

What do Neuro-Pathologists need to know about Ophthalmology?

Natalie Wolkow, MD, PhD

Assistant Professor of Ophthalmology

Eye Pathology and Ophthalmic Plastic Surgery

Mass Eye and Ear/Harvard Medical School

Disclosures

- I have no relevant financial relationships to disclose

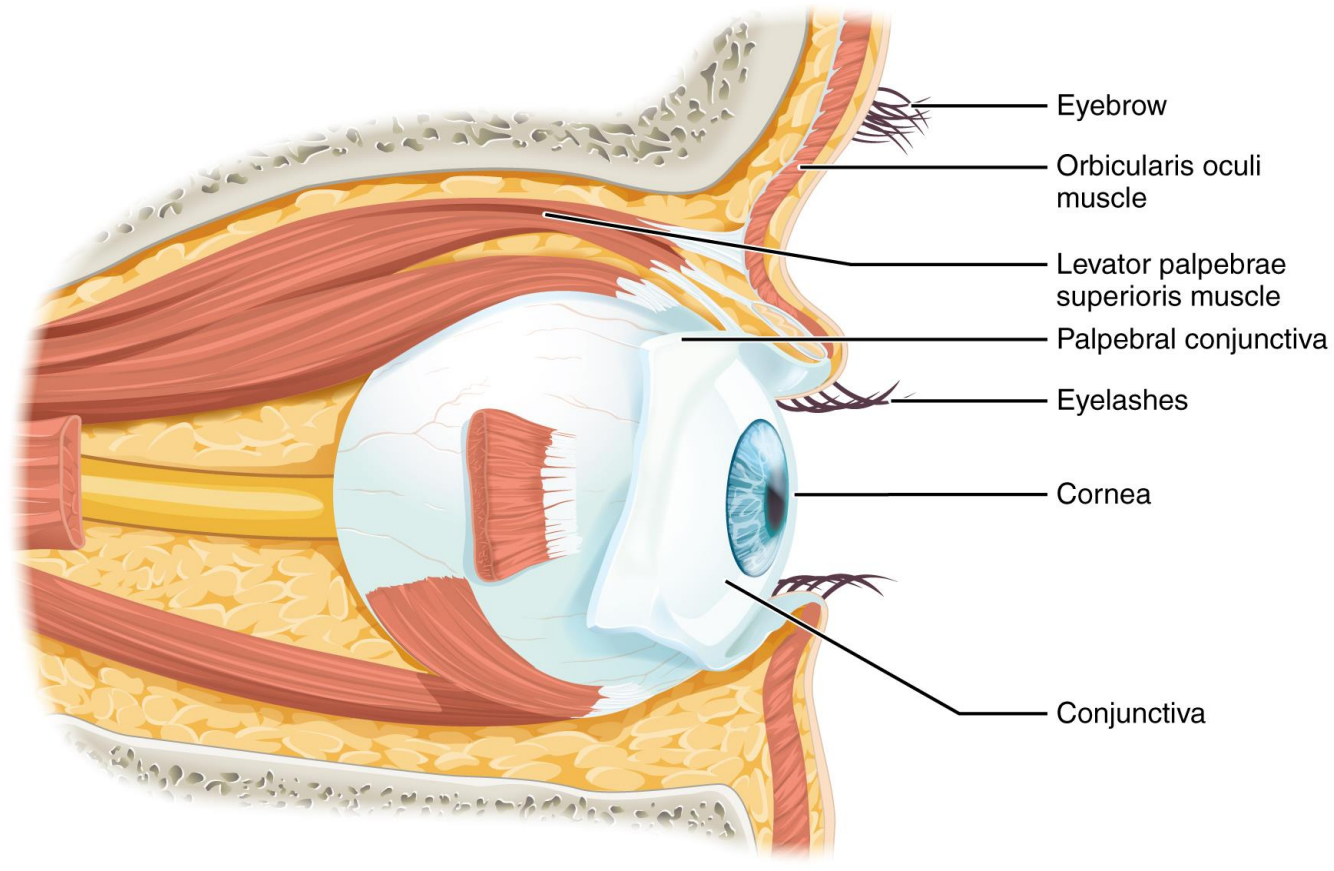


Learning Objectives

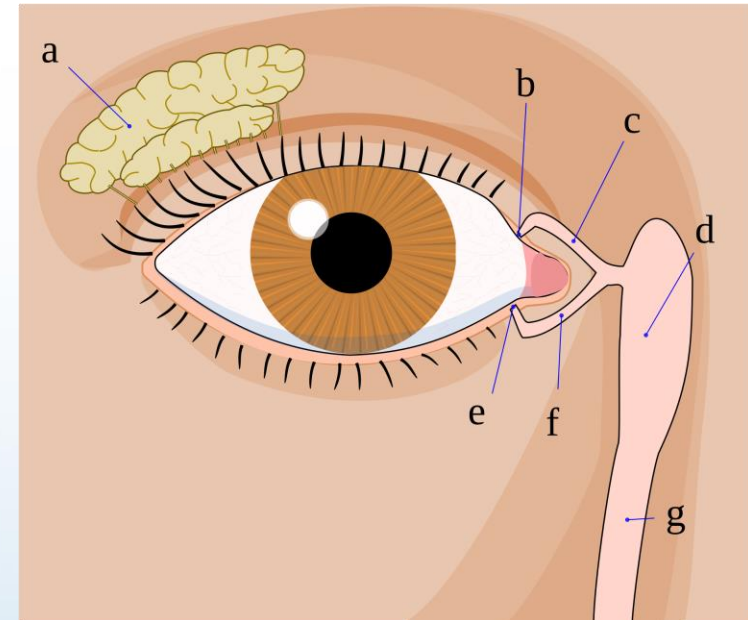
- Recall normal orbital and ocular **anatomy and histology**
- Describe common ophthalmic surgical procedures and the histopathologic changes that they may result in
- Identify select histopathologic diagnoses that are unique to the ocular region



Eye Pathology



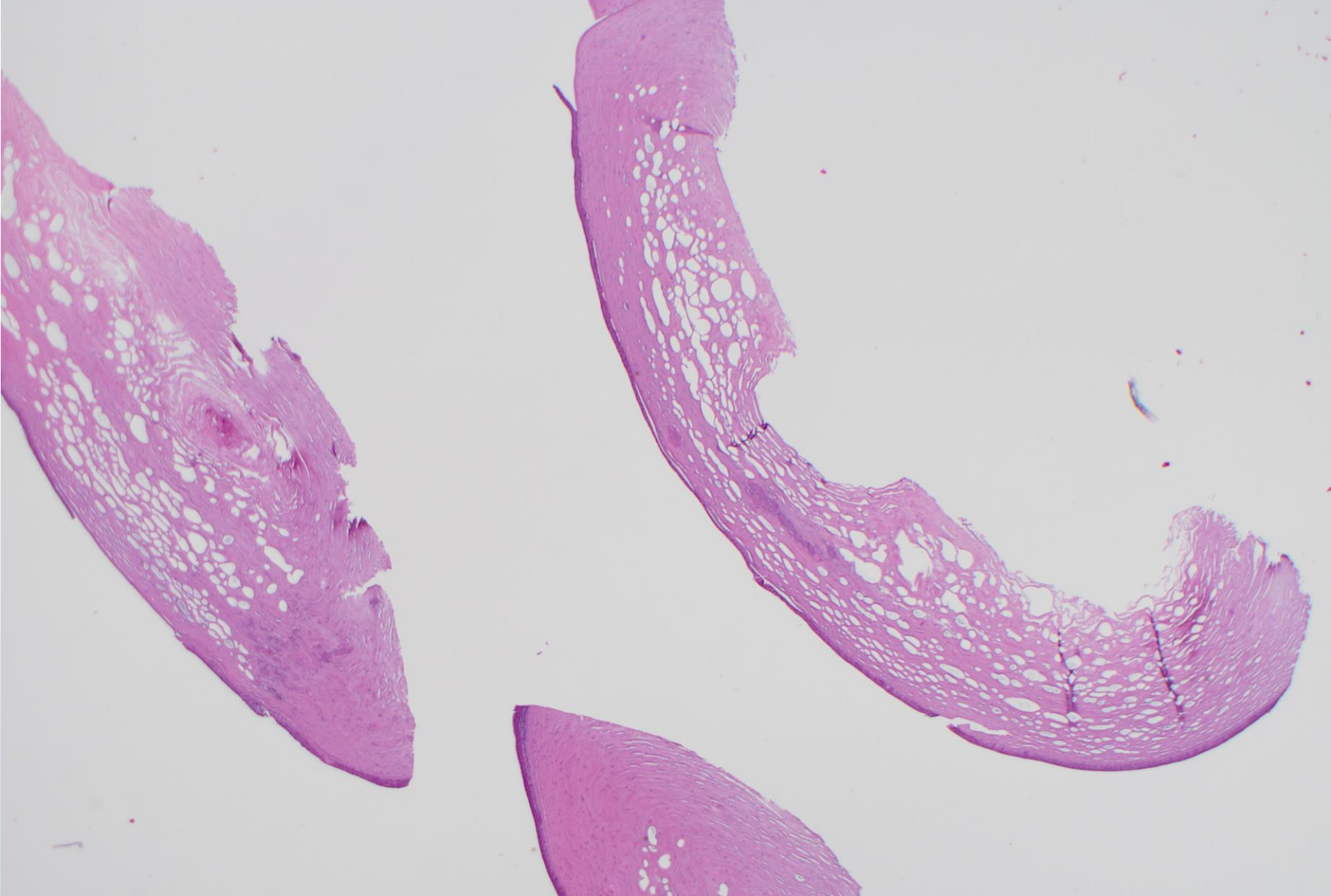
https://commons.wikimedia.org/wiki/File:1411_Eye_in_The_Orbit.jpg



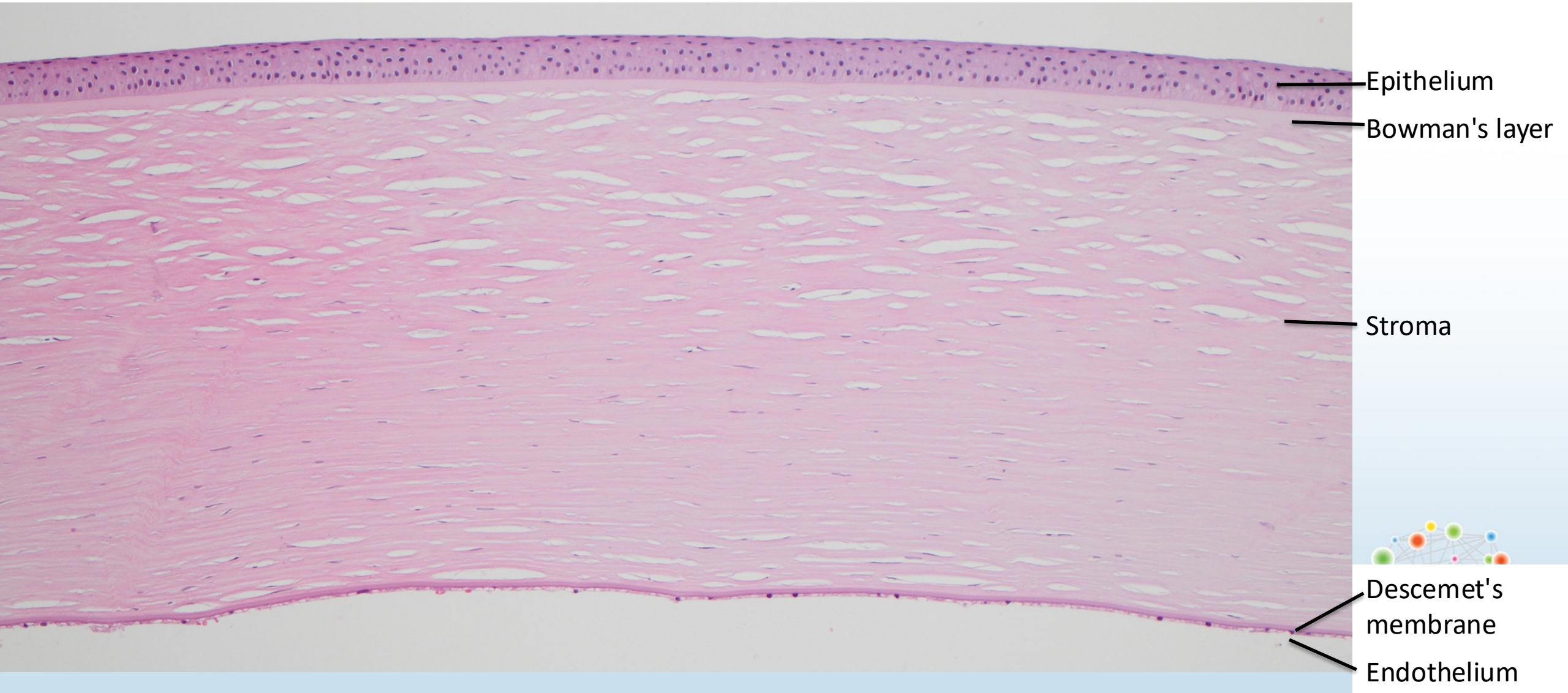
https://commons.wikimedia.org/wiki/File:Tear_system.svg

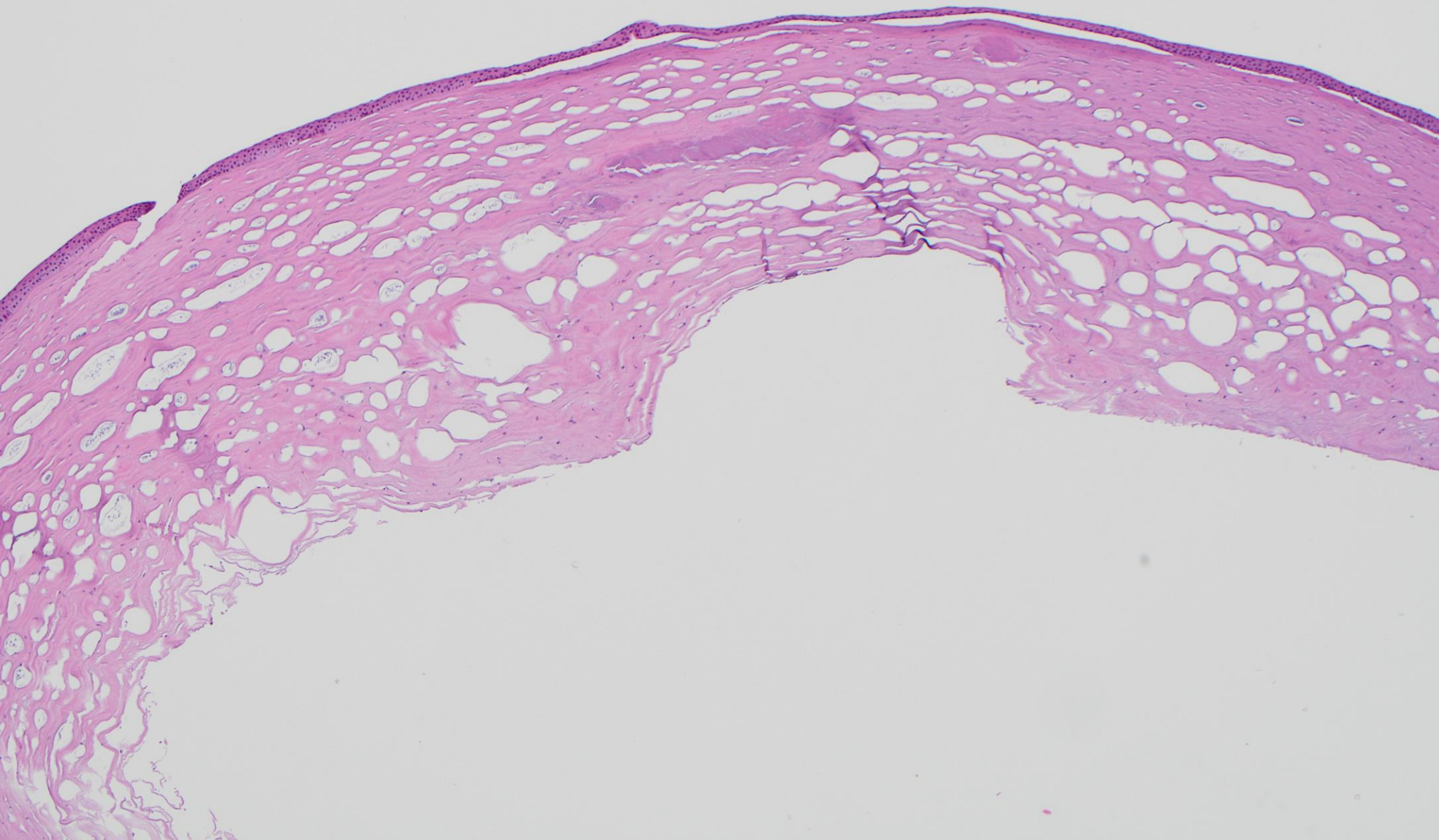


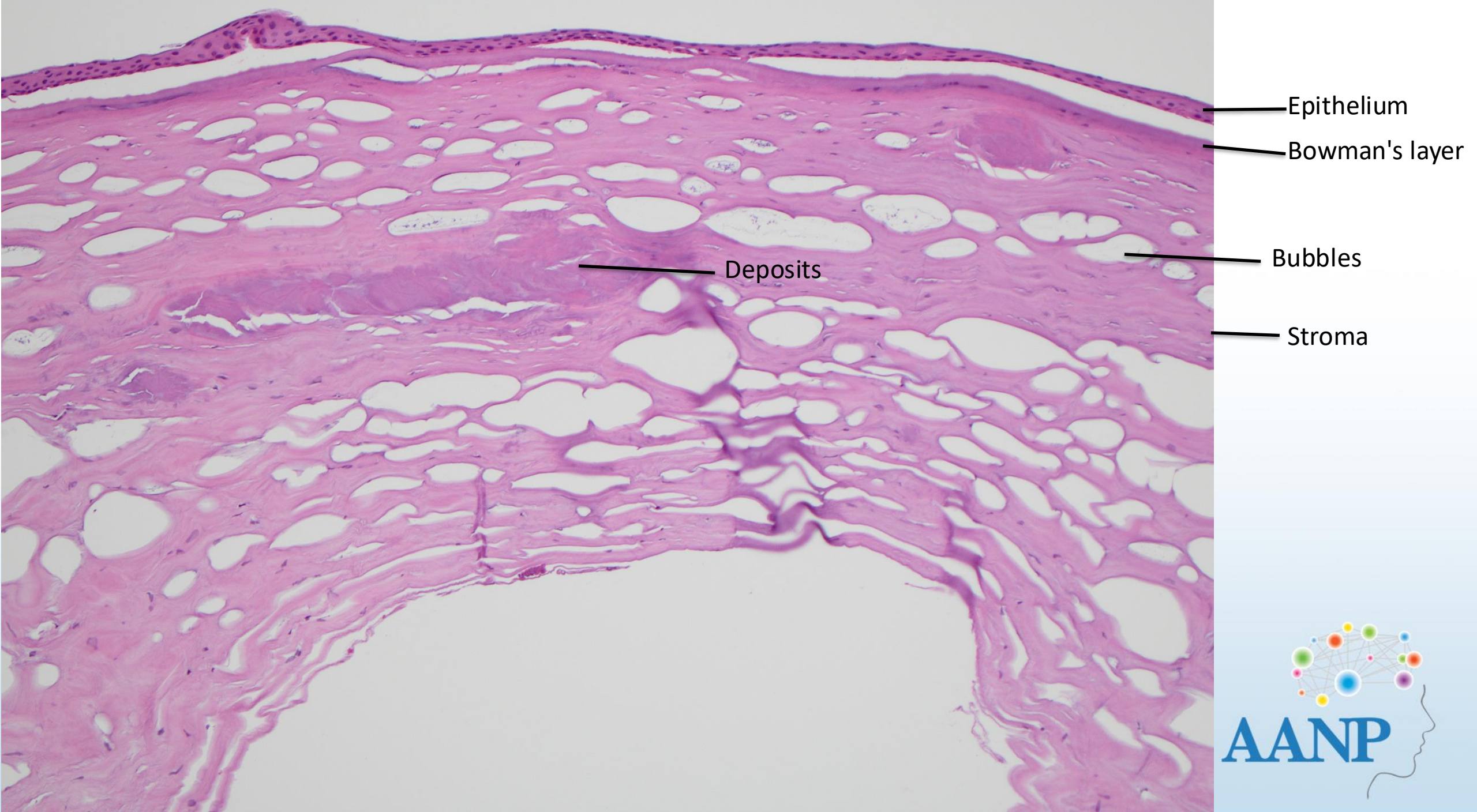Case #1: Corneal Tissue Submitted for Evaluation



Review: Normal Corneal Histology







Epithelium

Bowman's layer

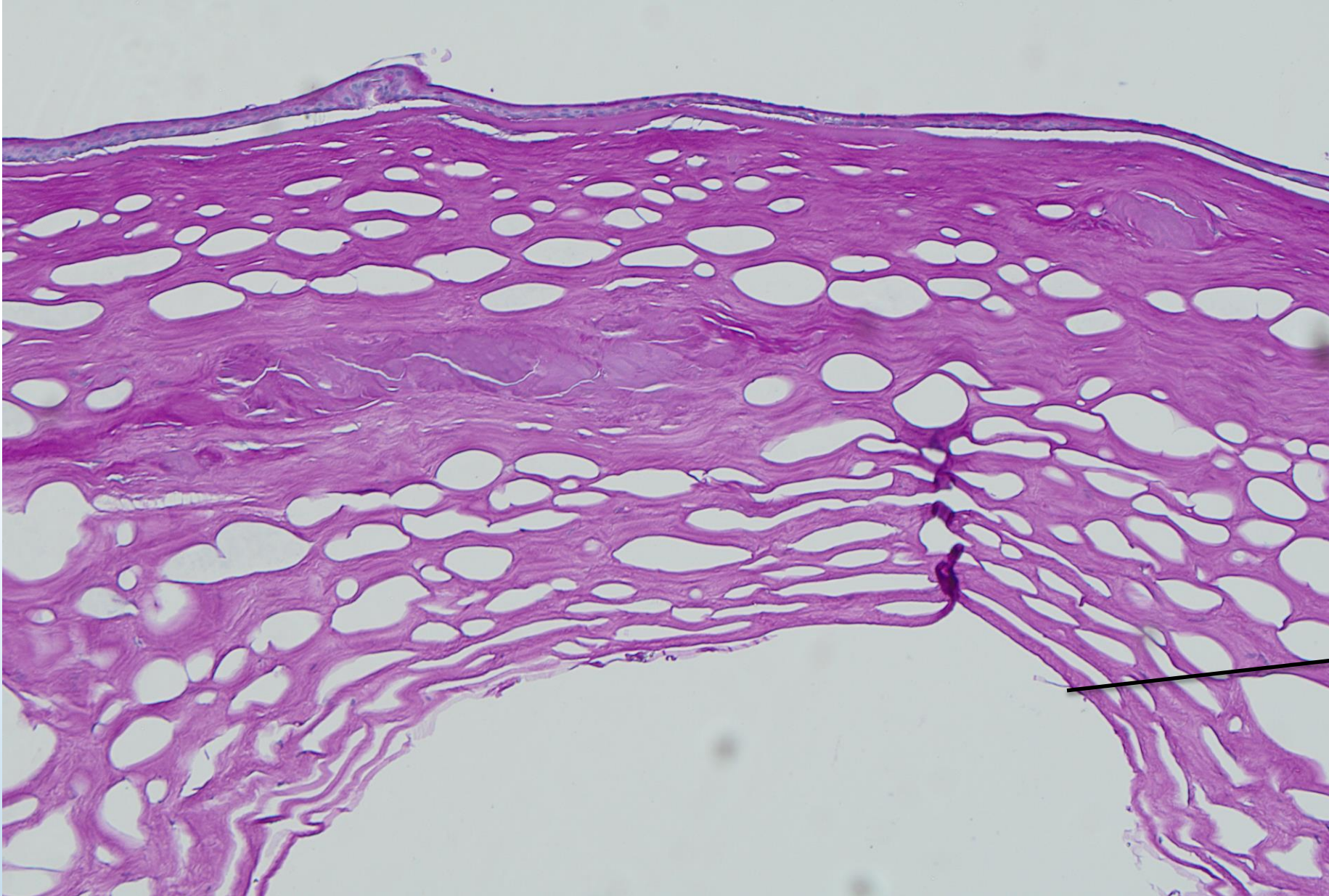
Deposits

Bubbles


Stroma



Periodic acid-Schiff (PAS)



No Descemet's
membrane or
Endothelium



Corneal Stromal Deposits → Corneal Stromal Dystrophies



Mnemonic: Marilyn Monroe Always Gets Her Man in L.A. County

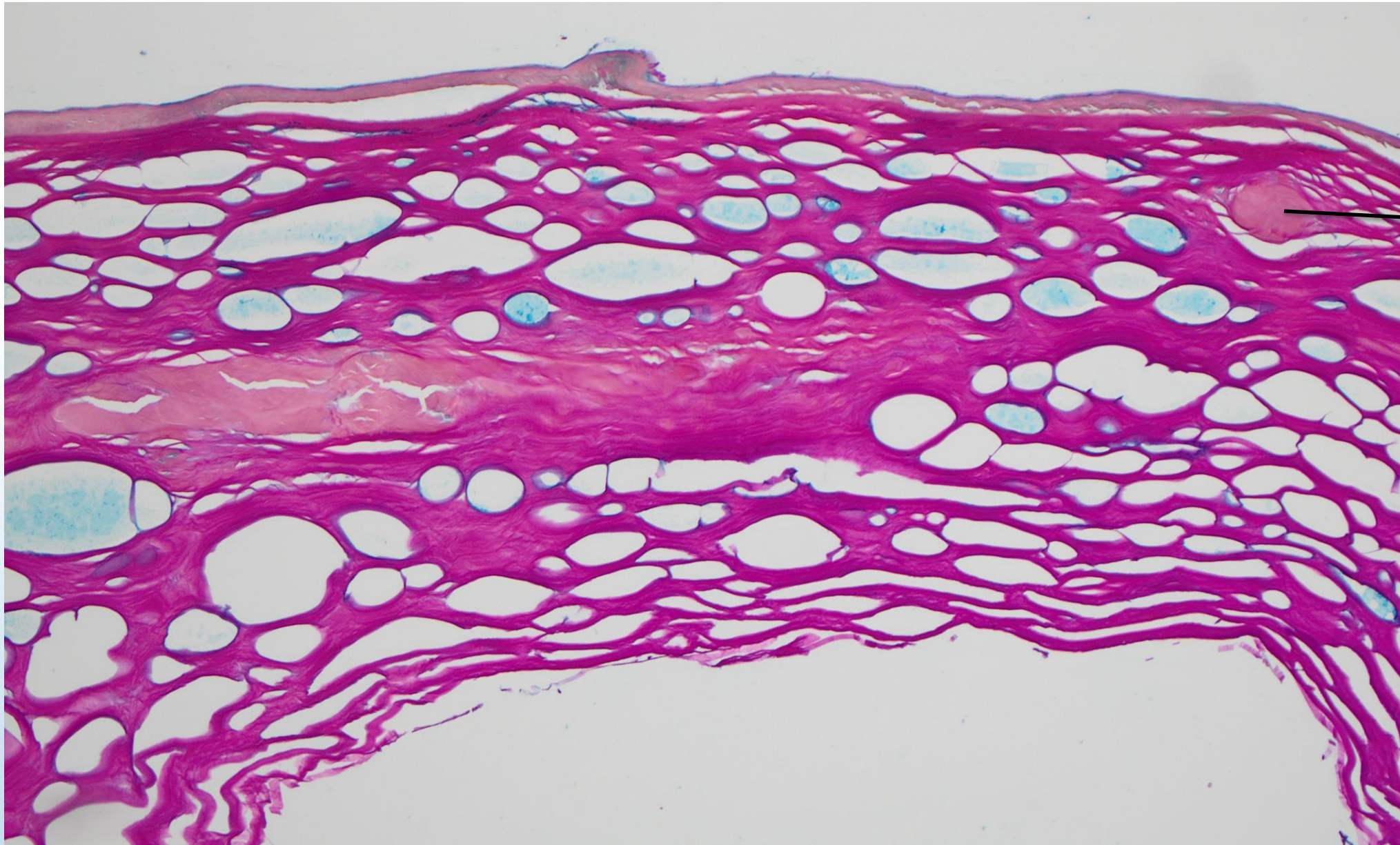
Marilyn: **M**acular Dystrophy
Monroe: **M**ucopolysaccharide
Always: **A**lcian Blue (or Colloidal Iron)

Gets: **G**ranular Dystrophy
Her: **H**yaline
Man: **M**asson Trichrome

L.: **L**attice Dystrophy
A.: **A**myloid
County: **C**ongo Red

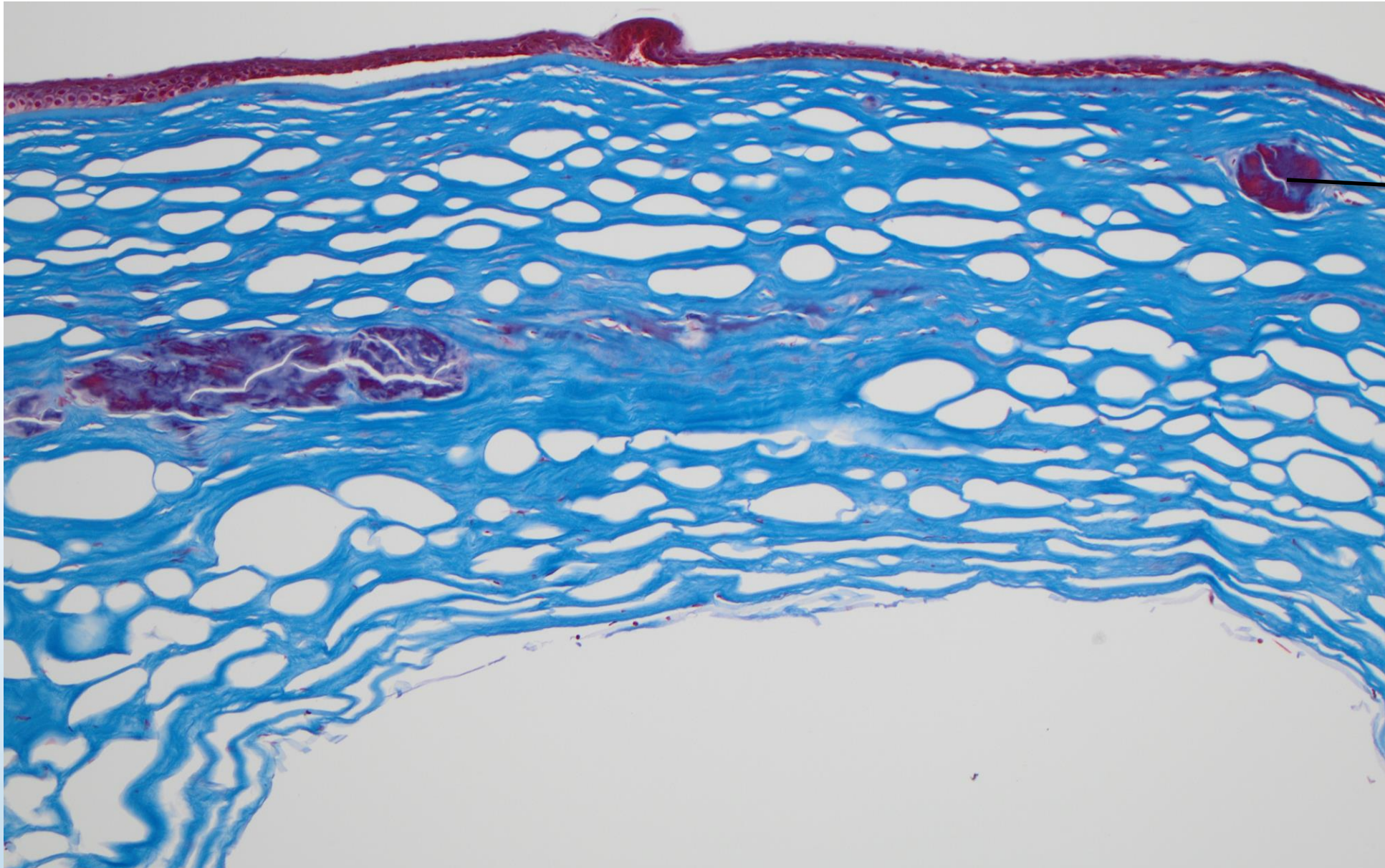


Colloidal Iron (instead of Alcian Blue)

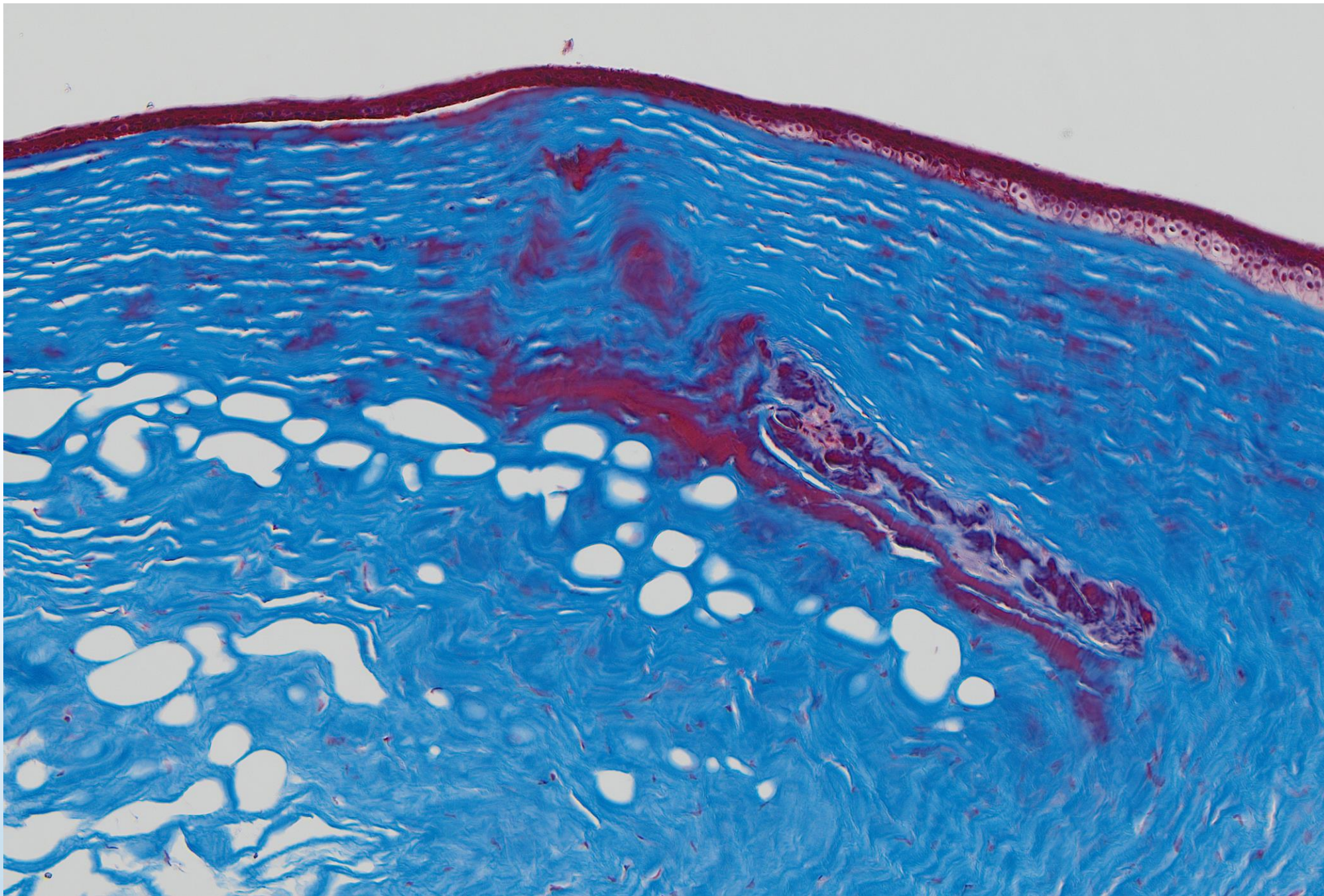


Deposits:
negative with
colloidal iron

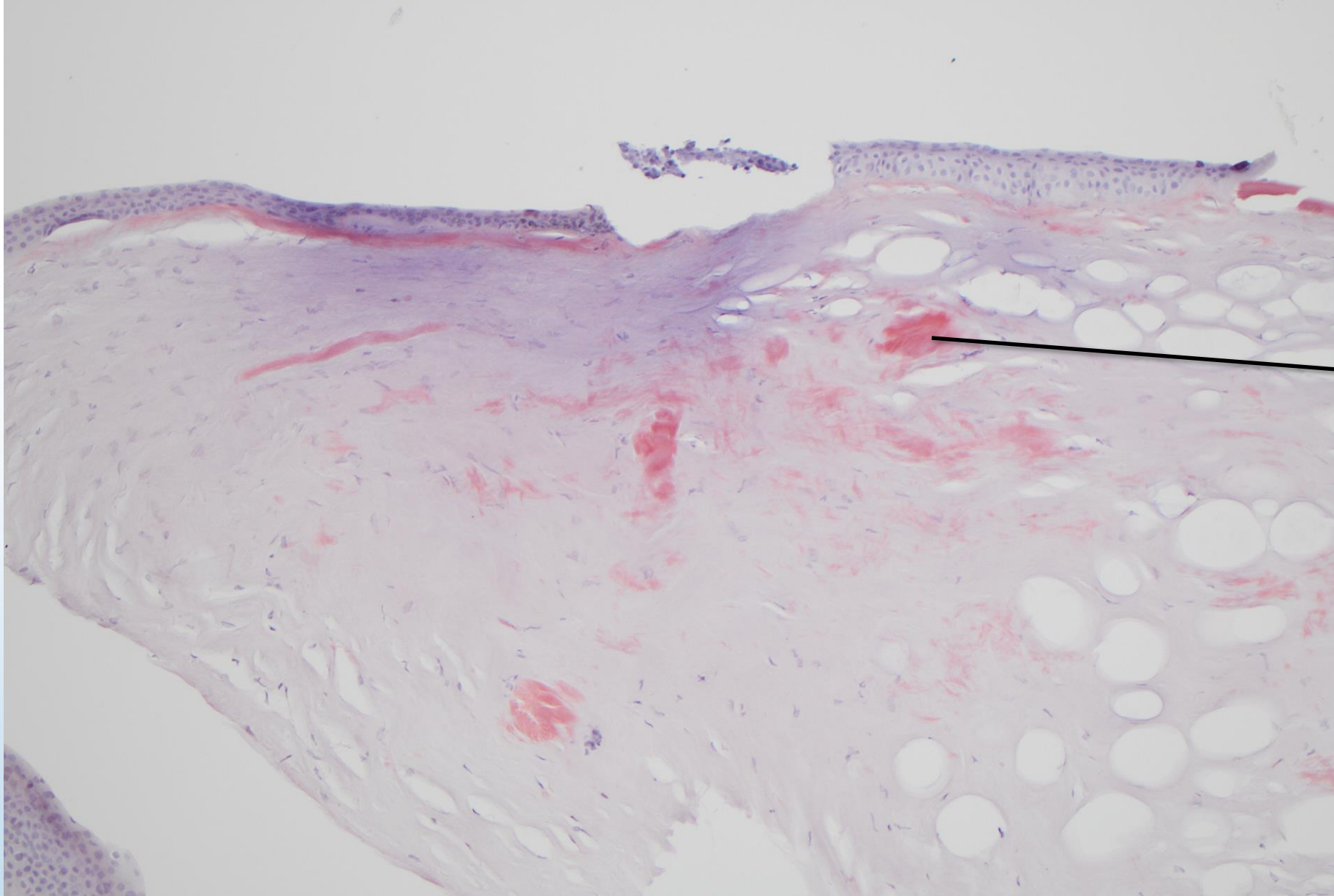
Masson Trichrome



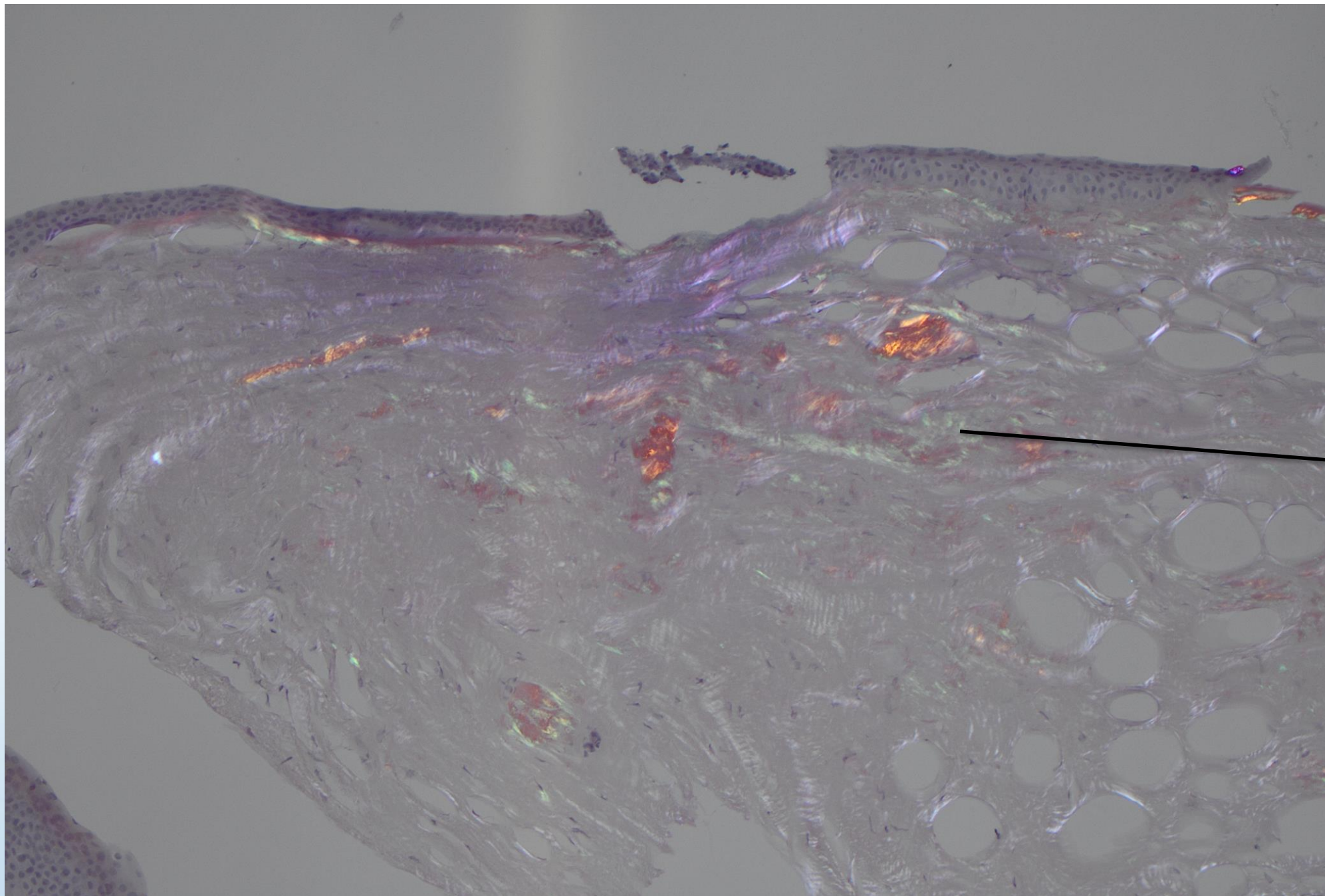
Deposits: red
with trichrome



Congo Red



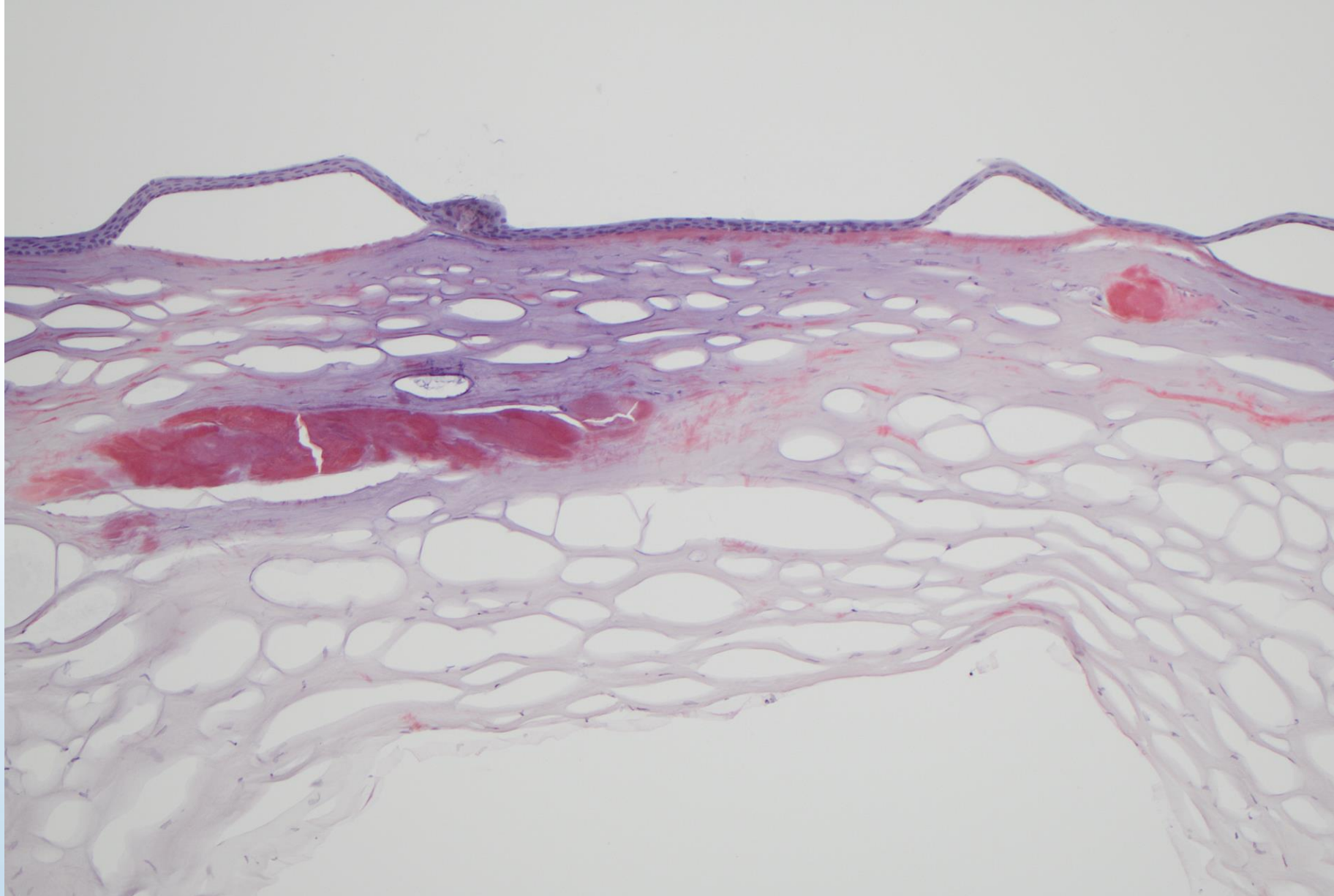
Deposits:
stain with
Congo red

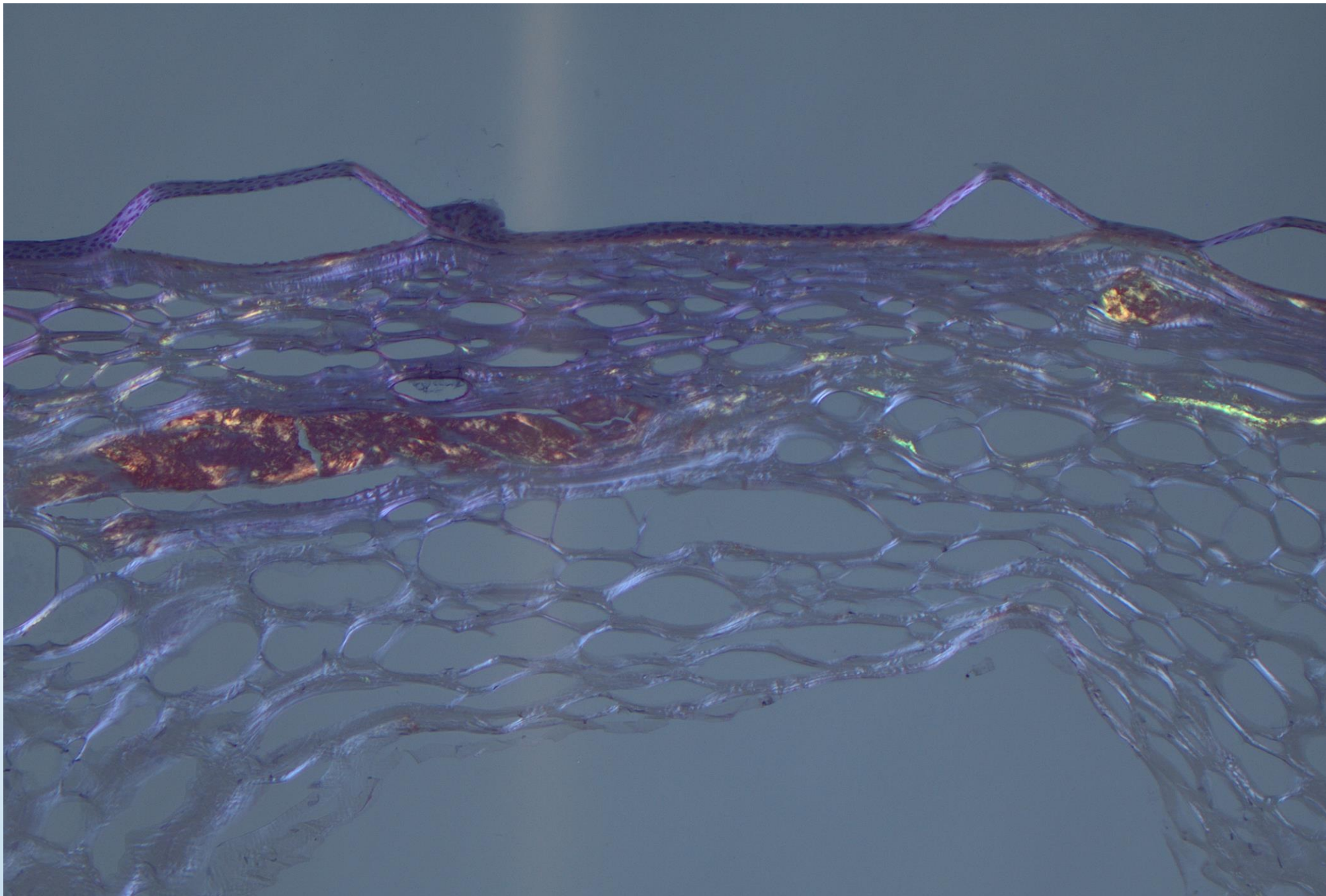


Deposits:
apple green
birefringence



Congo Red





Corneal Stromal Dystrophies



Mnemonic: Marilyn Monroe Always Gets Her Man in L.A. County

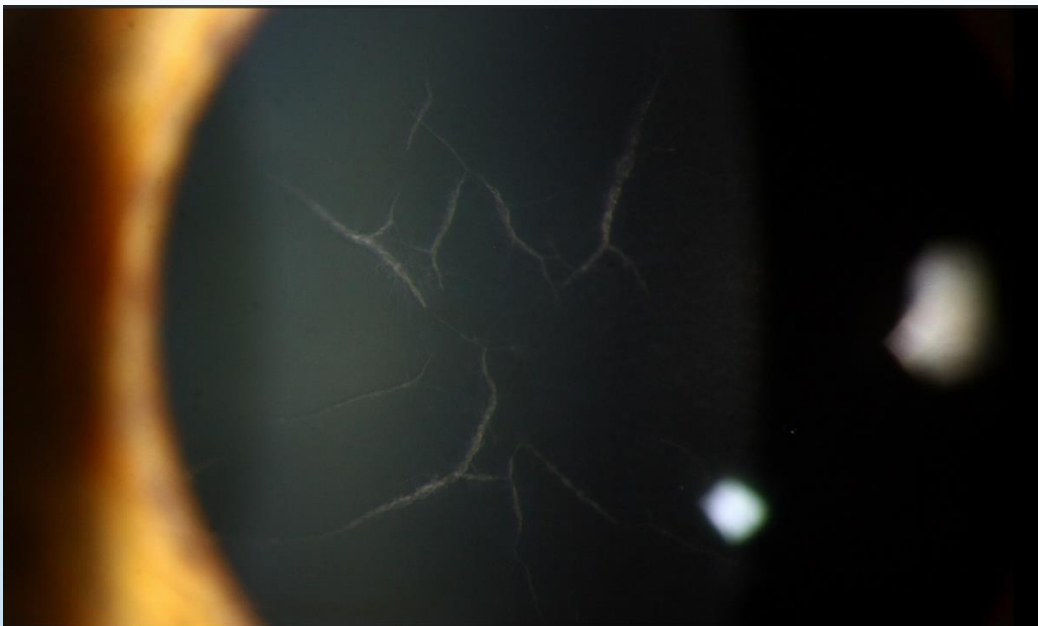
Marilyn: **M**acular Dystrophy
Monroe: **M**ucopolysaccharide
Always: **A**lcian Blue (or Colloidal Iron)

Gets: **G**ranular Dystrophy
Her: **H**yaline
Man: **M**asson Trichrome

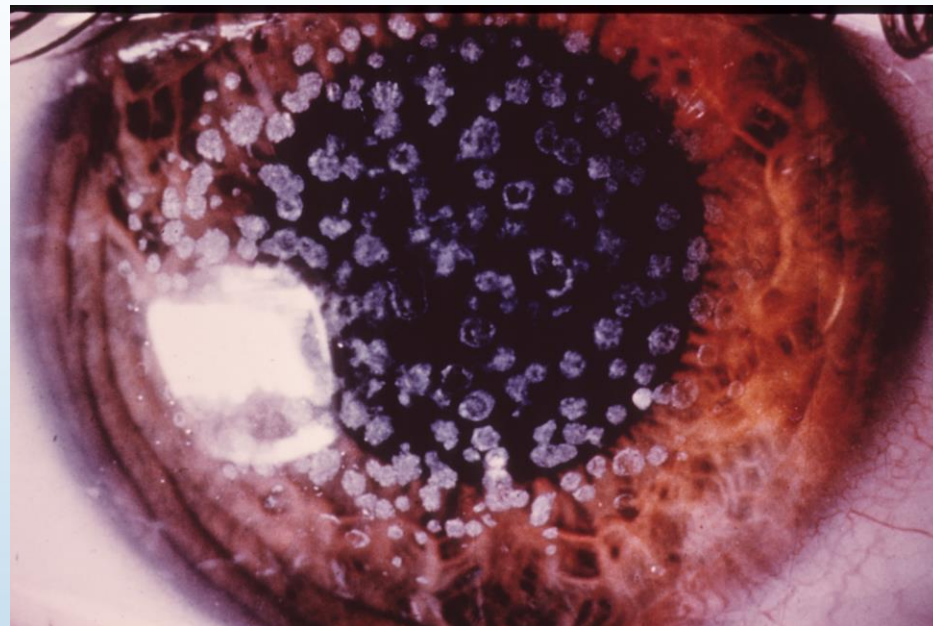
L: **L**attice Dystrophy
A.: **A**myloid
County: **C**ongo Red

Corneal Stromal Dystrophies

- Autosomal dominant
- Mutations in *TGFBI* gene (transforming growth factor beta induced)
 - Lattice Corneal Dystrophy Type 1: "classic" -- lines -- amyloid
 - Granular Dystrophy Type 1: "classic" -- crumbs -- hyaline



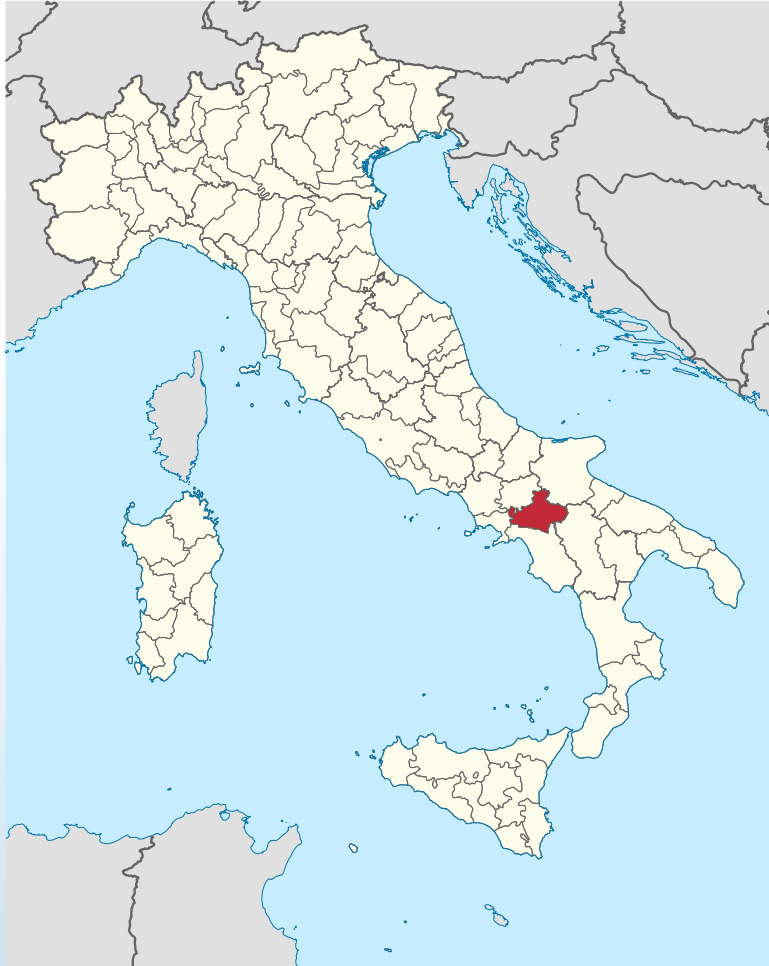<https://webeye.ophth.uiowa.edu/eyeforum/atlas/pages/lattice-corneal-dystrophy.htm#gsc.tab=0>



<https://disorders.eyes.arizona.edu/disorders/corneal-dystrophy-granular>

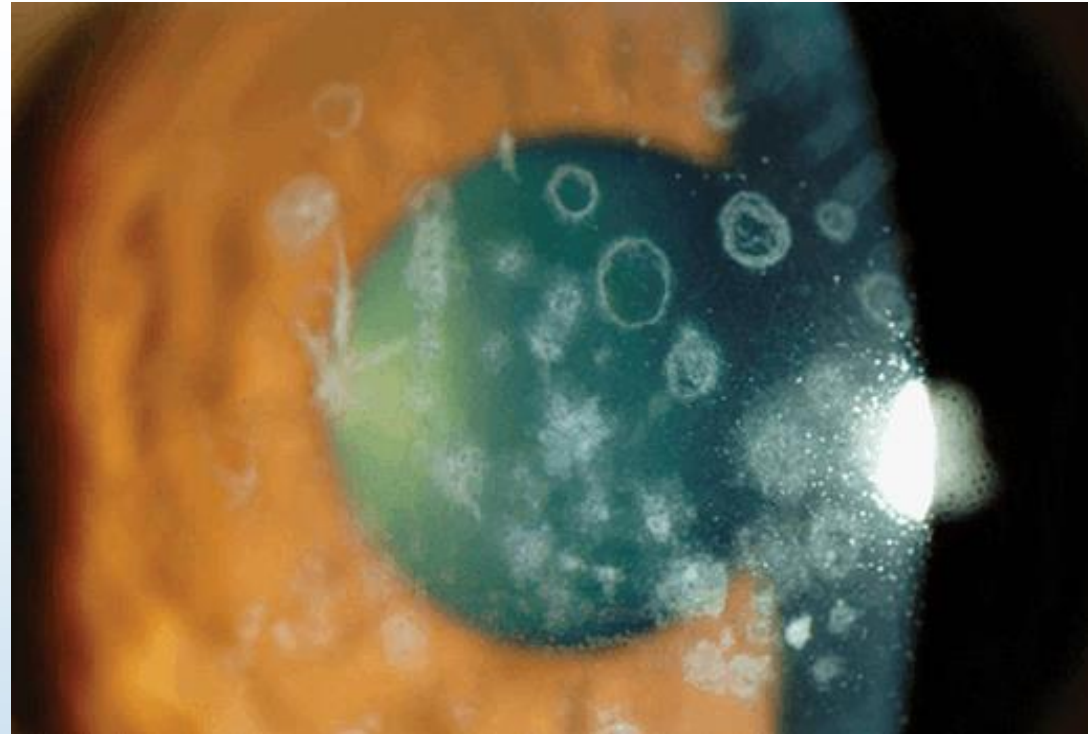


Granular Dystrophy Type 2: "Avellino Dystrophy"



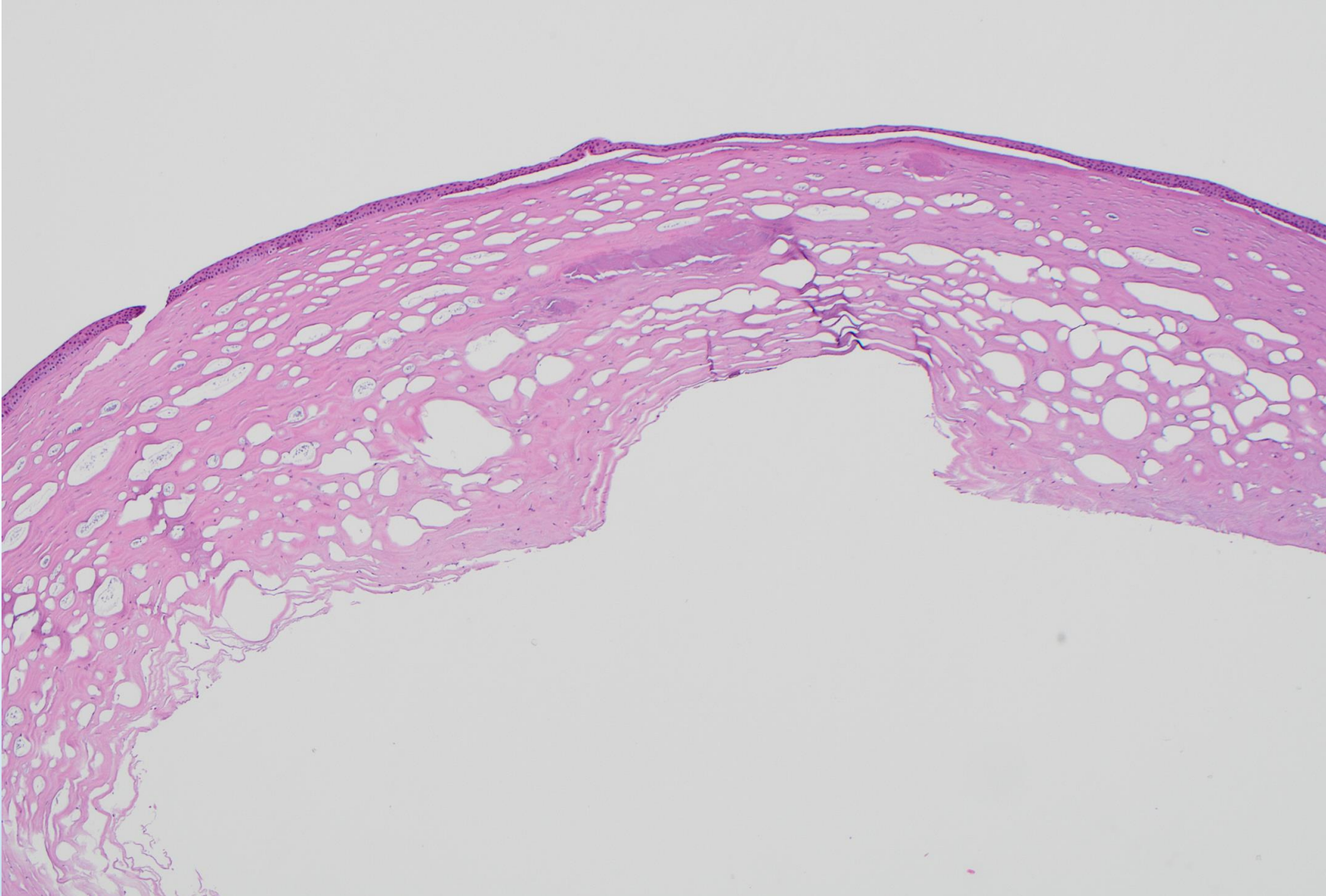
https://en.wikivoyage.org/wiki/Avellino_%28province%29

- Autosomal dominant; mutations in *TGFBI* gene
- Combines features of granular type 1 and lattice type 1 dystrophies clinically and histologically – **hyaline and amyloid deposits** (lines and crumbs)

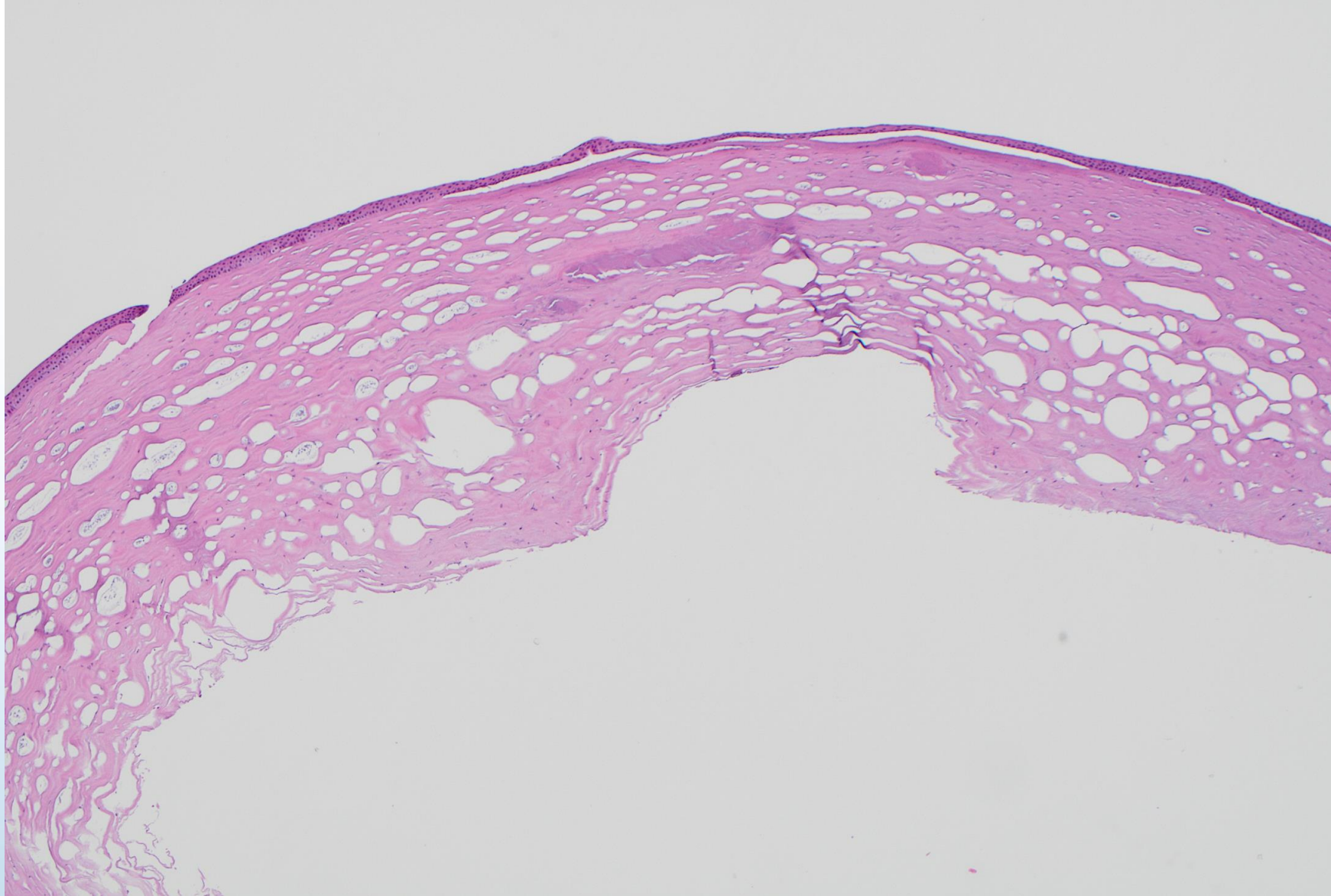


<https://www.eyenews.uk.com/education/trainees/post/corneal-dystrophies-simplified>

Case 1 corneal deposits = Avellino dystrophy (Granular Type 2)



What was the surgical procedure?



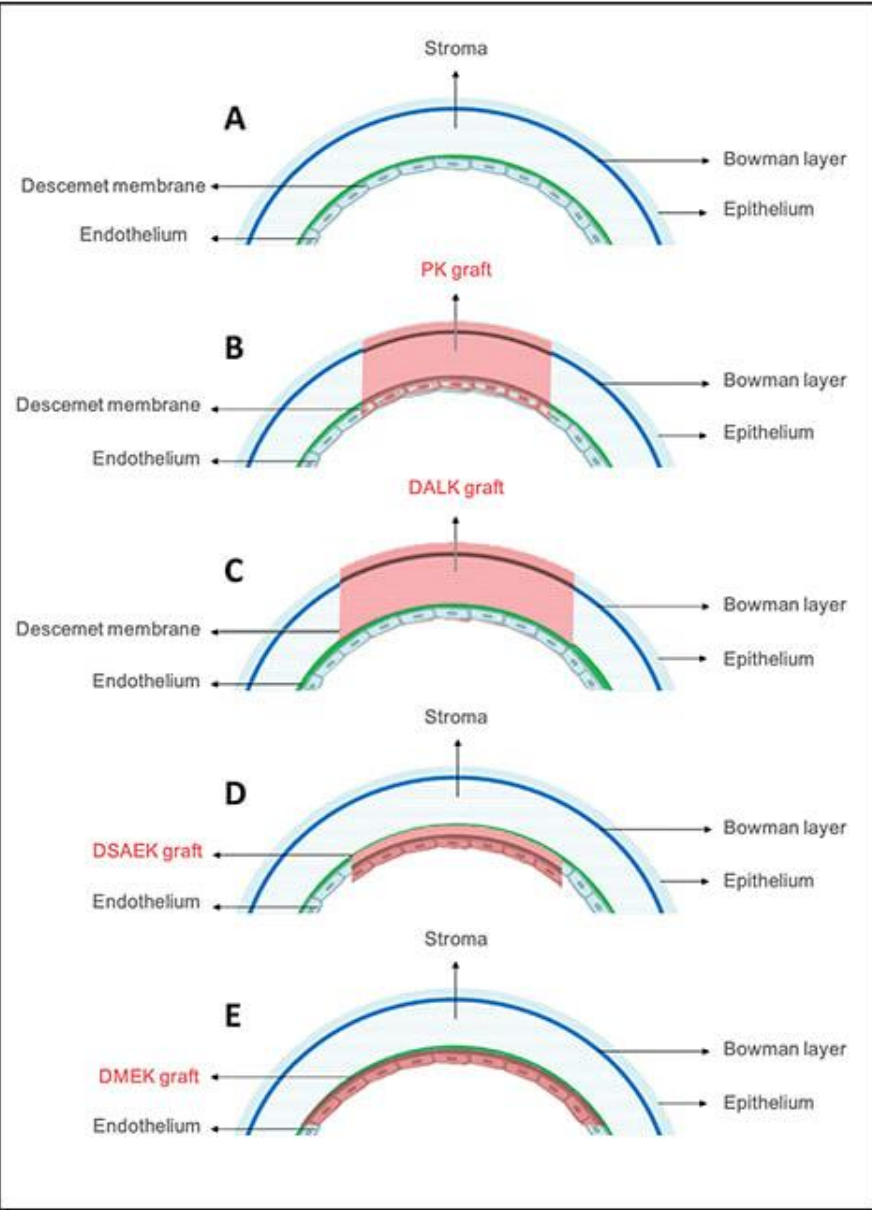
Surgical Procedures of the Cornea

Corneal Transplants:

- Penetrating Keratoplasty (PK)
- Deep Anterior Lamellar Keratoplasty (DALK)
- Descemet Stripping Automated Endothelial Keratoplasty (DSAEK)
- Descemet Membrane Endothelial Keratoplasty (DMEK)
 - ***Descemetorrhexis Without Endothelial Keratoplasty (DWEK)
- Boston KPro Type I
- Boston KPro Type II



Cornea



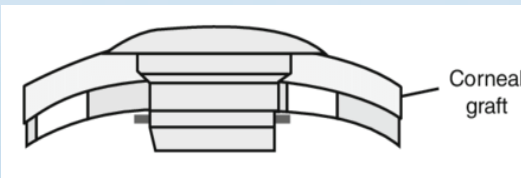
Penetrating Keratoplasty (**PK**)

Deep Anterior Lamellar Keratoplasty (**DALK**)


Descemet Stripping Automated Endothelial Keratoplasty (**DSAEK**)

Descemet Membrane Endothelial Keratoplasty (**DMEK**)

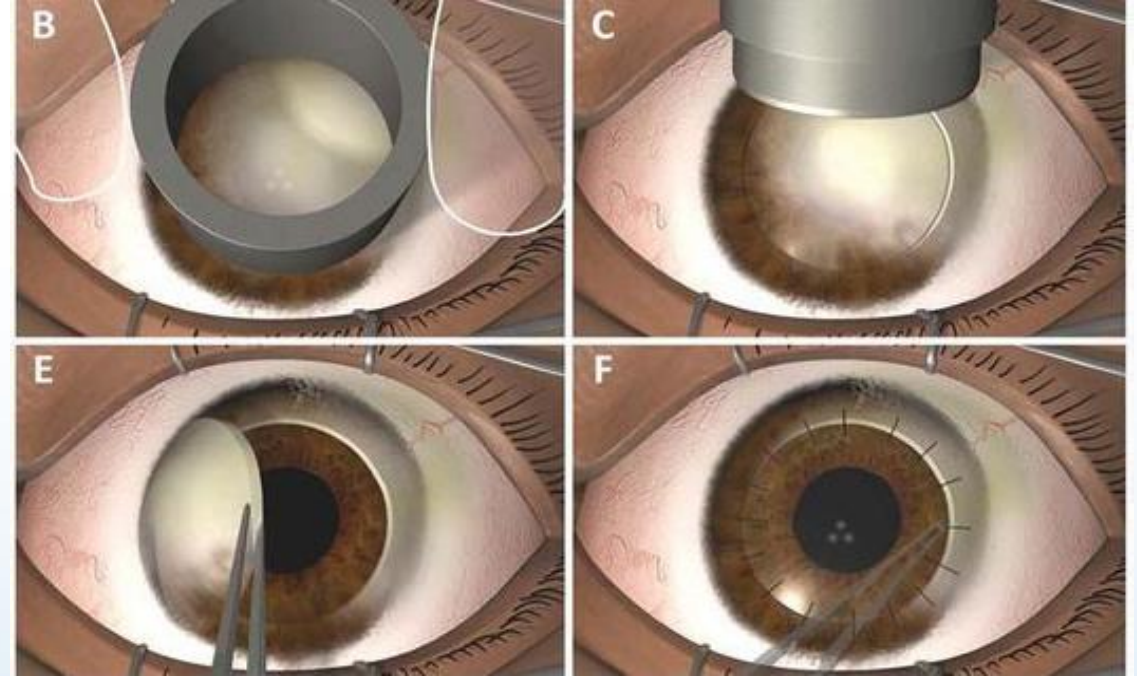
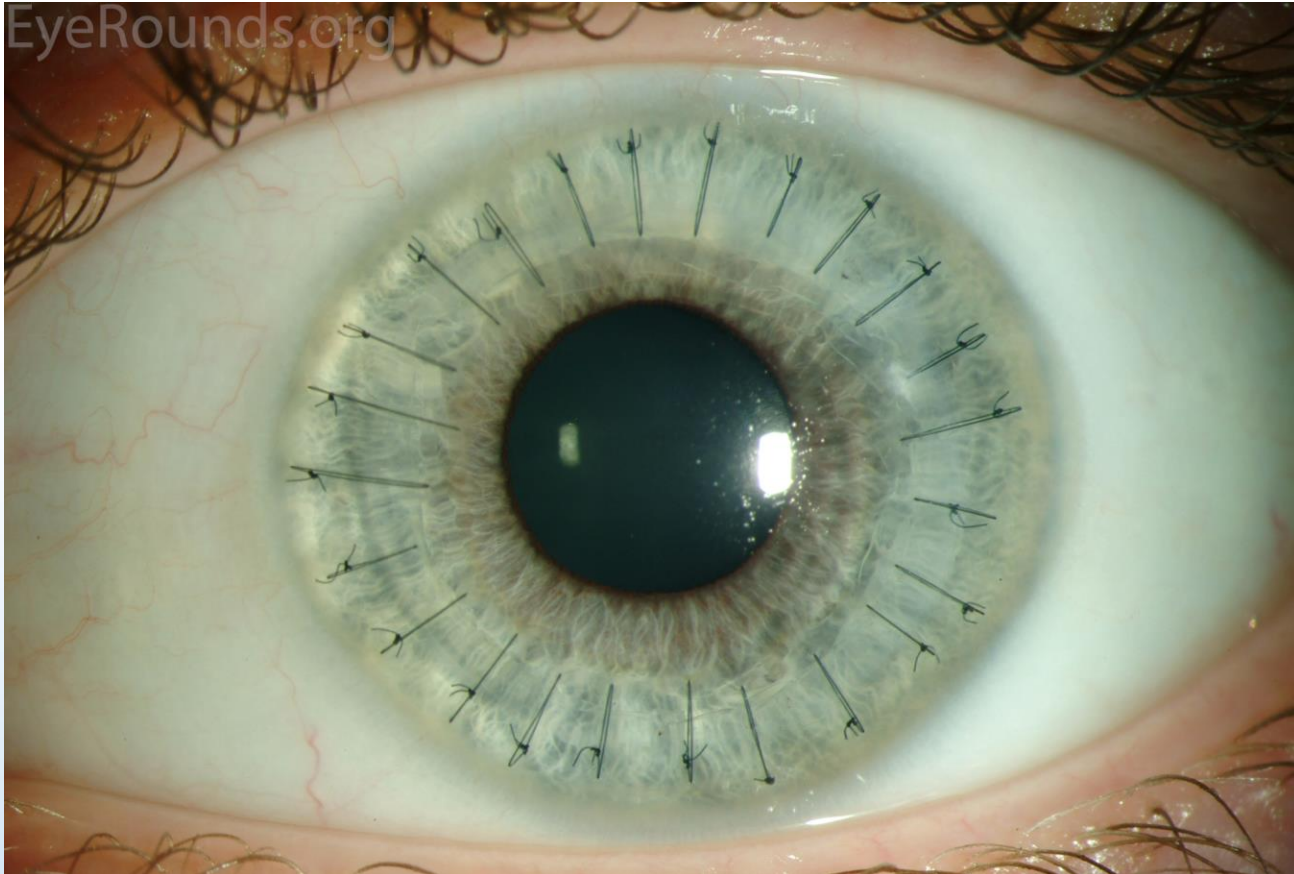
** Descemetorhexis Without Endothelial Keratoplasty (**DWEK**)



Boston KPro Type I and Type II




Penetrating keratoplasty

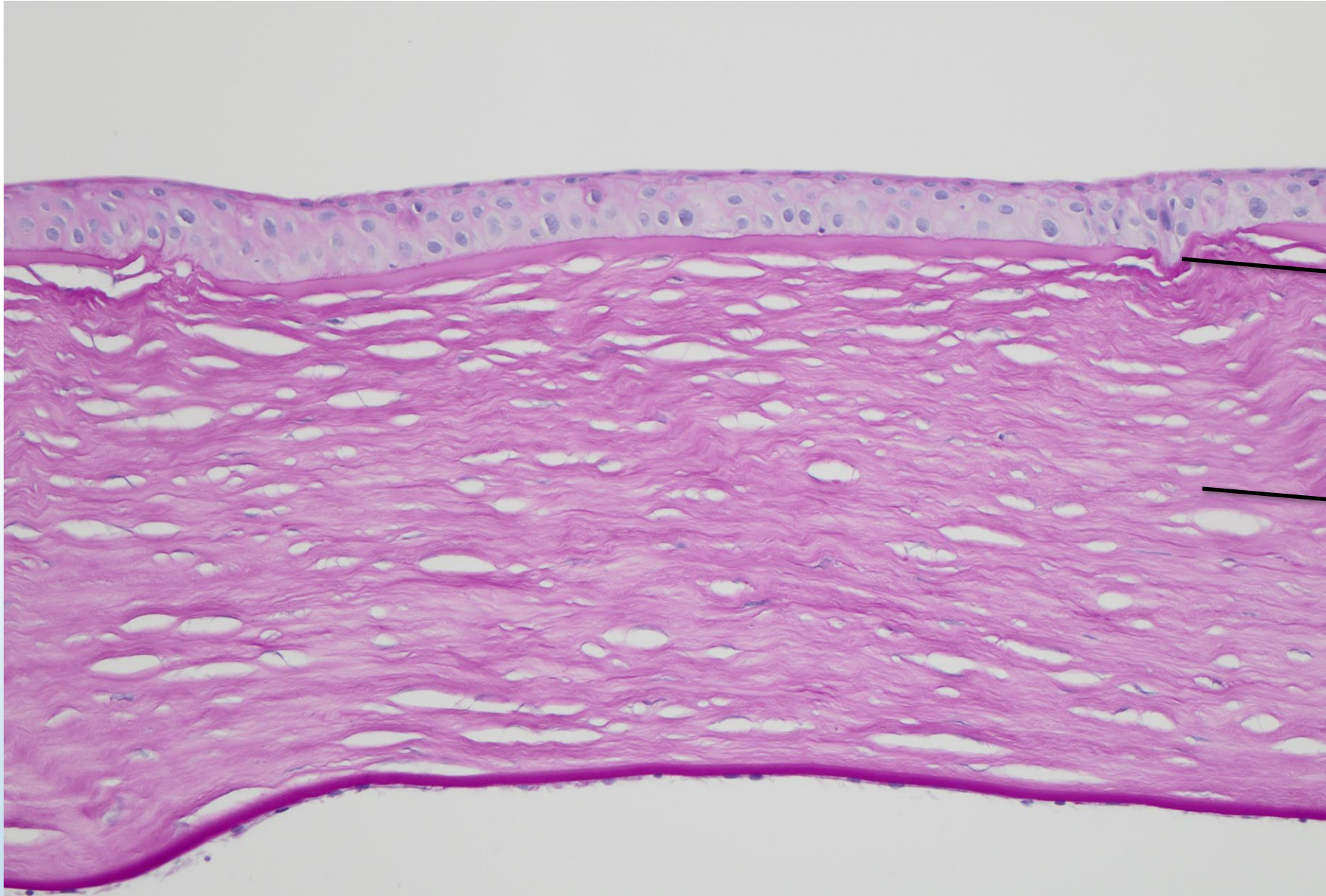


<https://www.healio.com/news/ophthalmology/20240702/secondary-pdek-can-follow-therapeutic-penetrating-keratoplasty-for-corneal-ulcer>

<https://webeye.ophth.uiowa.edu/eyeforum/tutorials/cornea-transplant-intro/2B-LRG-POM12-sp-PKP-for-ulcer-scar.jpg>




Penetrating keratoplasty in keratoconus (PAS stain)



Breaks in
Bowman's
layer

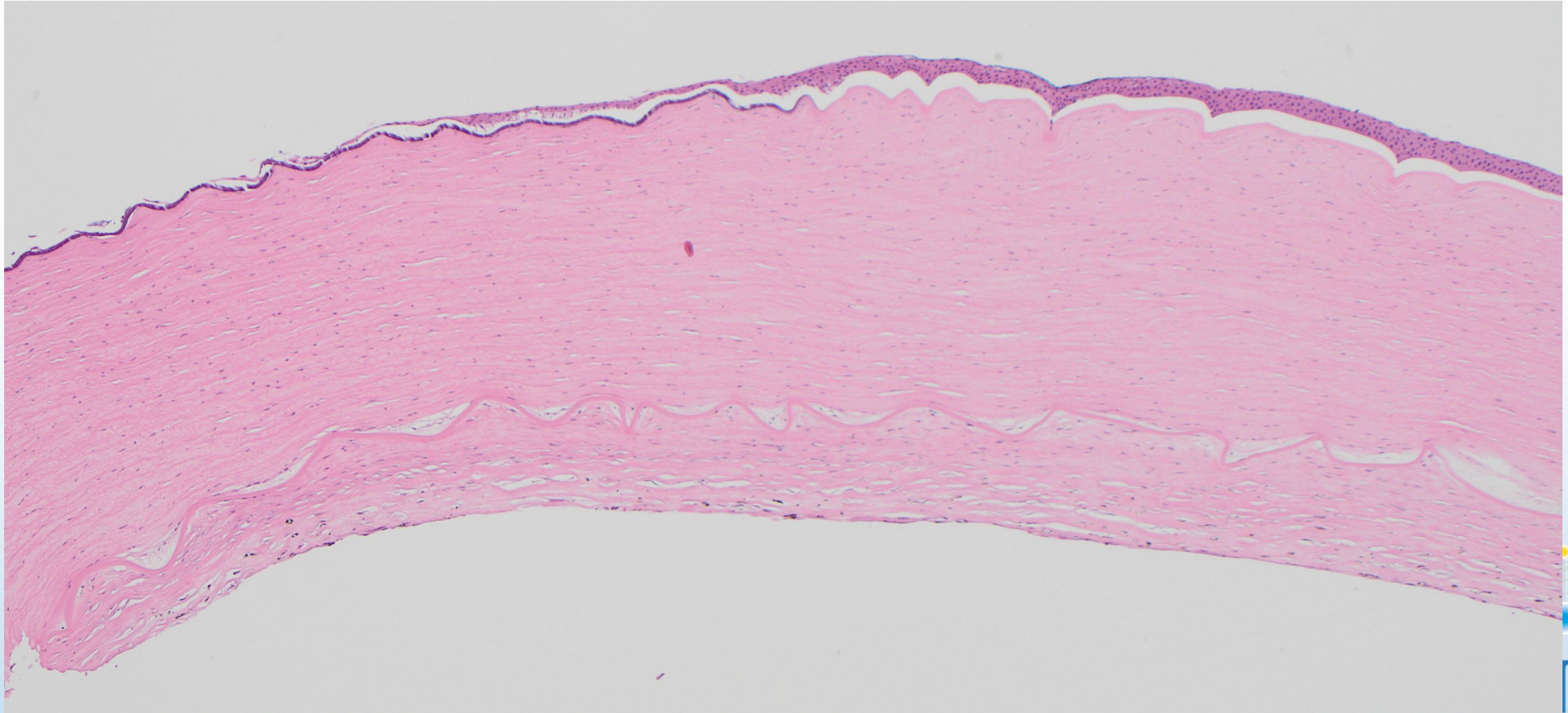
Decreased
corneal
stromal
thickness

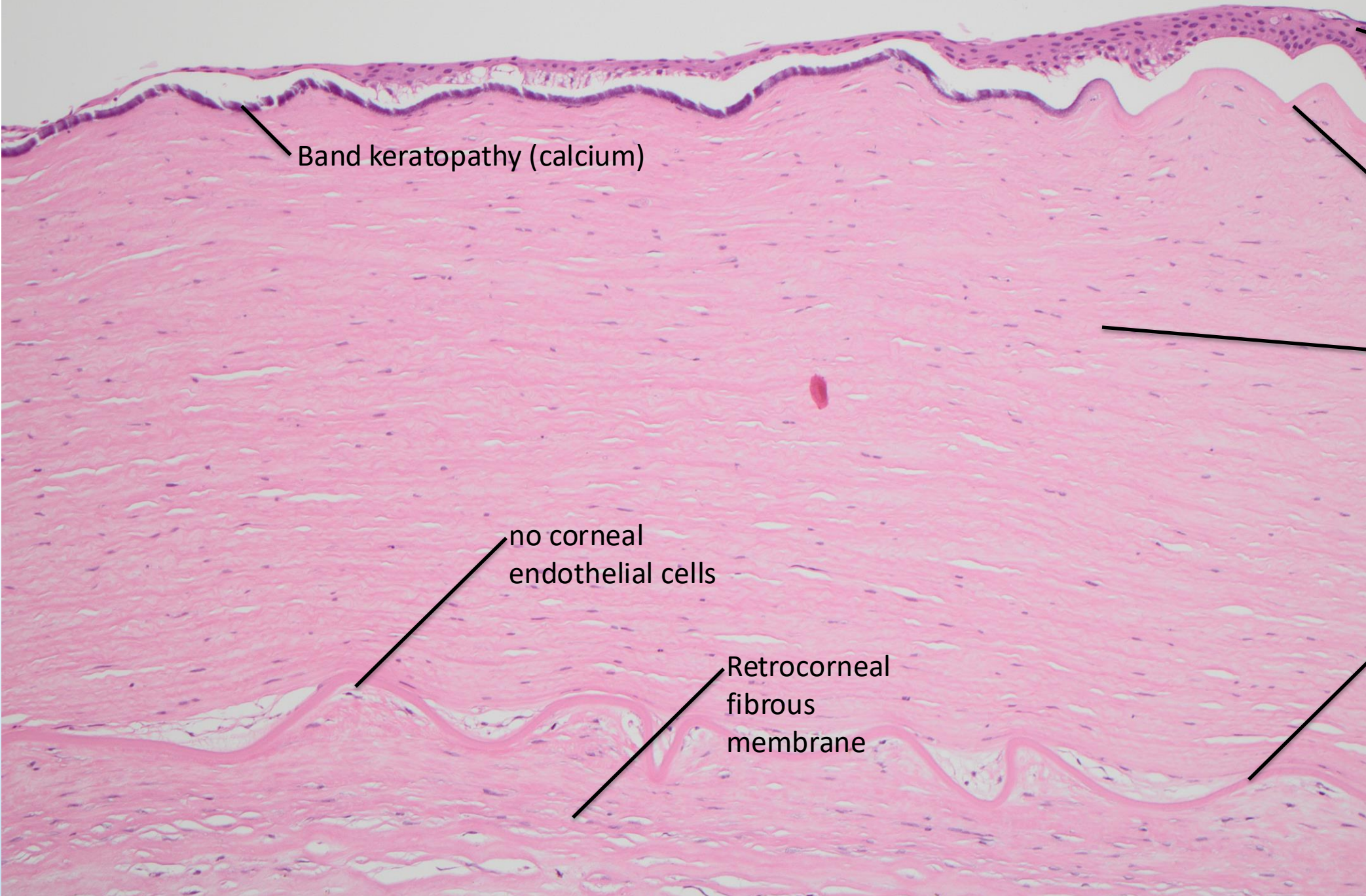
Penetrating keratoplasty for acanthamoeba keratitis (GMS)



Acanthamoeba

Repeat corneal transplant: Graft failure secondary to retrocorneal fibrous membrane; also band keratopathy





Attenuated corneal epithelium

Band keratopathy (calcium)


Bowman's layer

Stromal edema

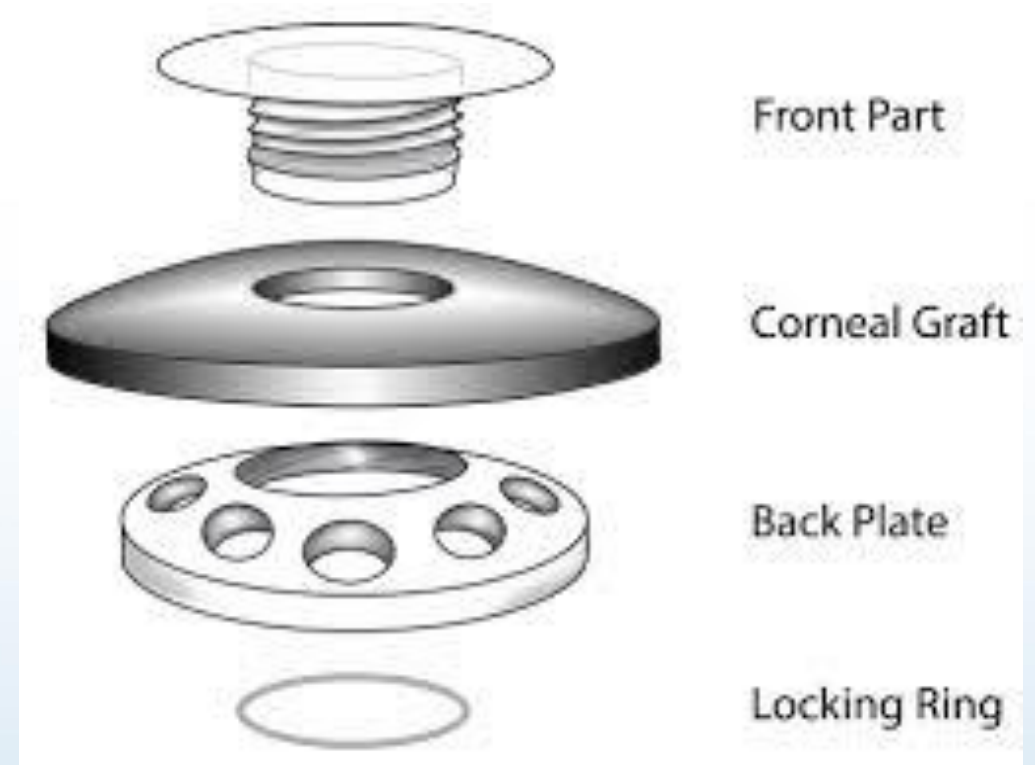
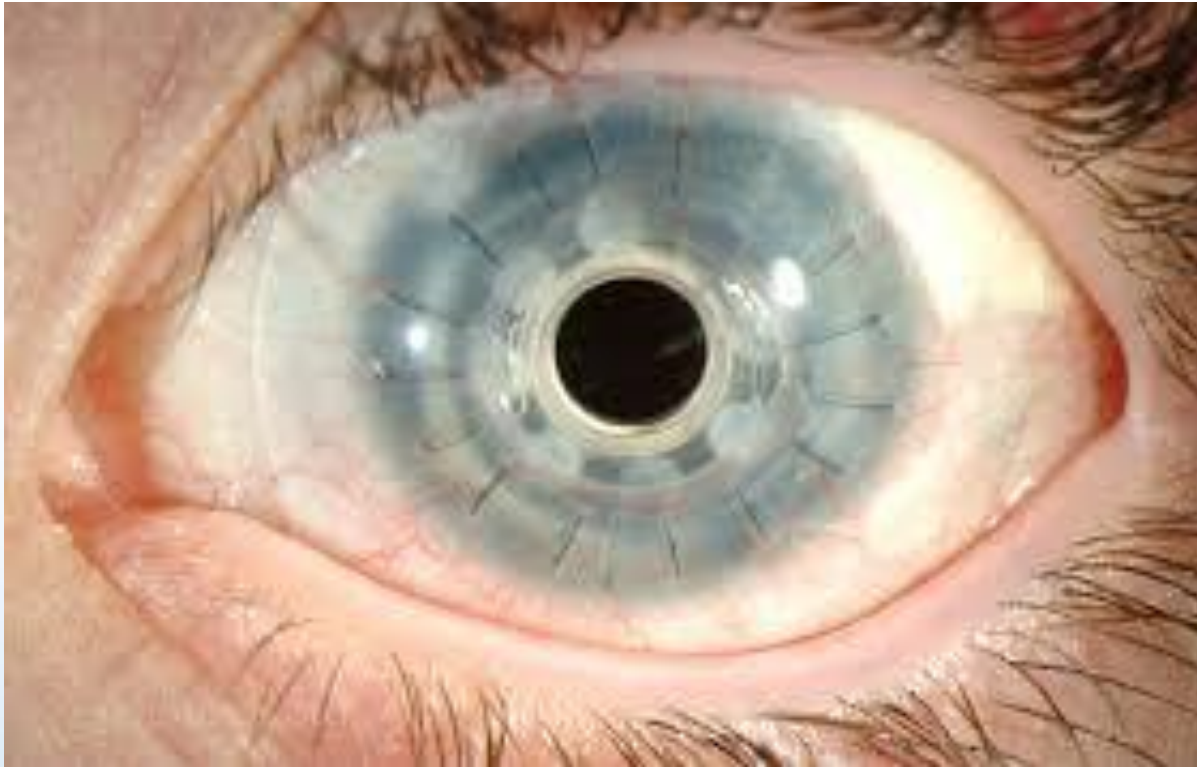no corneal endothelial cells

Retrocorneal fibrous membrane

Descemet's membrane

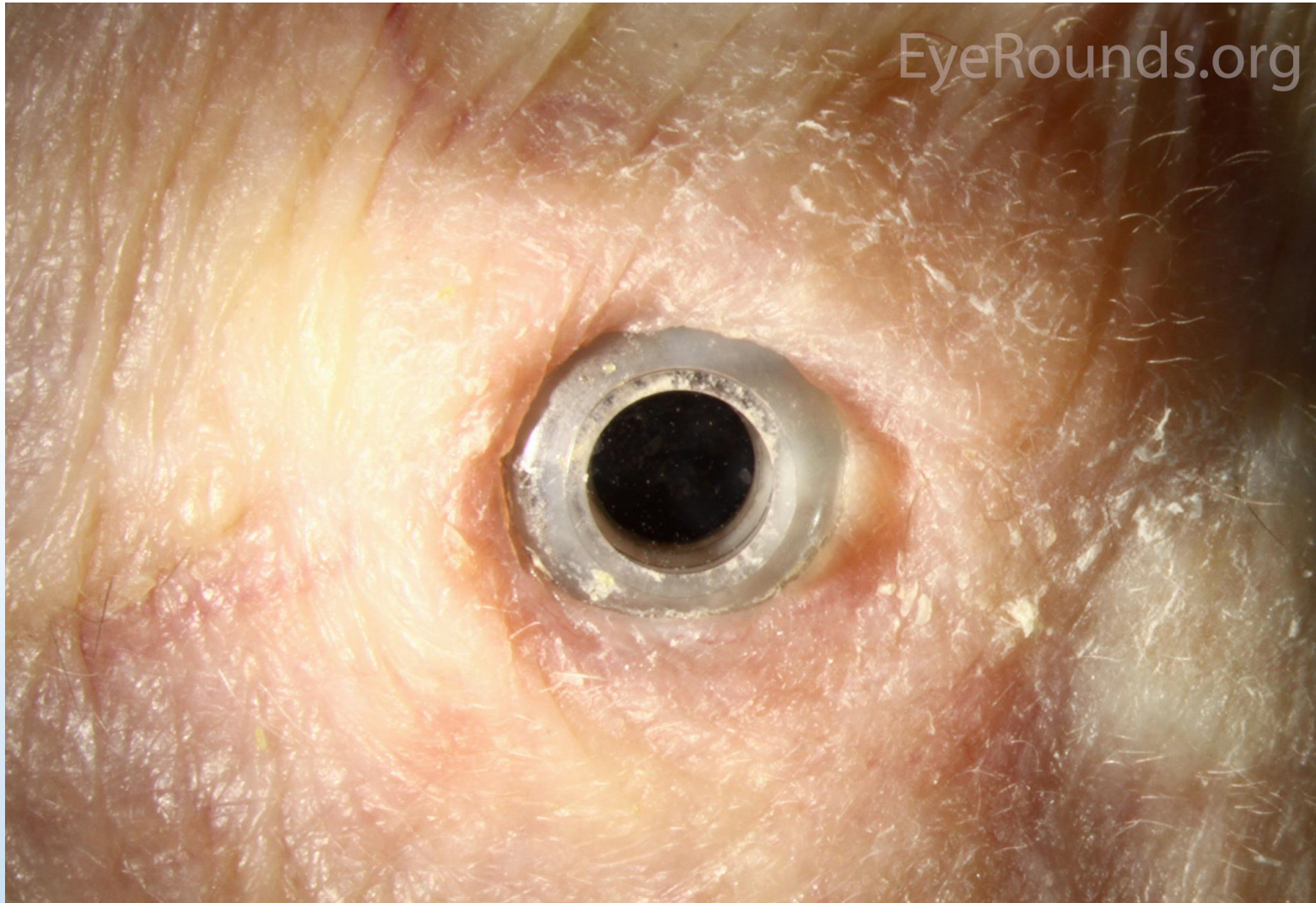


Boston Keratoprosthesis Type I



<https://webeye.ophth.uiowa.edu/eyeforum/tutorials/cornea-transplant-intro/6-kprosth.htm>

Boston Keratoprosthesis Type II

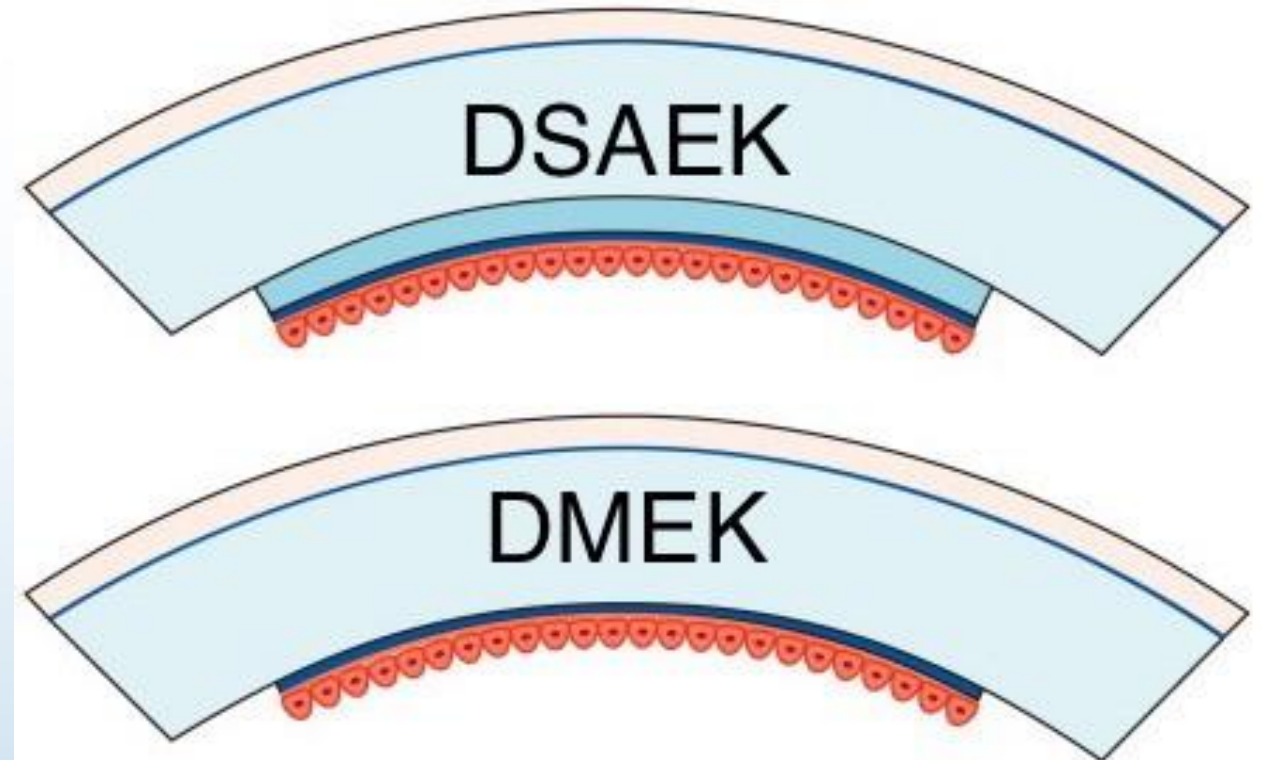
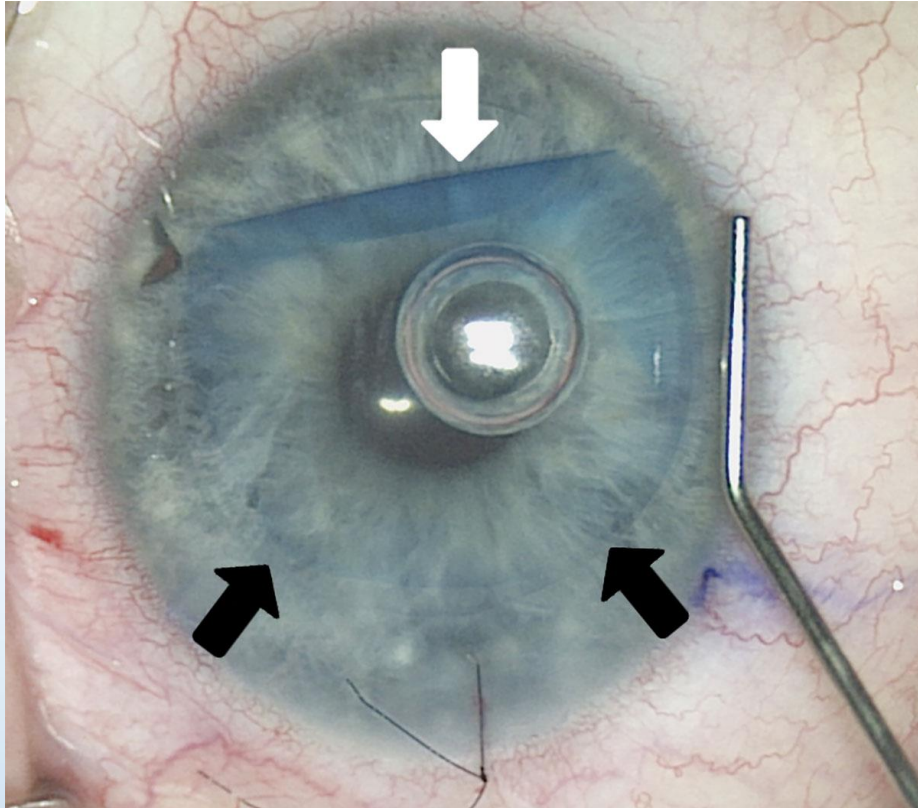


<https://webeye.ophth.uiowa.edu/eyeforum/tutorials/cornea-transplant-intro/6-kprosth.htm>



Descemet's Stripping Automated Endothelial Keratoplasty (DSAEK)

Descemet's Membrane Endothelial Keratoplasty (DMEK)

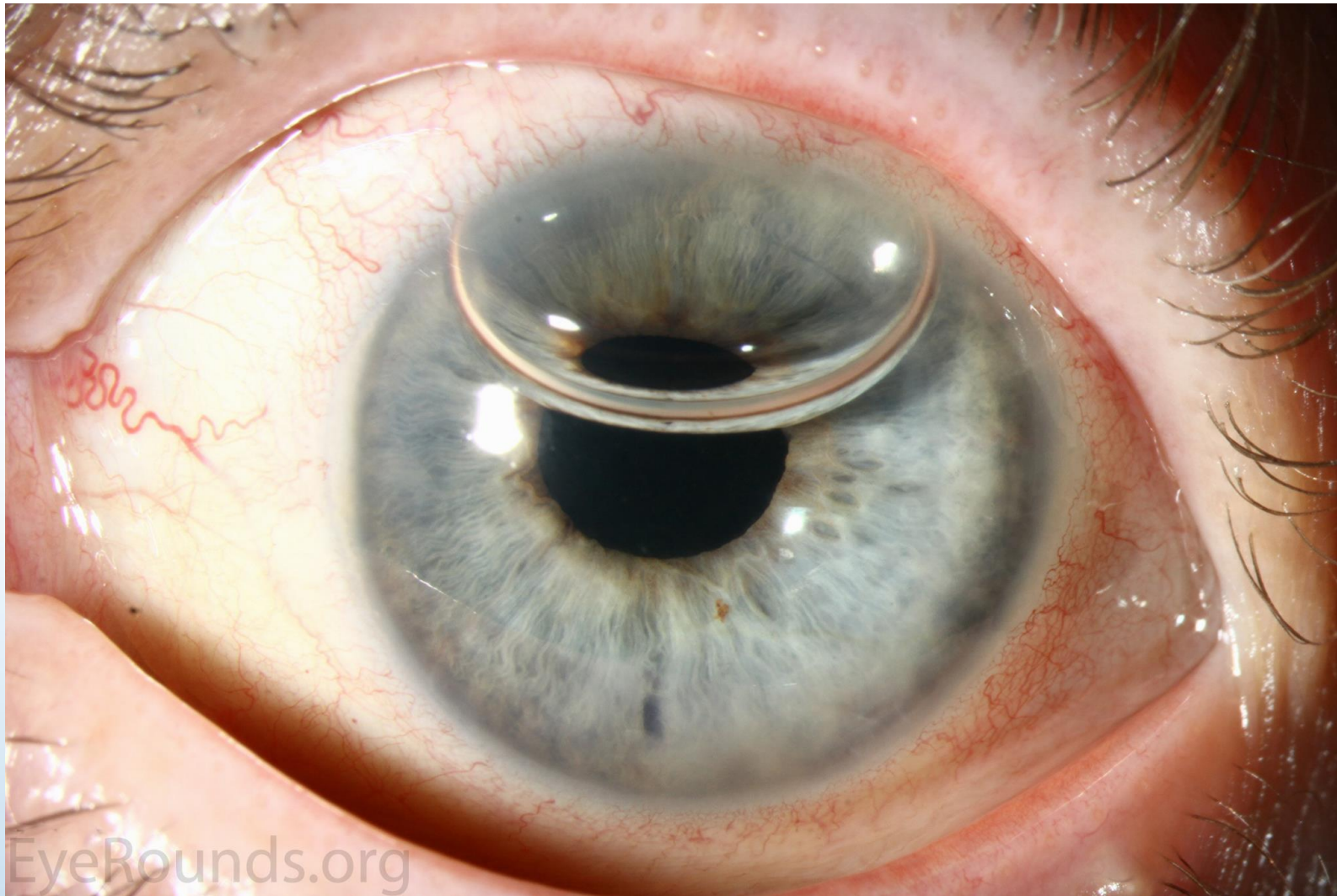


https://www.google.com/url?sa=i&url=https%3A%2F%2Fwww.reviewofoptometry.com%2Farticle%2Fadvances-in-endothelial-surgery-an-update-for-ods&psig=AOvVaw3Ucpp07mE4UAuVQXiy_3T9L&ust=1742819628768000&source=images&cd=vfe&opi=89978449&ved=0CBQQjRxqFwoTCPjotp6boIwDFQAAAAAdAAAAABAE


https://www.google.com/url?sa=i&url=https%3A%2F%2Fcyreseye.com%2Fservice%2Fcorneal-transplants-dsaek-dmek-dalk%2F&psig=AOvVaw1JBXkkpB-NWQIGPofQDjEz&ust=1742819838166000&source=images&cd=vfe&opi=89978449&ved=0CBQQjRxqFwoTCPDF_YCcolwDFQAAAAAdAAAAABAR

AANP


Air bubble to hold DMEK in place



<https://webeye.ophth.uiowa.edu/eyeforum/tutorials/cornea-transplant-intro/8A-LRG-sp-DMEK-for-Fuchs.jpg>



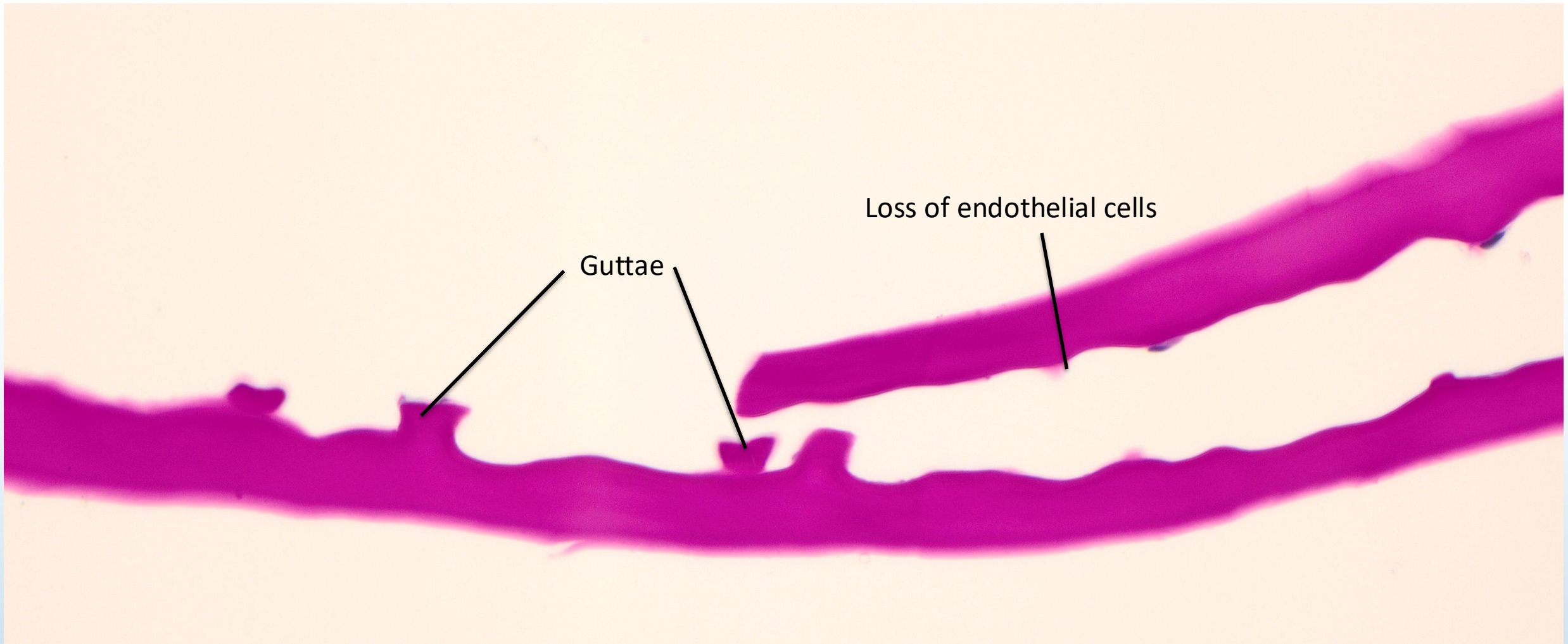
DMEK or DSAEK for bullous keratopathy (PAS)



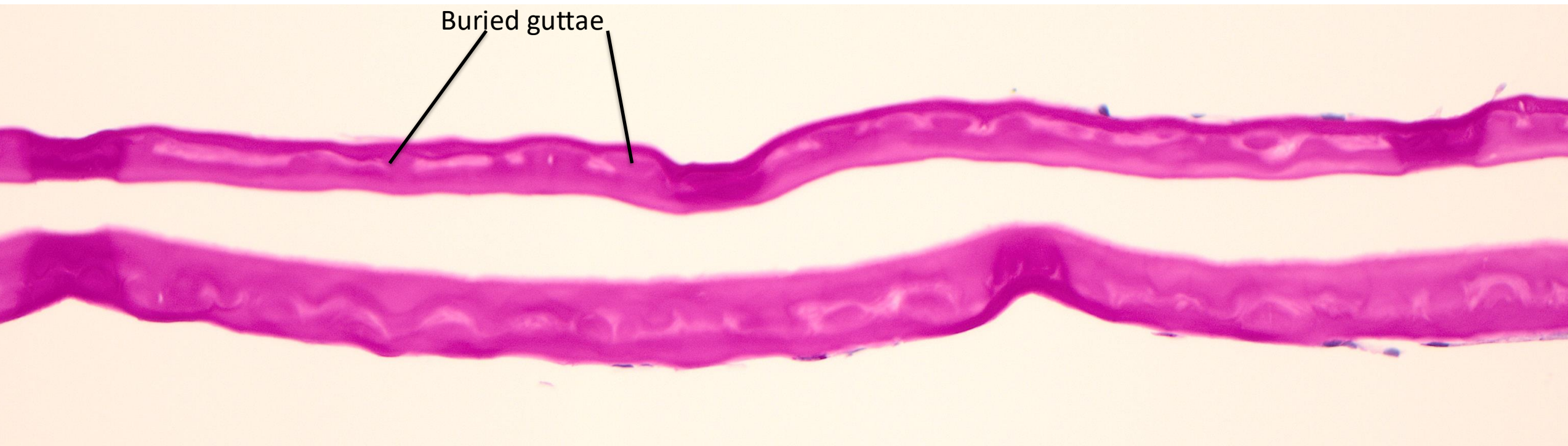Descemet's membrane; no corneal endothelial cells and no guttae



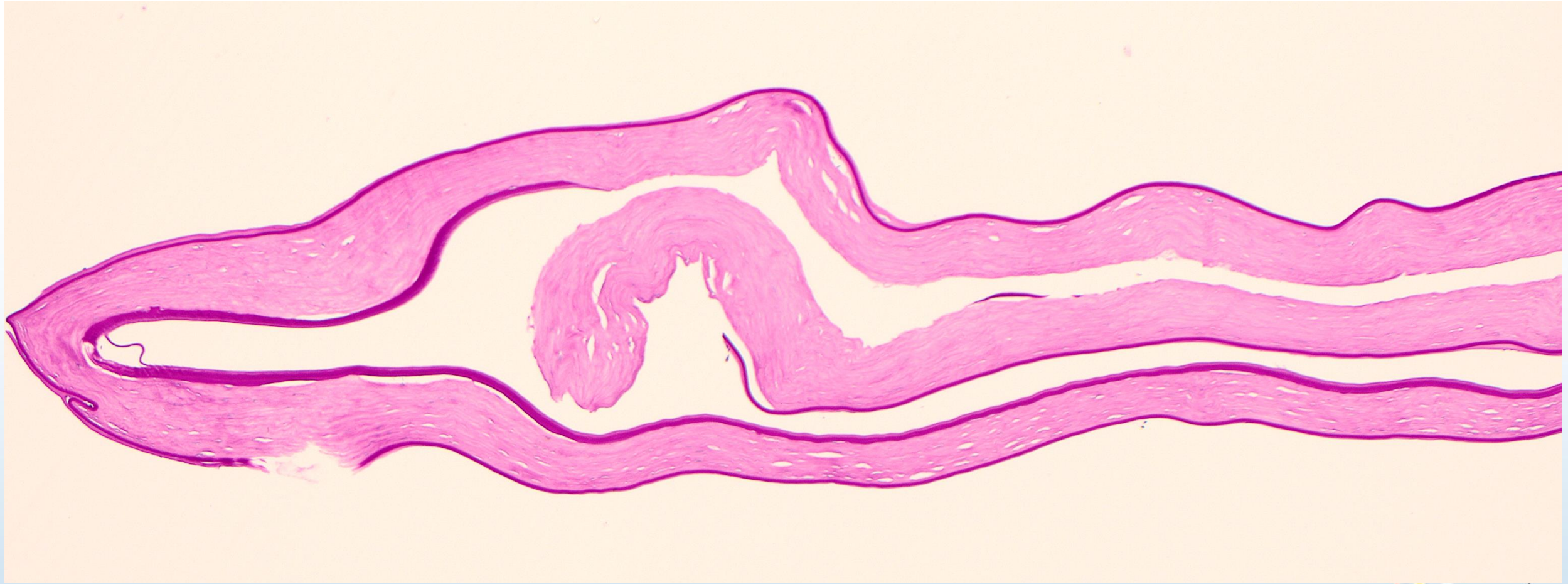DMEK or DSAEK or DWEK for Fuchs' endothelial corneal dystrophy (PAS)

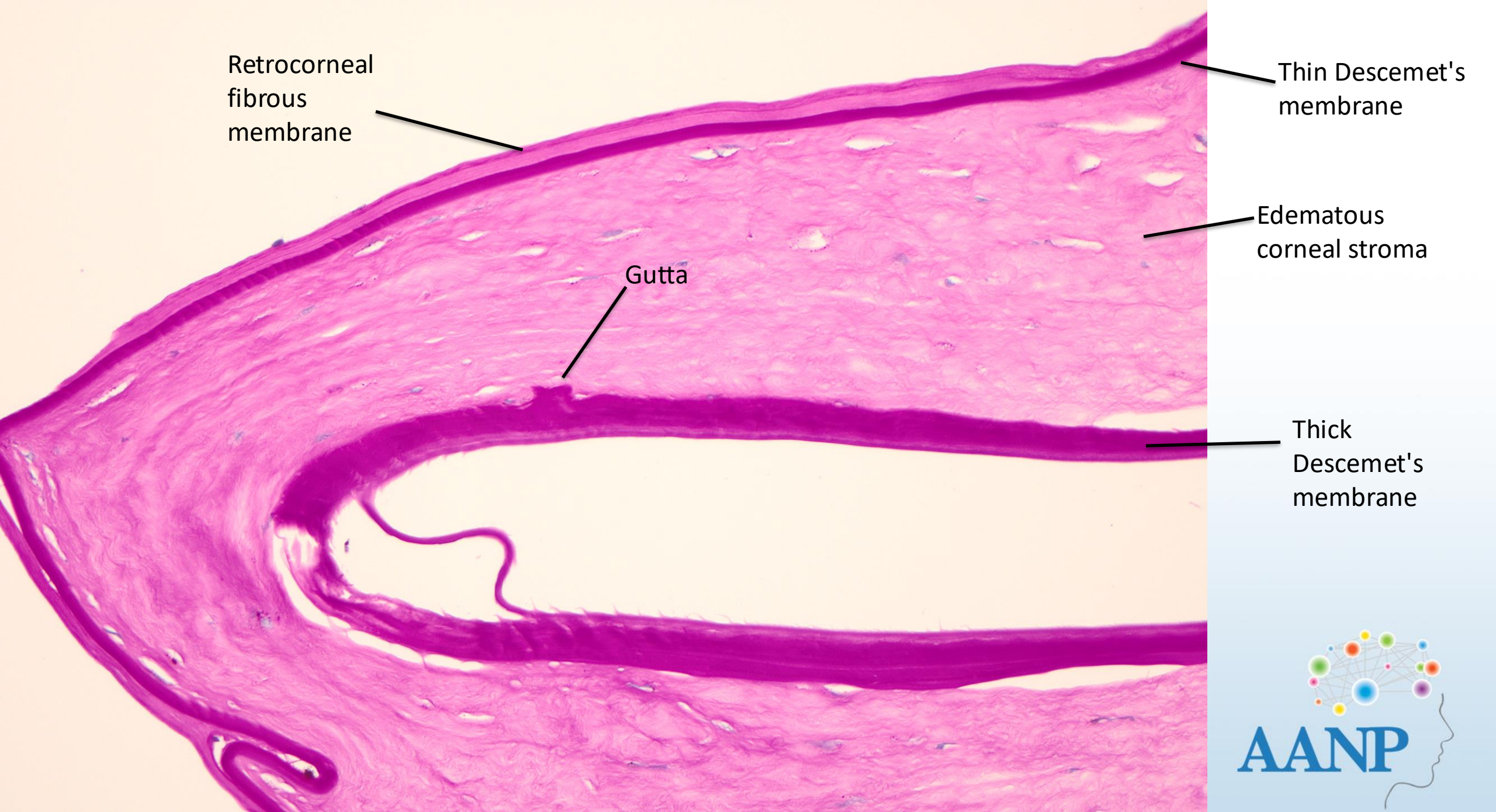


DMEK or DSAEK or DWEK for Fuchs' endothelial corneal dystrophy (PAS)



Failed DSAEK graft – undergoing repeat DSAEK





Retrocorneal
fibrous
membrane

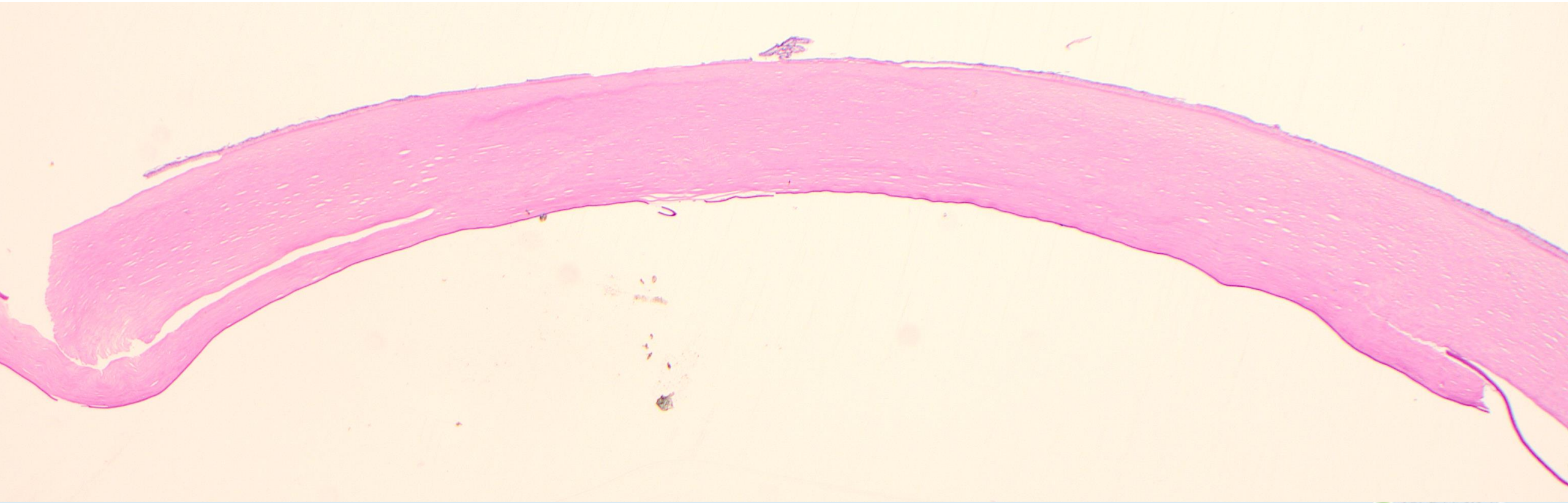
Thin Descemet's
membrane

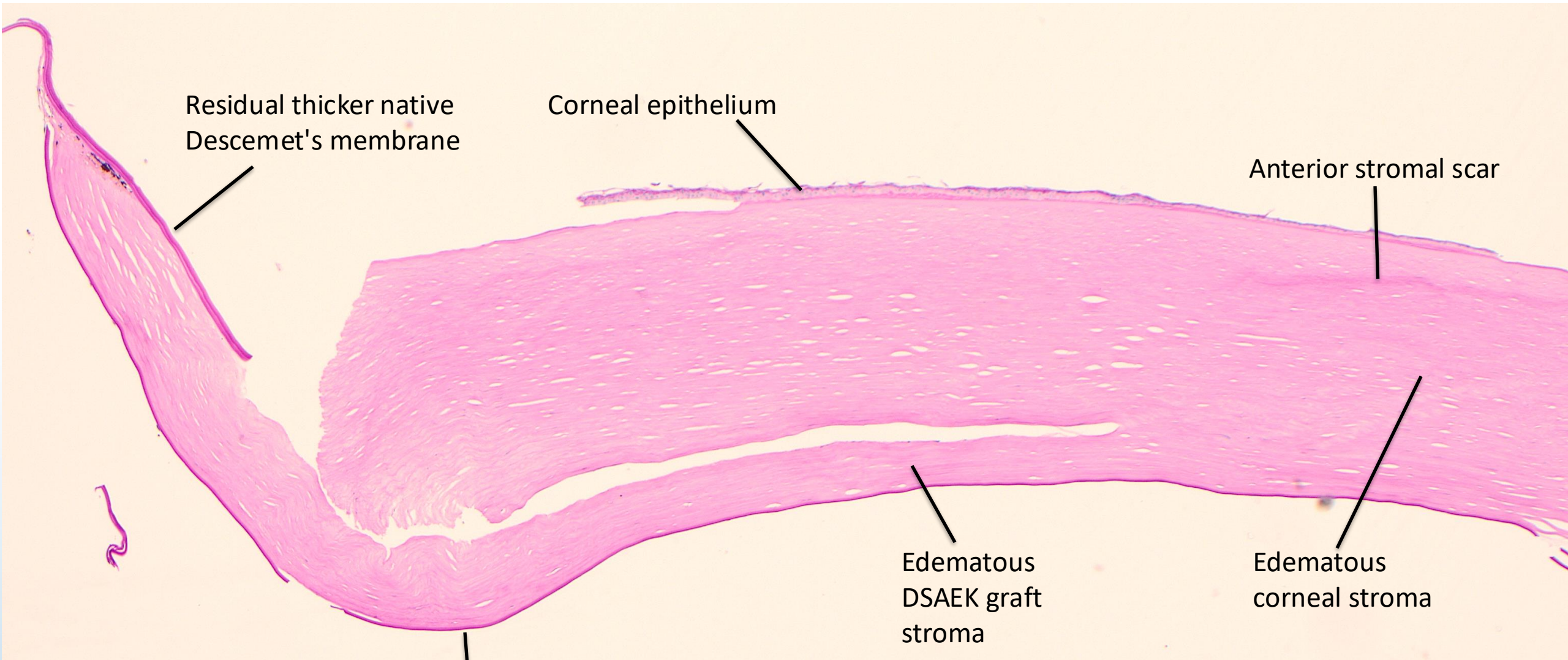
Edematous
corneal stroma

Gutta

Thick
Descemet's
membrane

Penetrating keratoplasty after failed DSAEK





Residual thicker native Descemet's membrane

Corneal epithelium

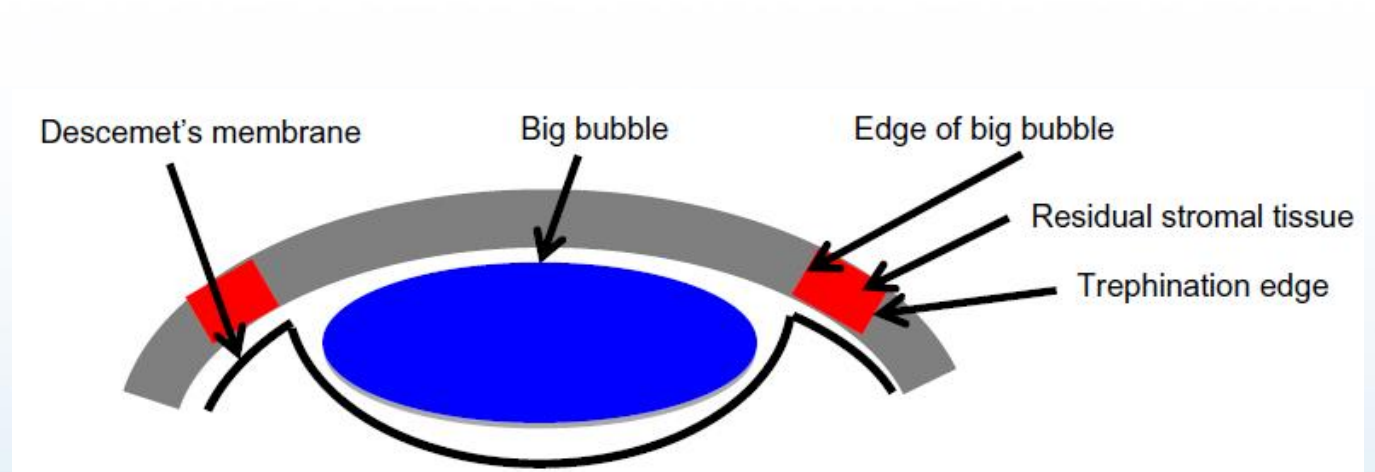
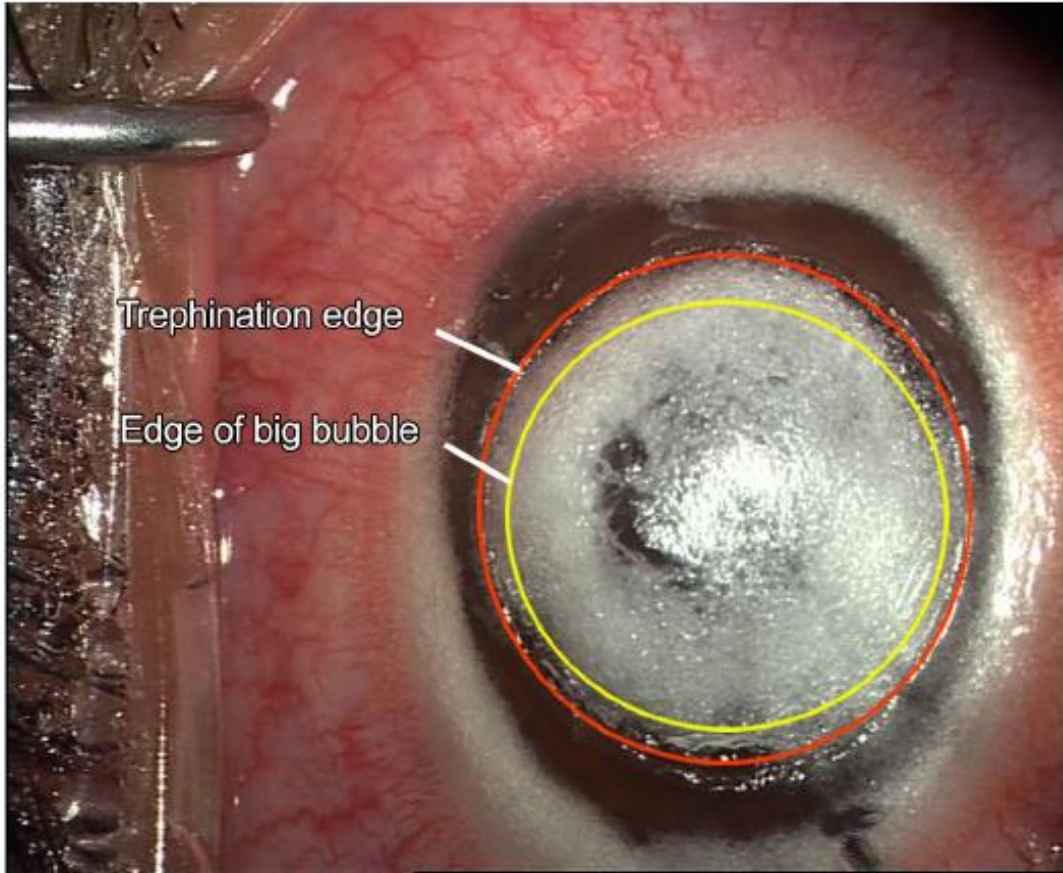
Anterior stromal scar

Edematous DSAEK graft stroma

Edematous corneal stroma

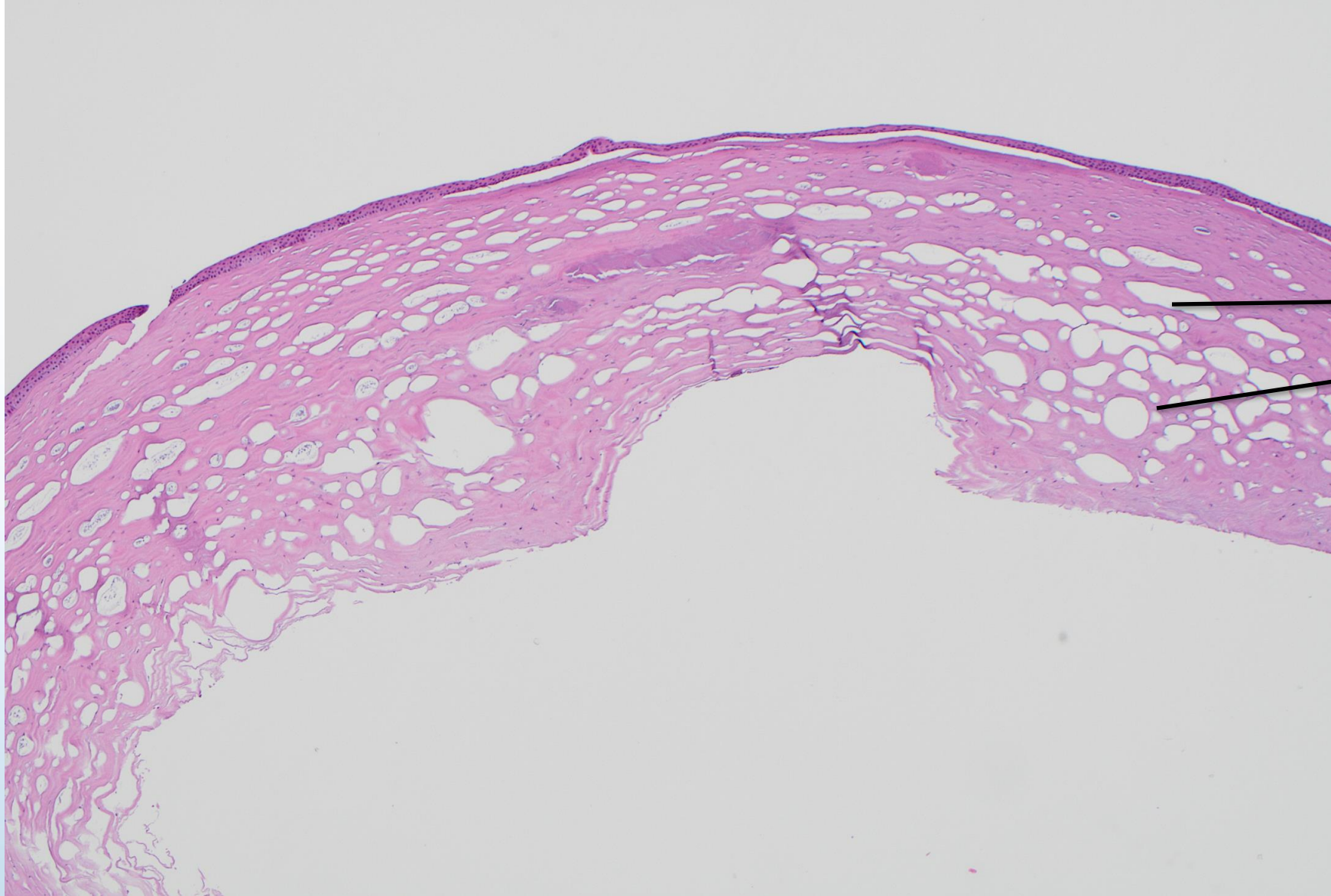
DSAEK graft: thin Descemet's membrane with no guttae and no endothelial cells

Deep Anterior Lamellar Keratoplasty (DALK)



https://www.dovepress.com/article/fulltext_file/52395/aW1n/fig1.jpg

DALK – air bubble artifact in corneal stroma



Air bubbles
from DALK
procedure


Surgical Procedures of the Cornea

Refractive Procedures:


- radial keratotomy (RK)
- laser in-situ keratomileusis (LASIK)
- photorefractive keratectomy (PRK)
- superficial keratectomy
- corneal crosslinking



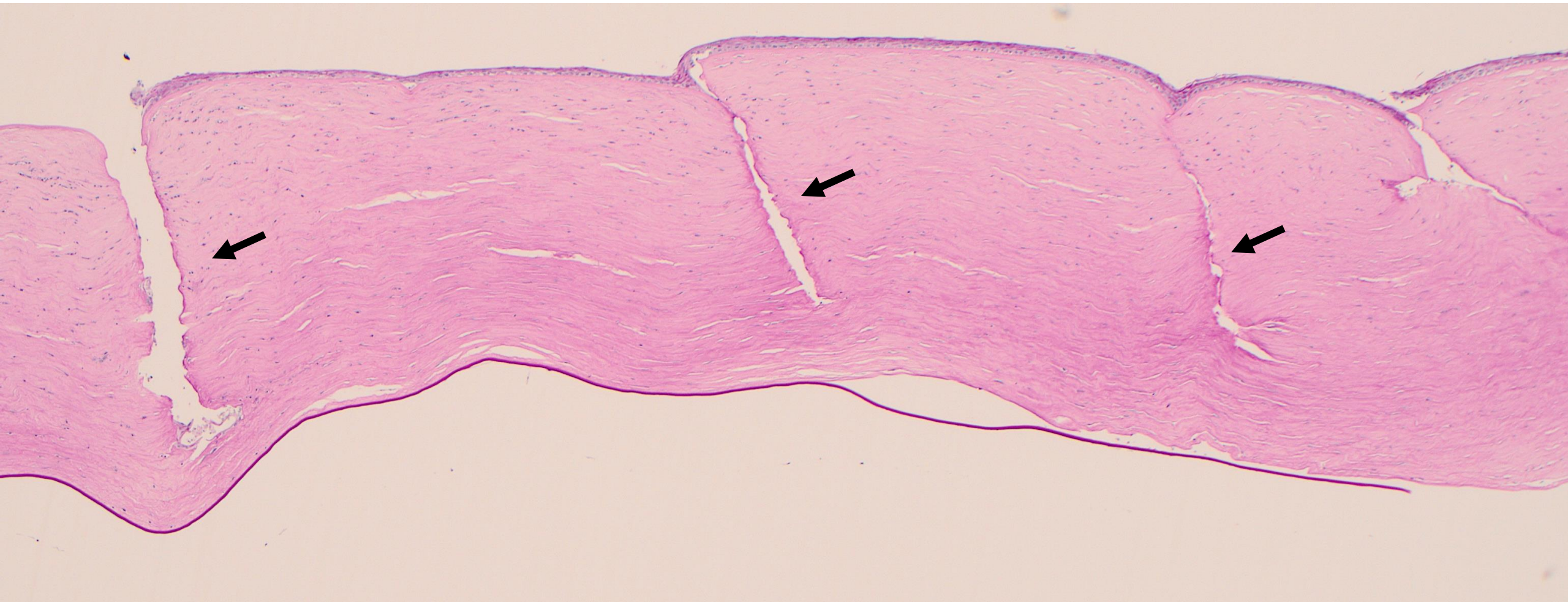
Radial Keratotomy

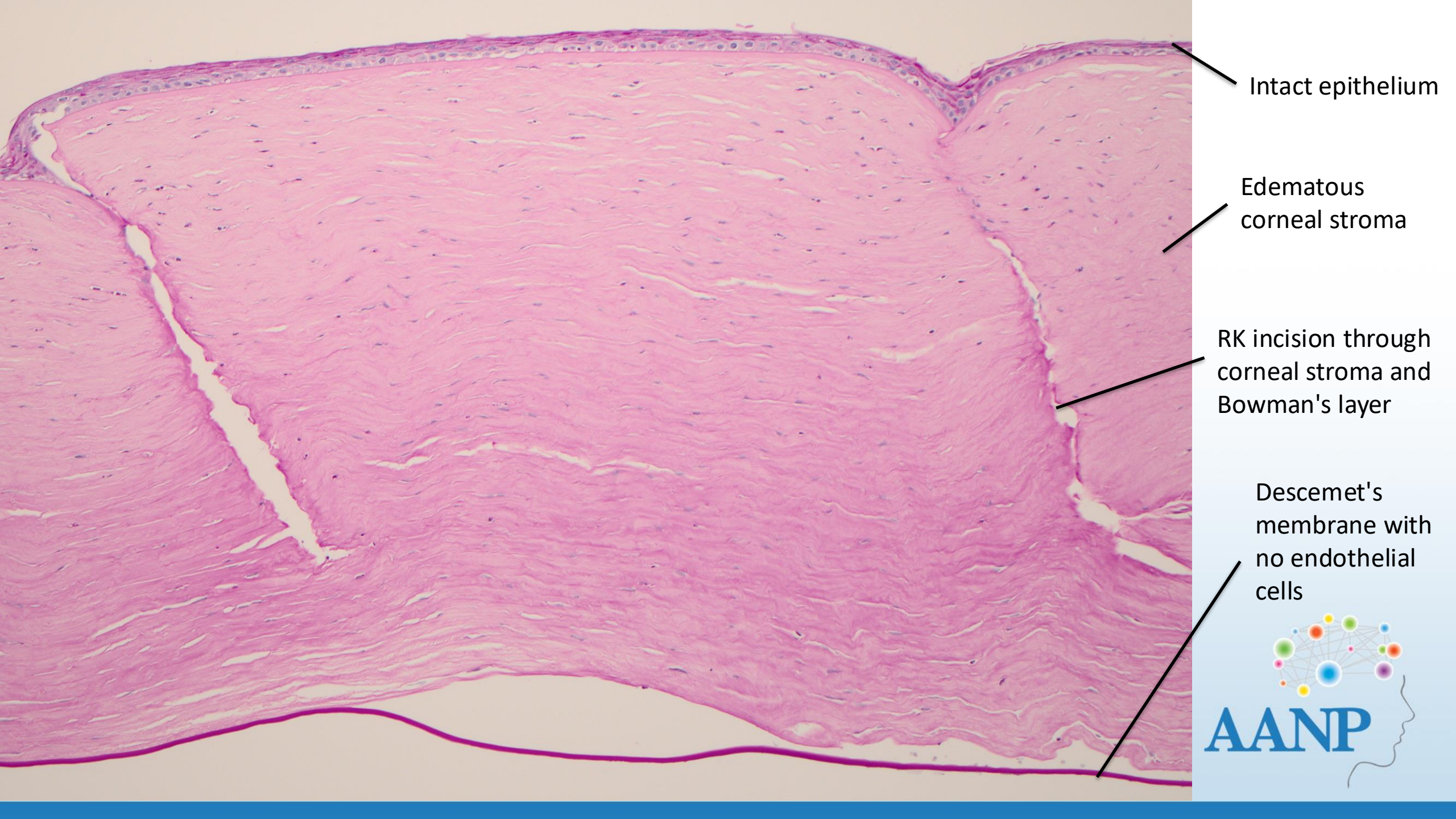


<https://www.gulanivision.com/radial-keratotomy-rk/can-radial-keratotomy-rk-surgery-complications-be-fixed-yes/>



Penetrating Keratoplasty for Corneal Edema in a Cornea with Prior Radial Keratotomy





Intact epithelium

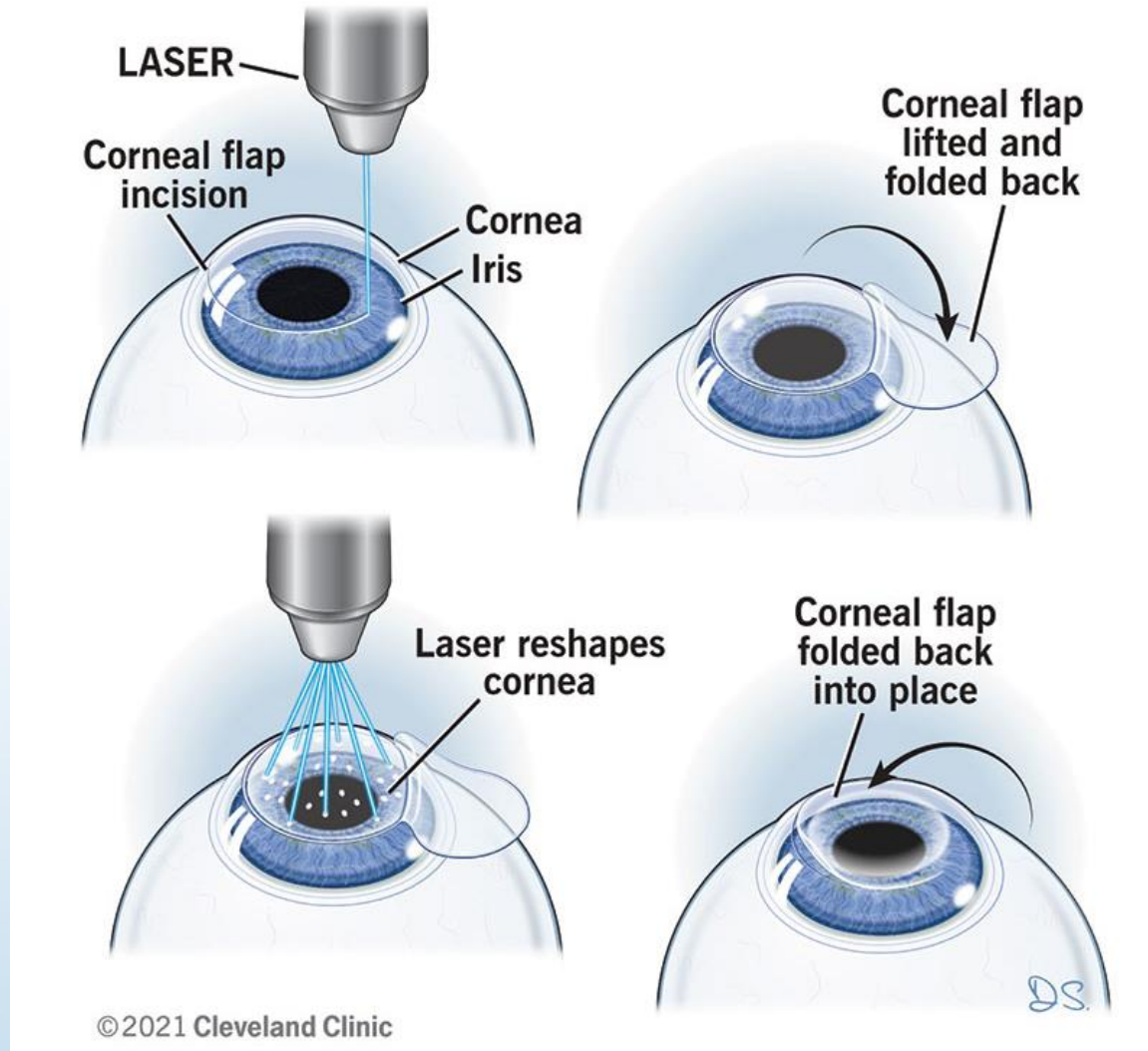
Edematous corneal stroma

RK incision through corneal stroma and Bowman's layer


Descemet's membrane with no endothelial cells



Laser-Assisted In-Situ Keratomileusis (LASIK)



<https://my.clevelandclinic.org/health/treatments/21805-lasik-eye-surgery>



Eye enucleated for uveal melanoma

Corneal incision scar from
prior cataract surgery

LASIK flap

Iris

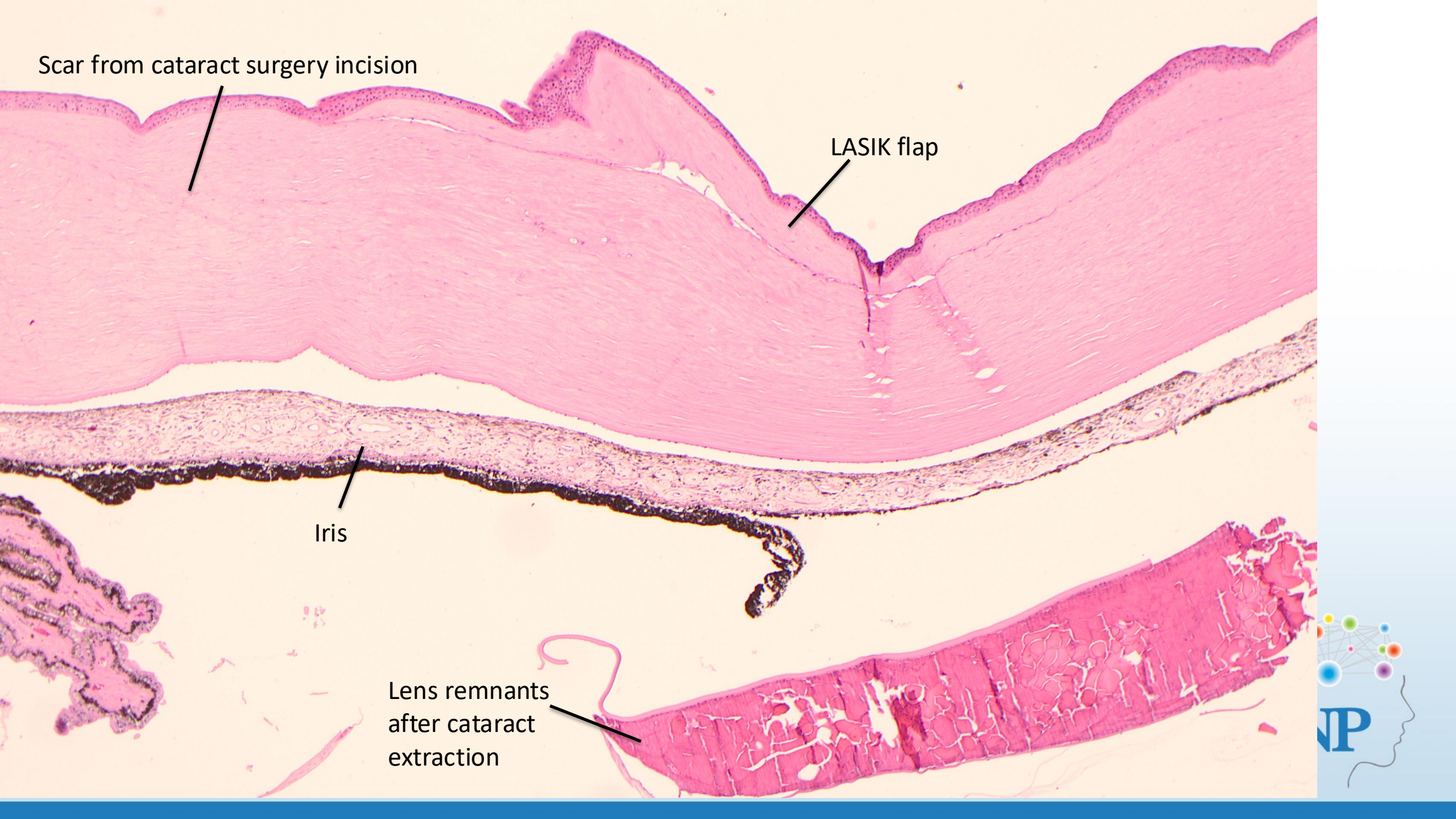
Lens remnants after cataract extraction; Soemmering ring

Scar from cataract surgery incision

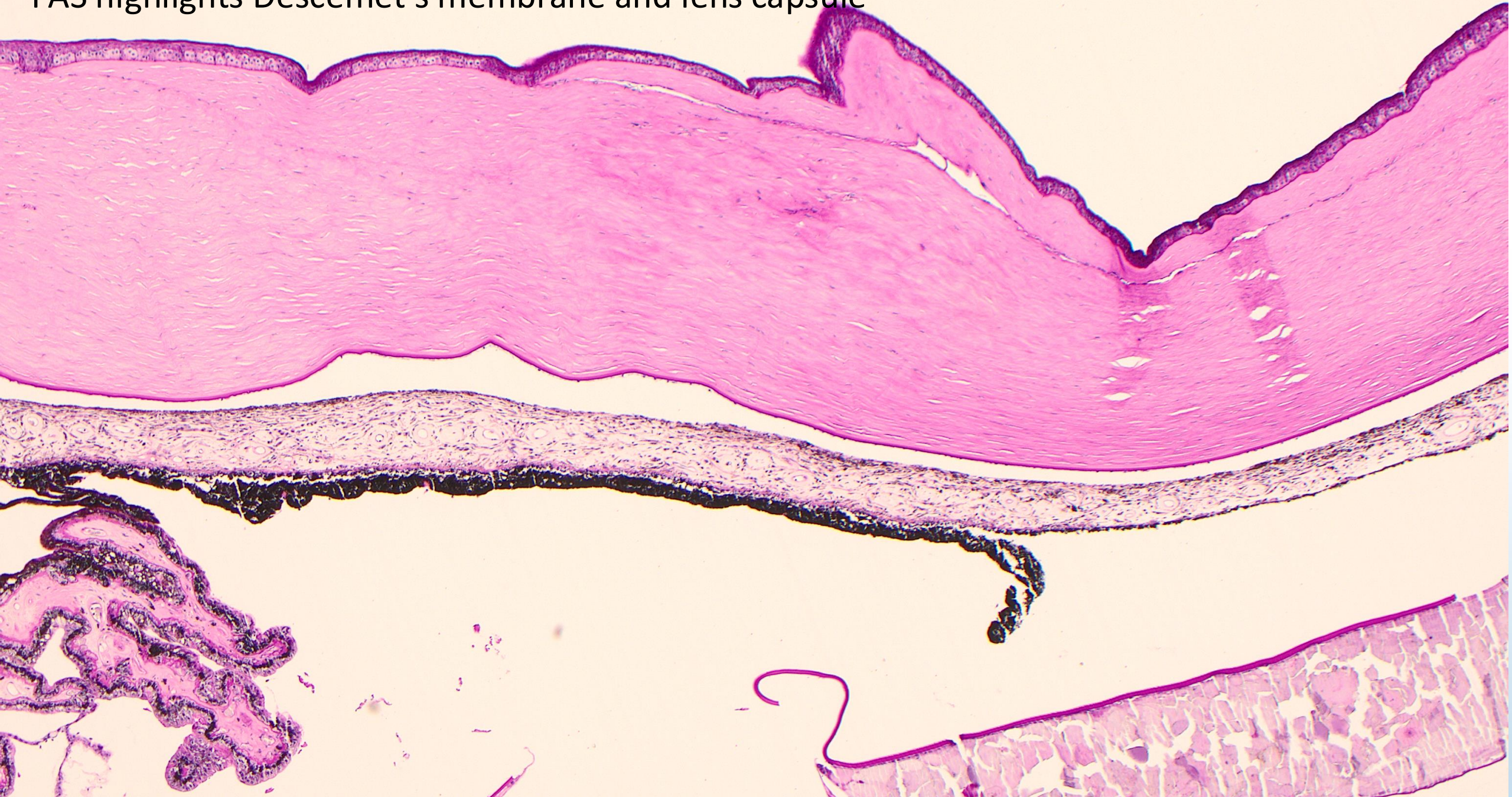LASIK flap

Iris

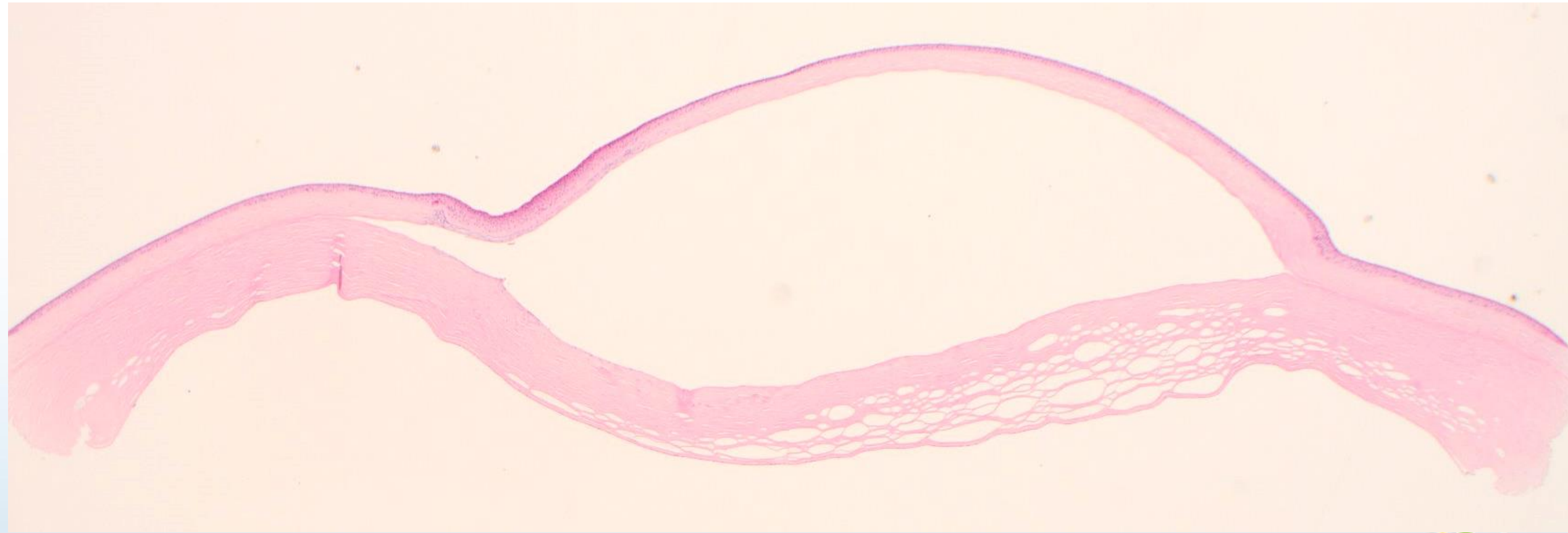Lens remnants
after cataract
extraction

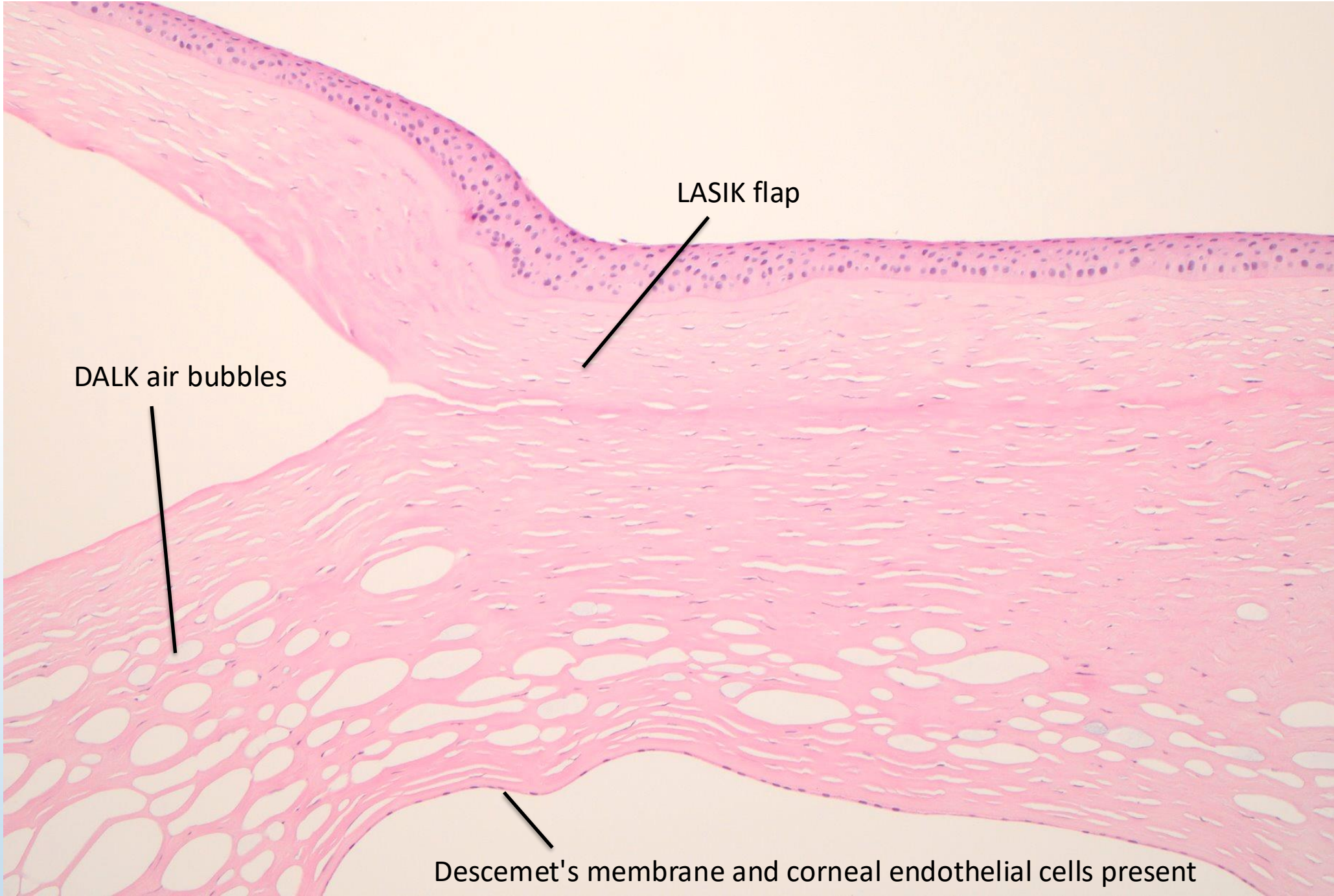


PAS highlights Descemet's membrane and lens capsule



Corneas can have evidence of multiple prior procedures





LASIK flap

DALK air bubbles

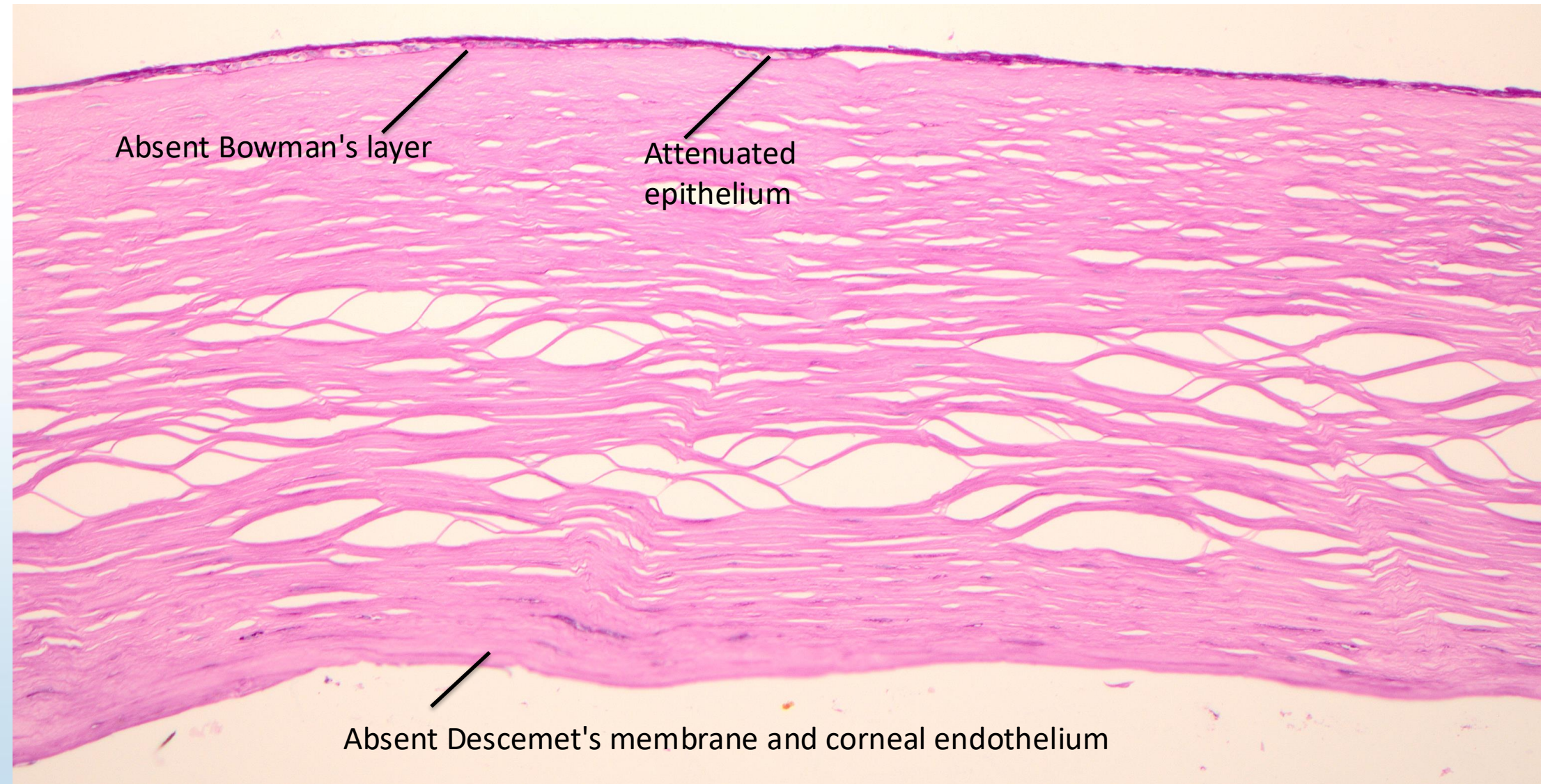
Descemet's membrane and corneal endothelial cells present



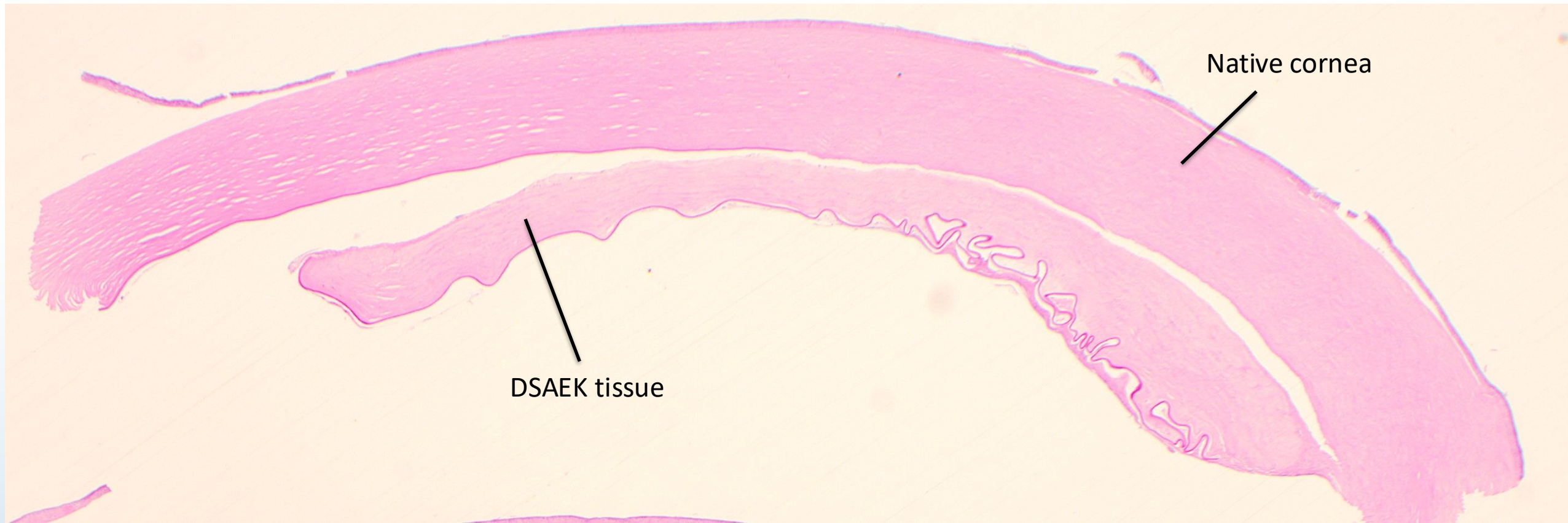

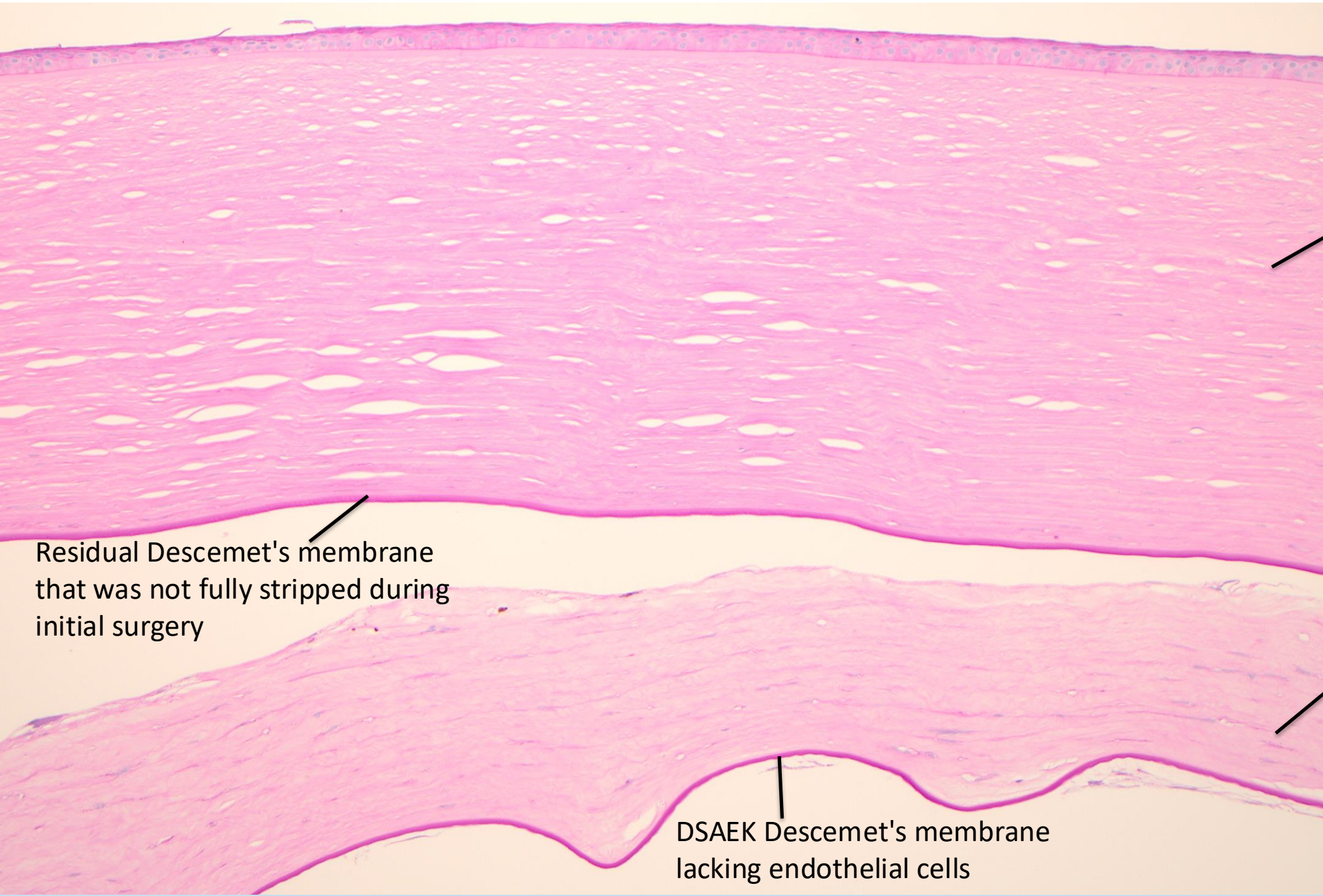
Cornea with a history of LASIK, that underwent an attempted DALK and was converted to a PK

Aborted DSAEK (or DMEK or DWEK) converted to PK (& prior anterior stromal keratoplasty)



PK after failed DSAEK





Edematous corneal stroma

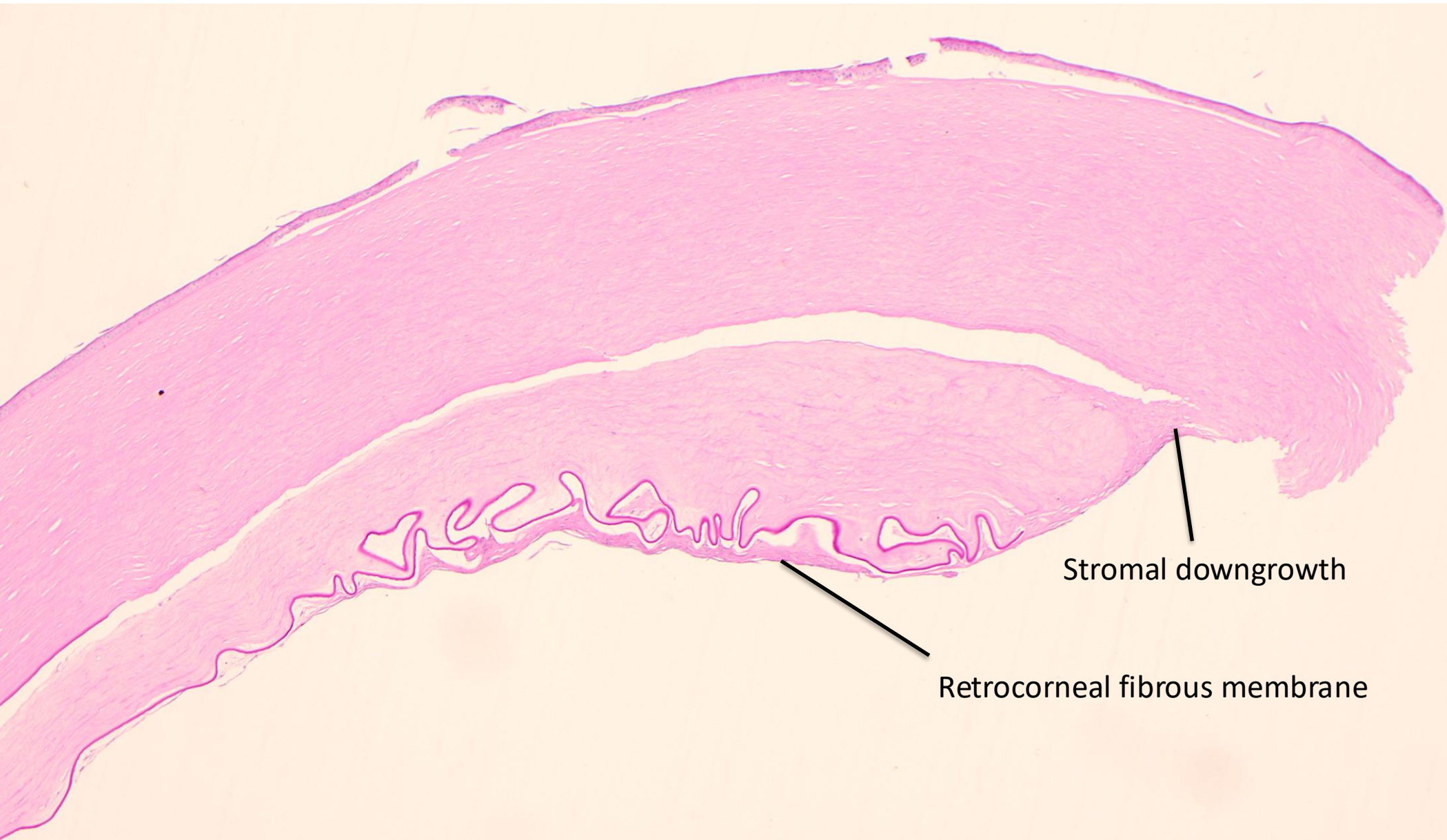
Residual Descemet's membrane that was not fully stripped during initial surgery

Edematous DSAEK stroma

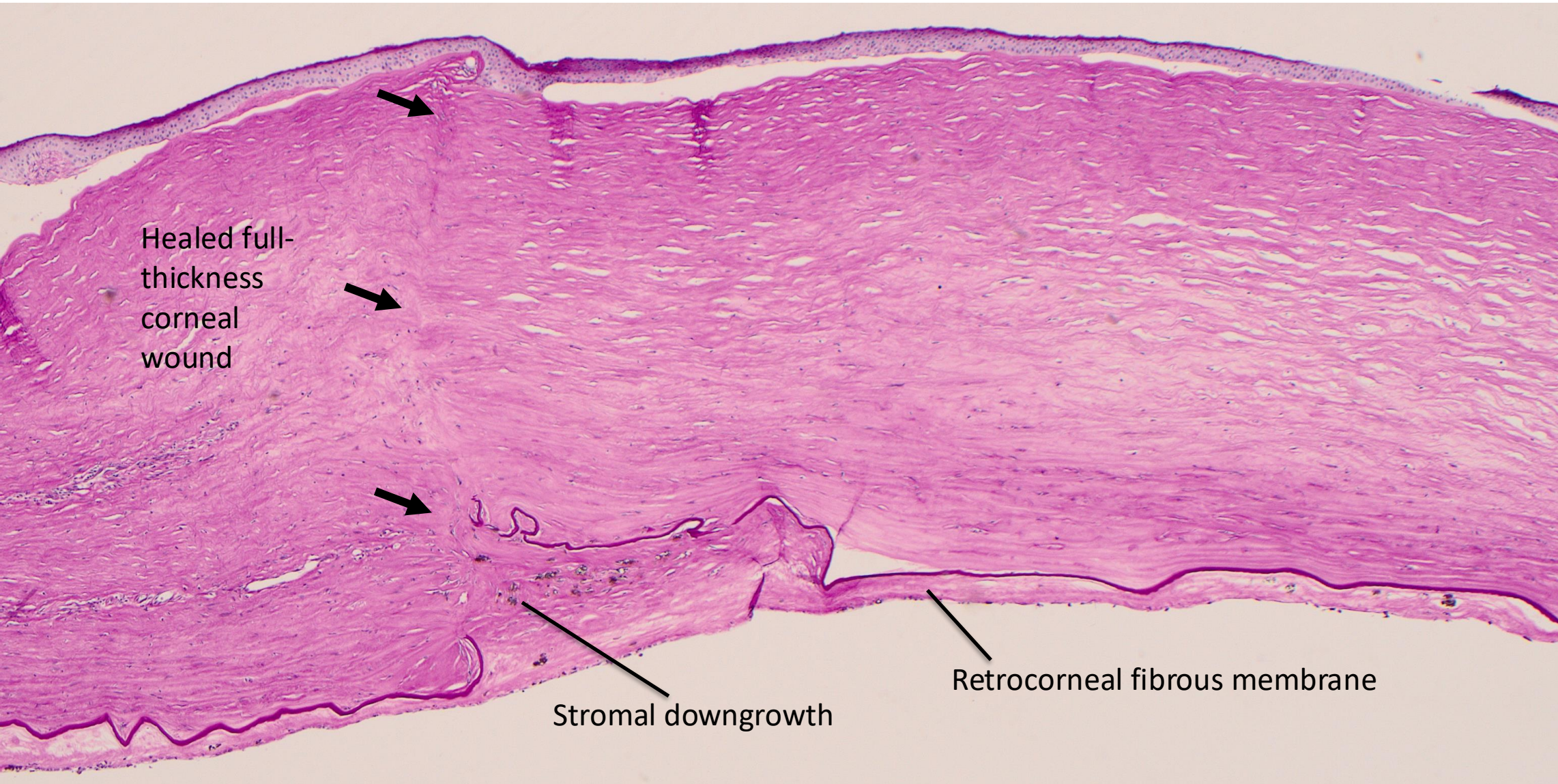
DSAEK Descemet's membrane lacking endothelial cells



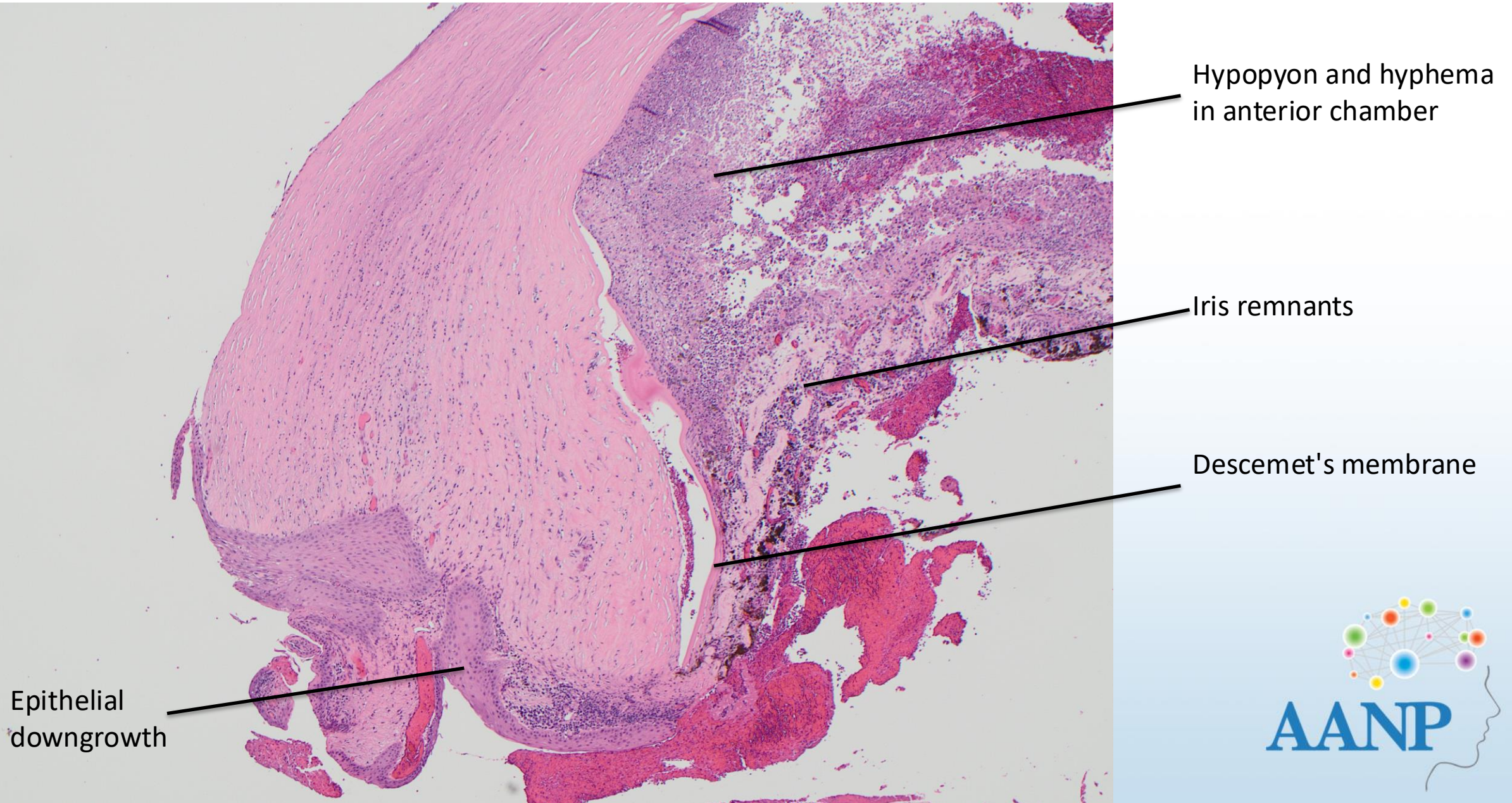
Retrocorneal fibrous membrane

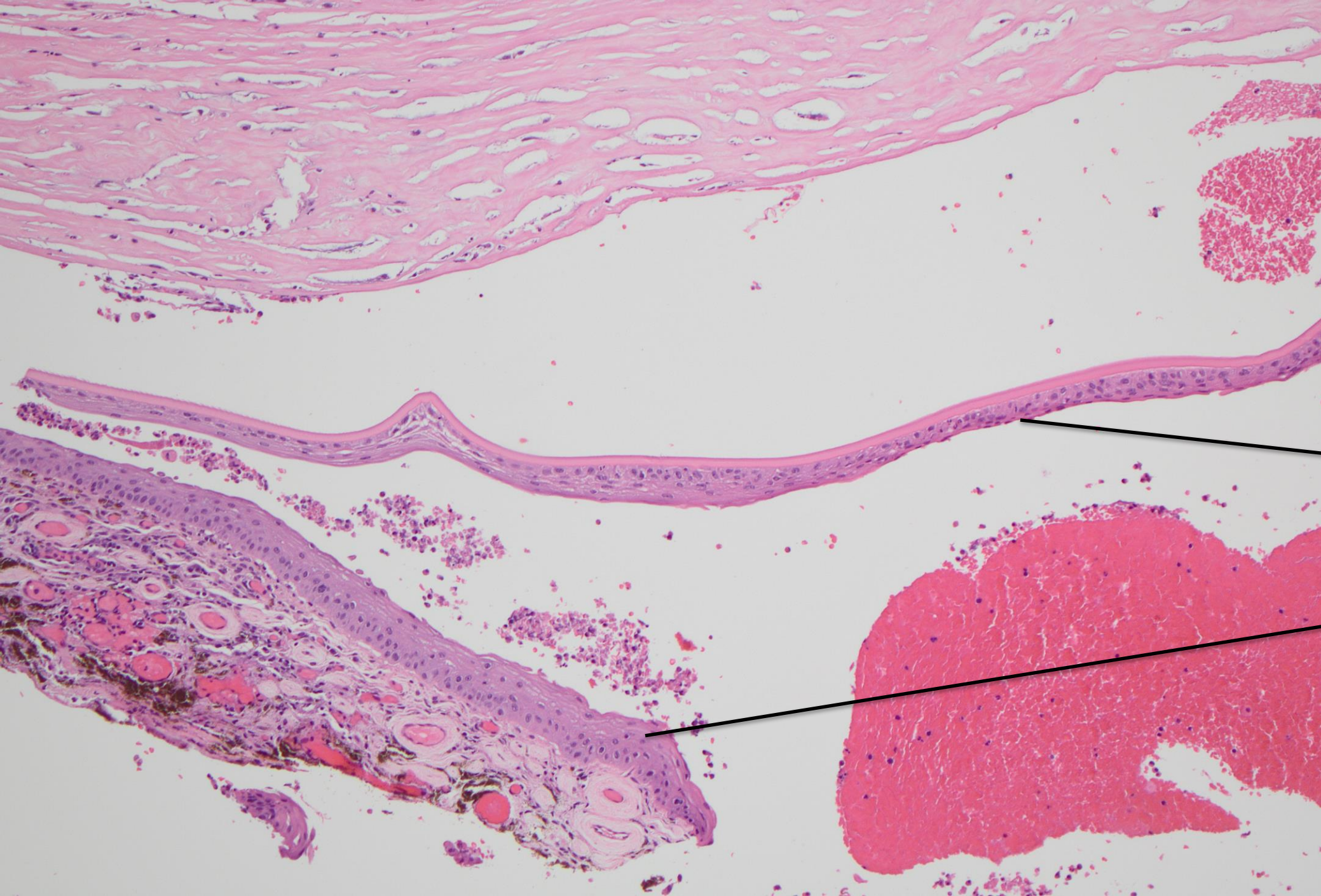


Stromal downgrowth through full-thickness corneal wound



Epithelial downgrowth in a cornea with perforation and infection



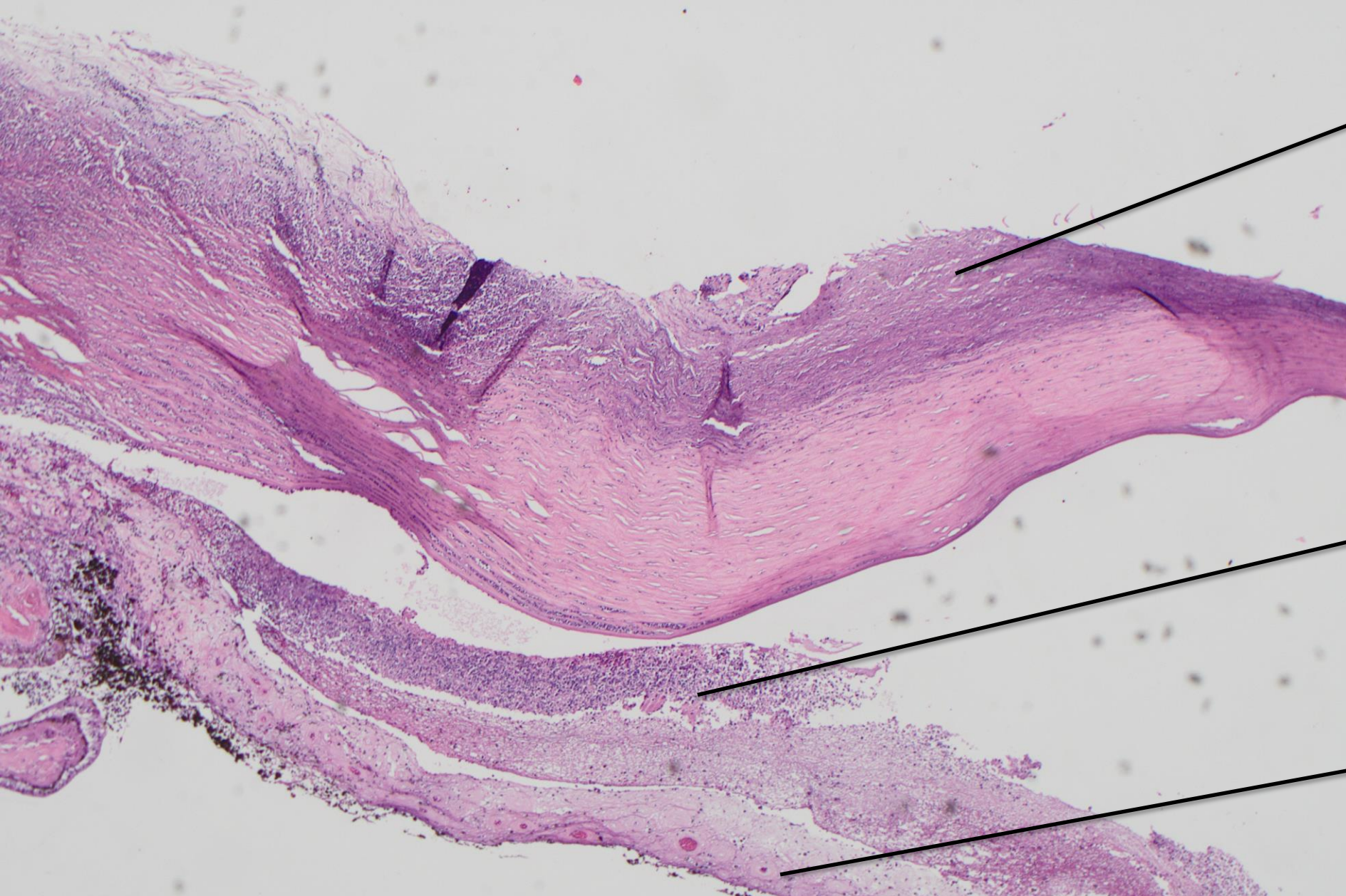


Epithelial
downgrowth coating
Descemet's
membrane

Epithelial
downgrowth coating
Iris



Corneal ulcer with hypopyon



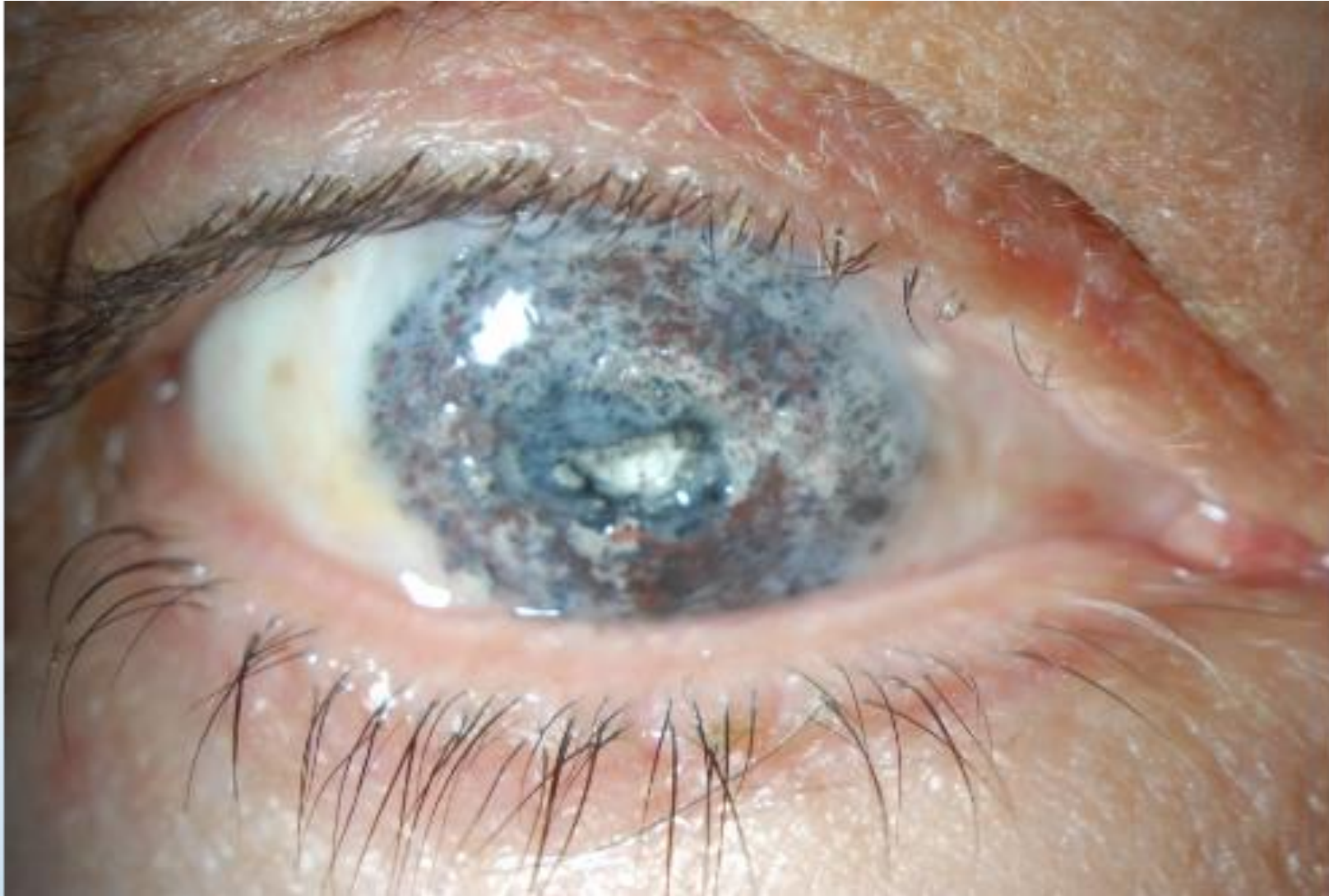
Absent epithelium,
severe stromal
inflammation and
necrosis/melt

Hypopyon in anterior
chamber

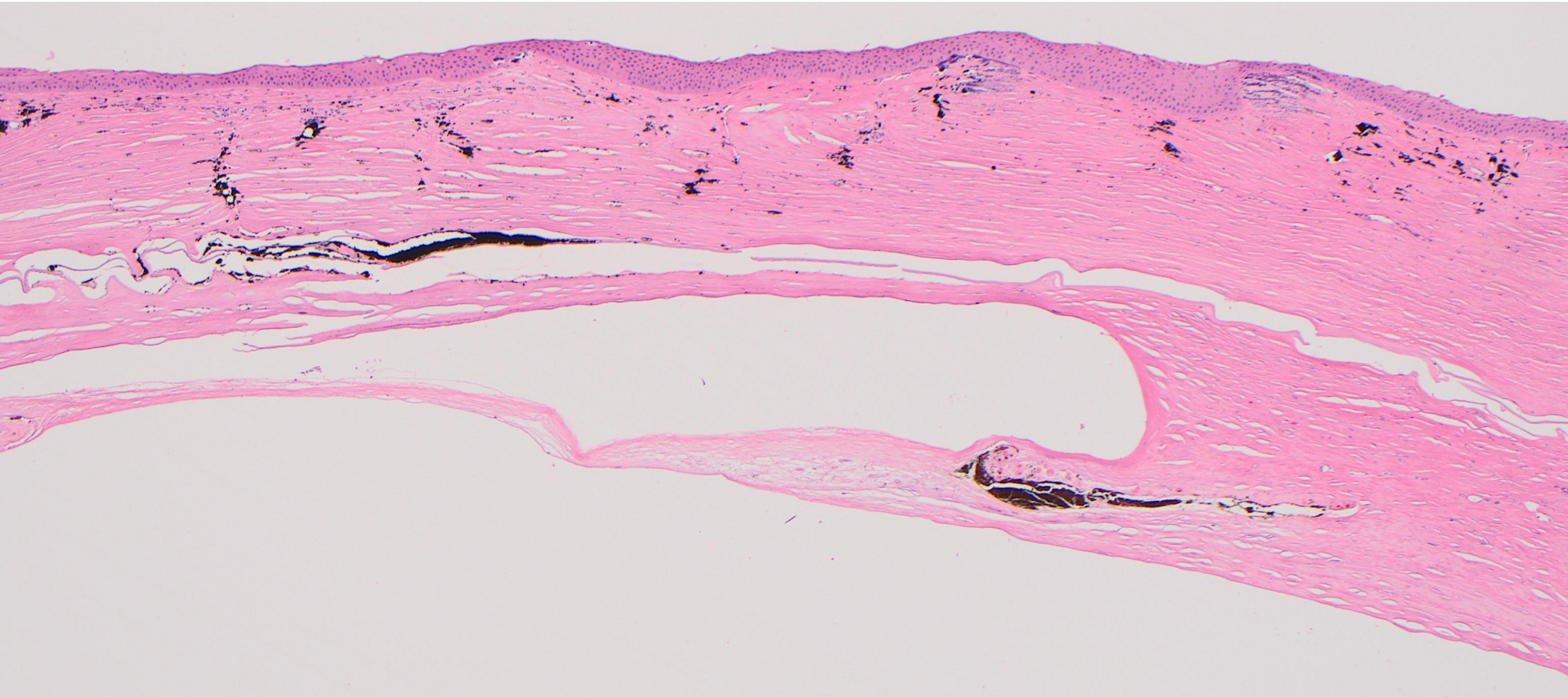
Iris

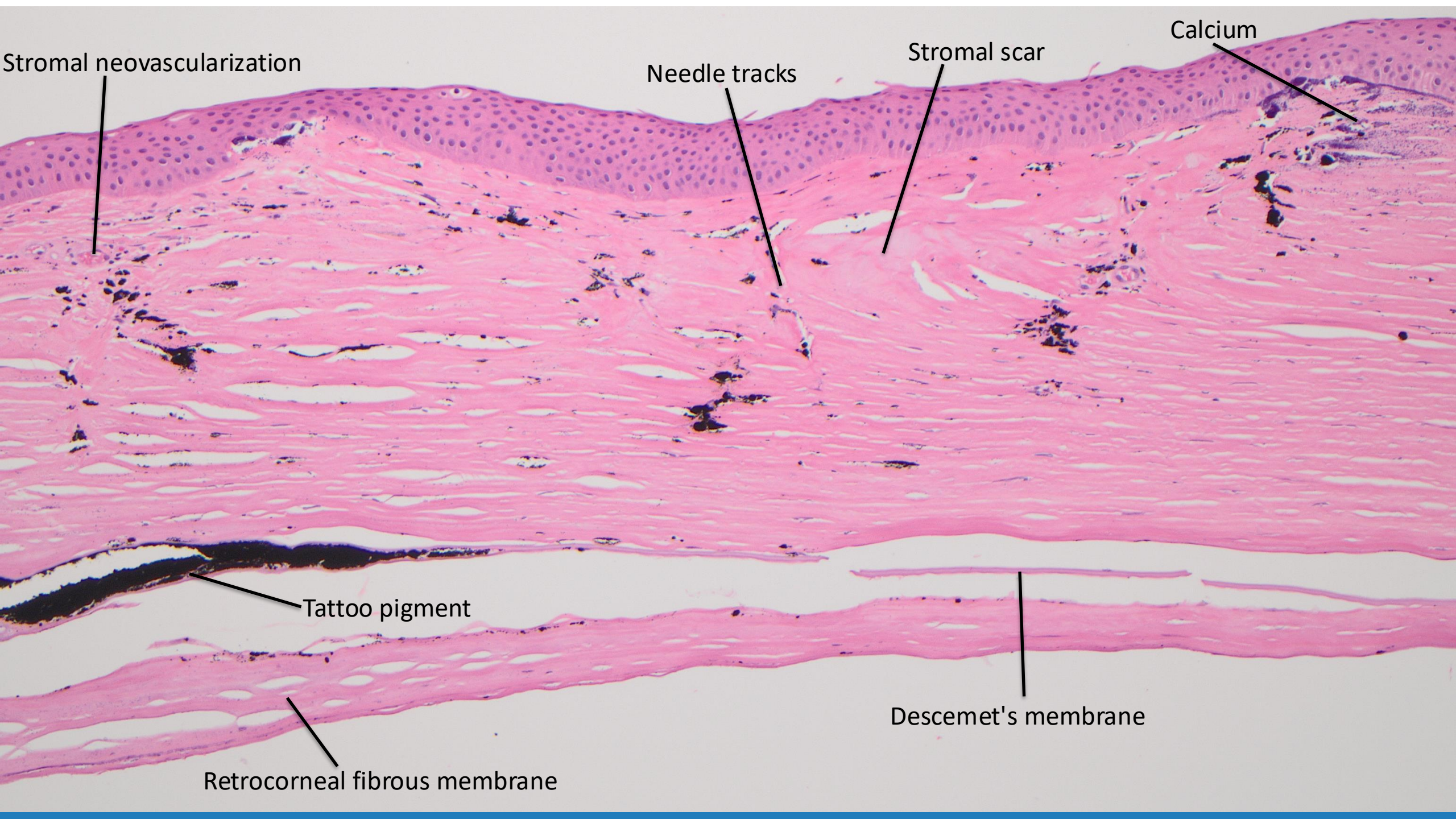


Corneal Tattoo (Keratopigmentation)



target: mid-stromal depth – small incision or laser-assisted





Stromal neovascularization

Needle tracks

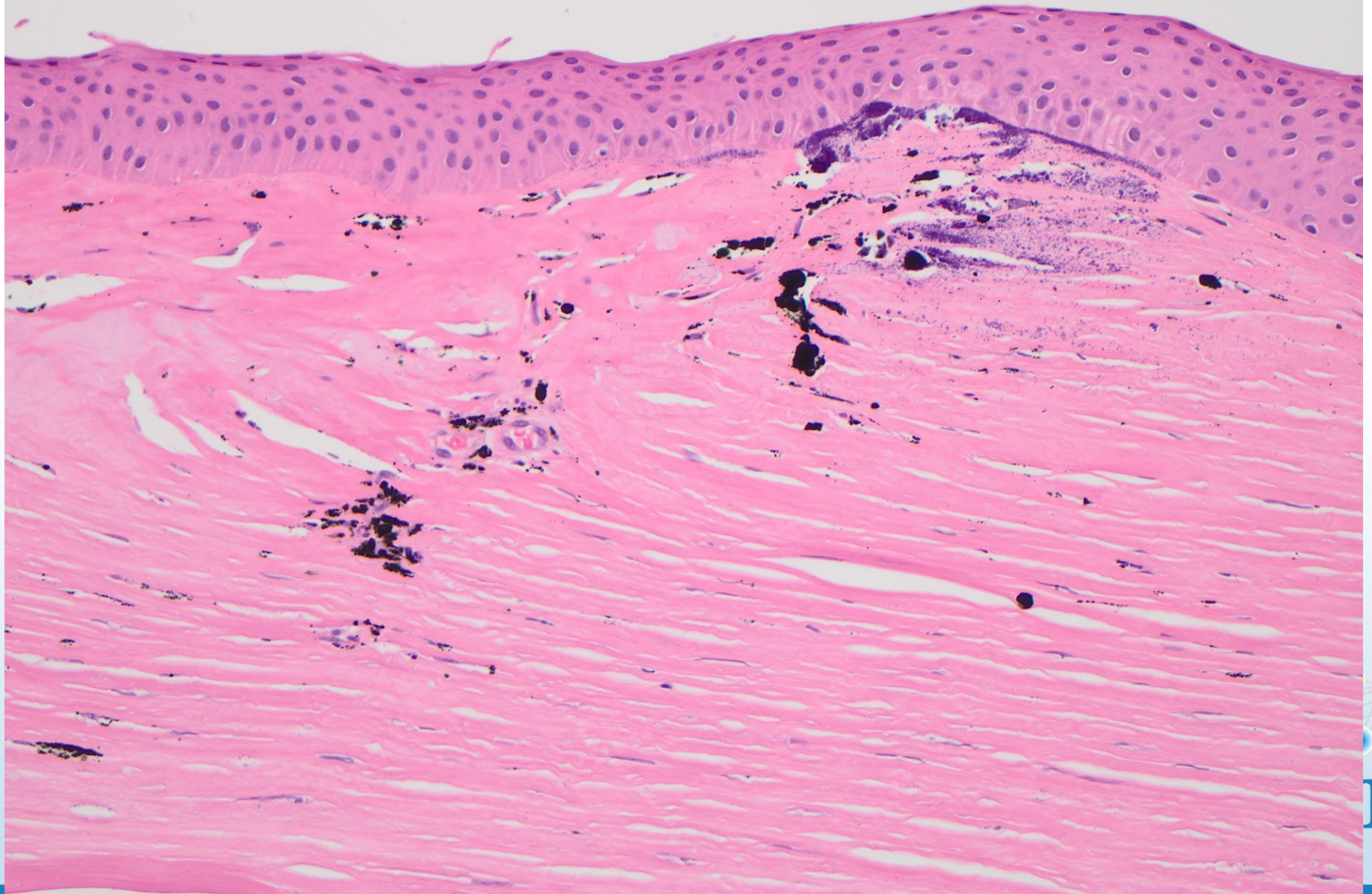
Stromal scar

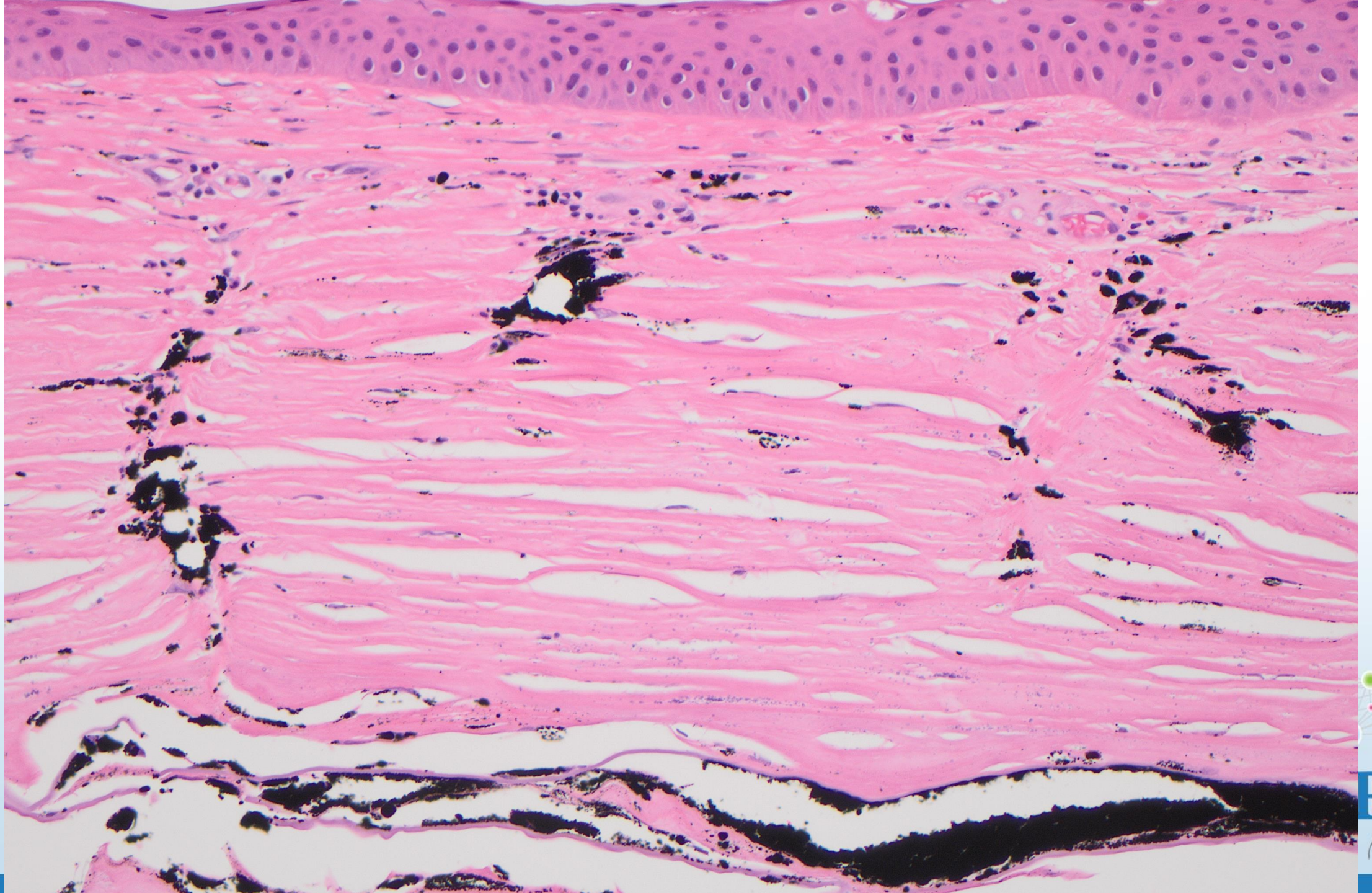
Calcium

Tattoo pigment

Descemet's membrane

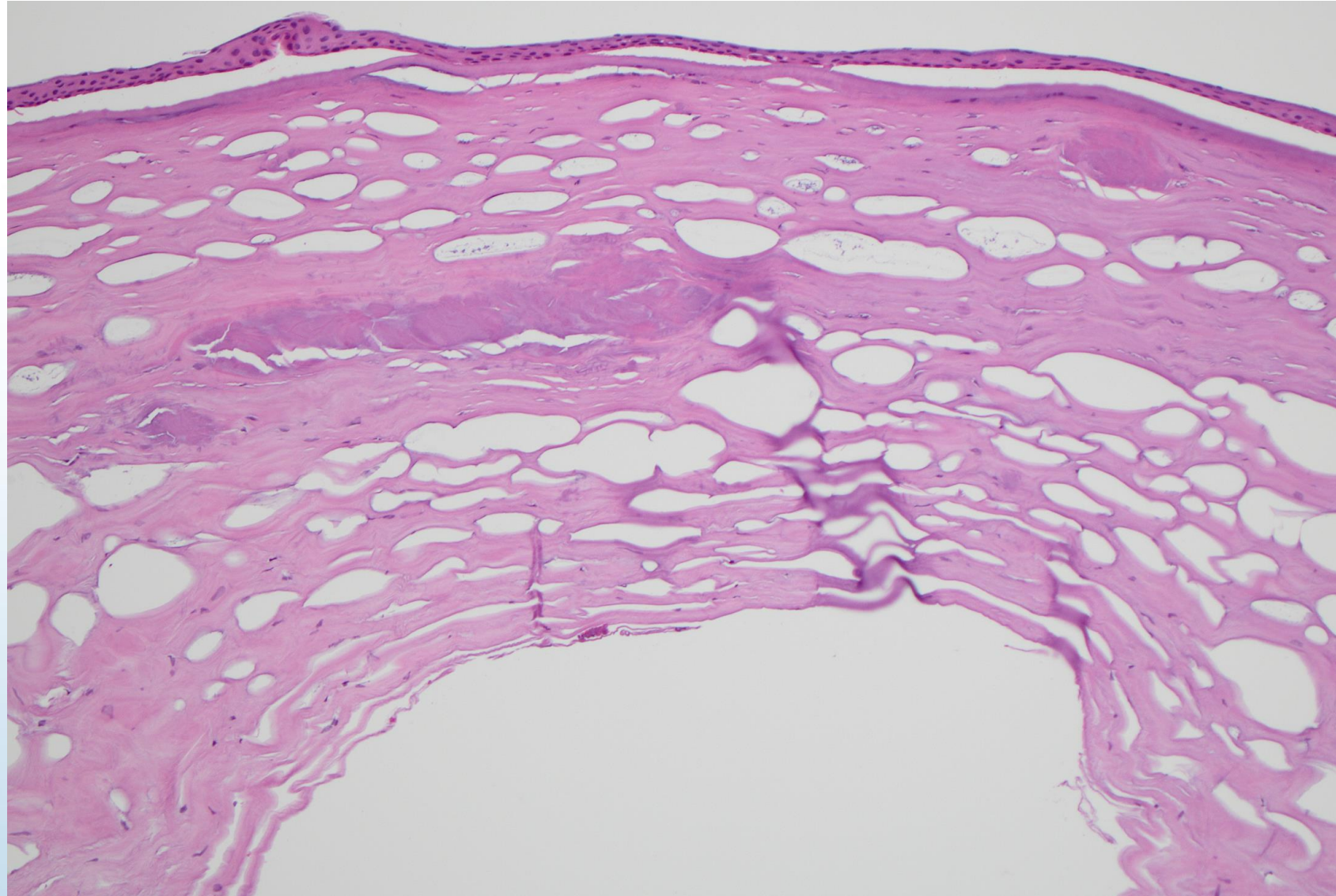
Retrocorneal fibrous membrane






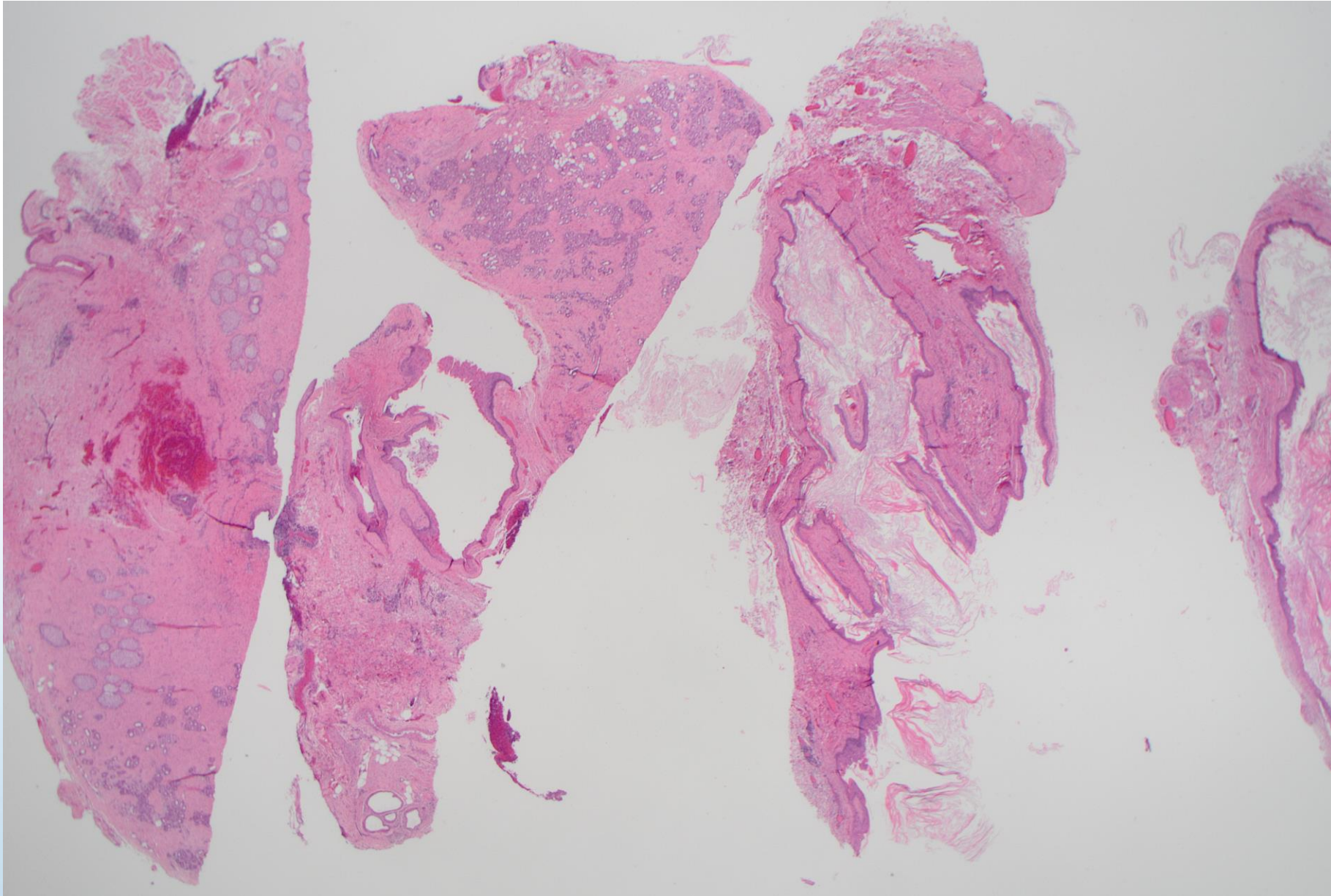
Summary – Case 1:

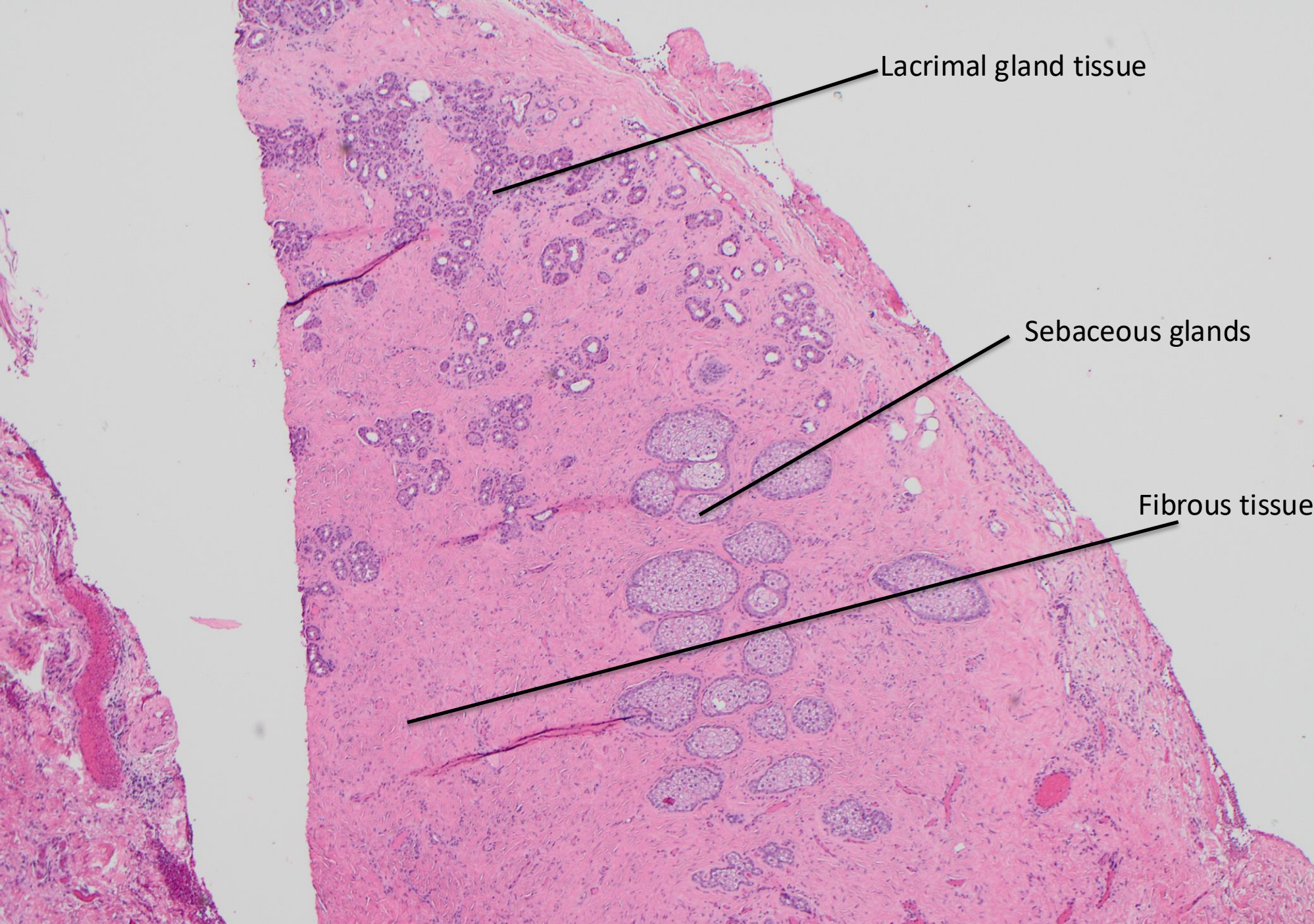
DALK in Granular Dystrophy Type 2 (Avellino Dystrophy)





Case #2: Eyelid lesion





Lacrimal gland tissue

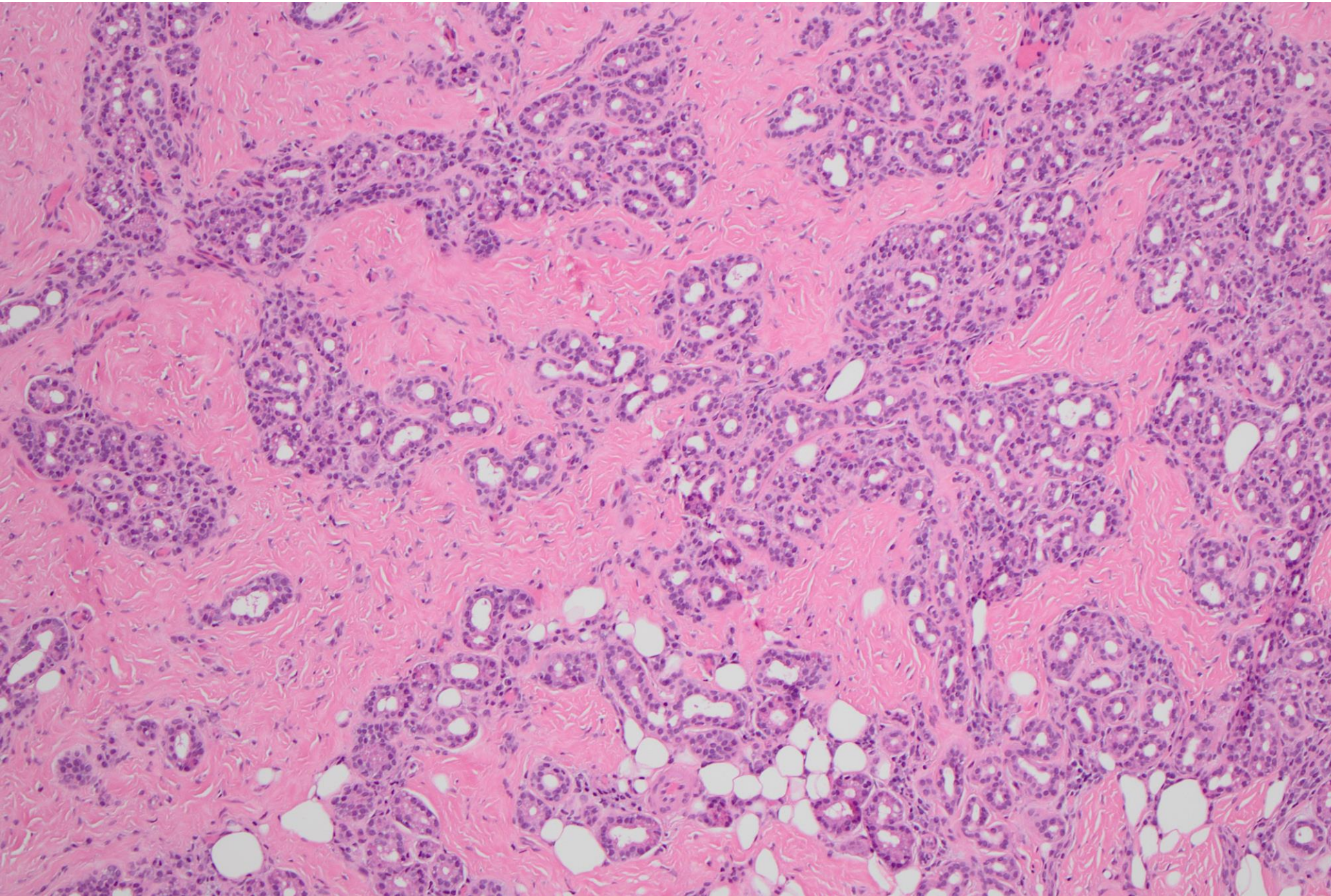
Sebaceous glands

Fibrous tissue

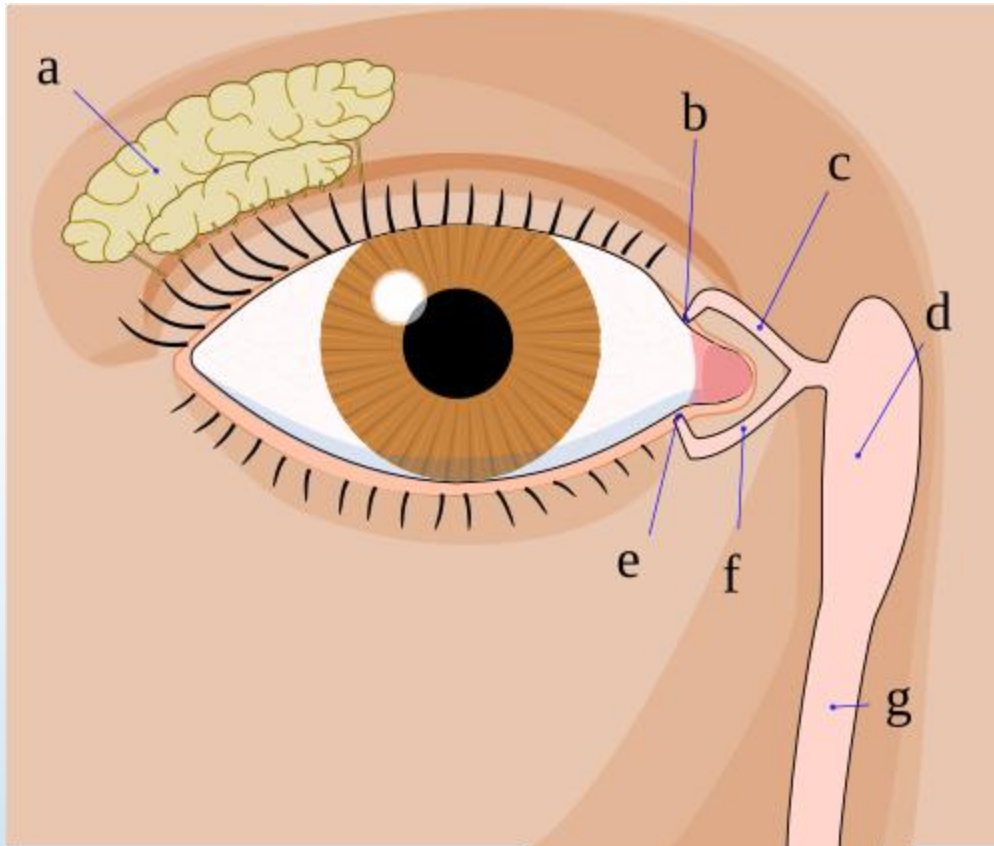
**Eyelid
posterior
lamella:
superior
aspect of
tarsus**



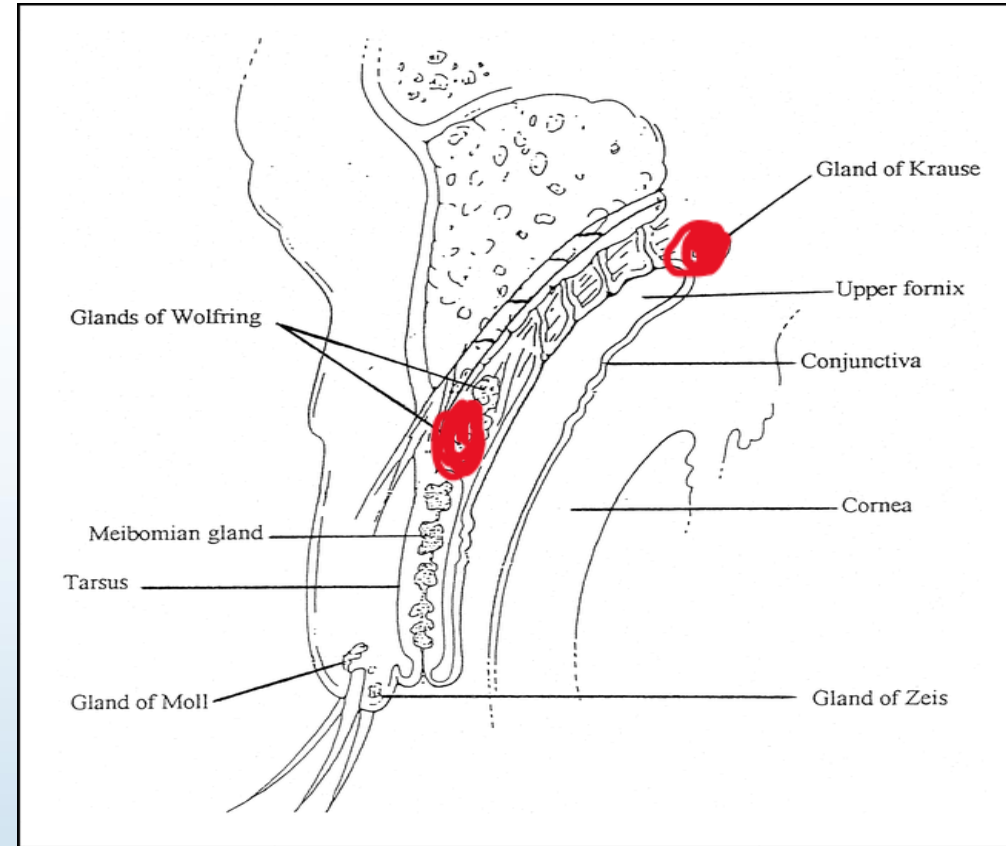
Fibrous tissue & lacrimal gland -> Accessory lacrimal glands of Wolfring



Lacrimal glands: Main (orbital and palpebral lobe), Krause and Wolfring

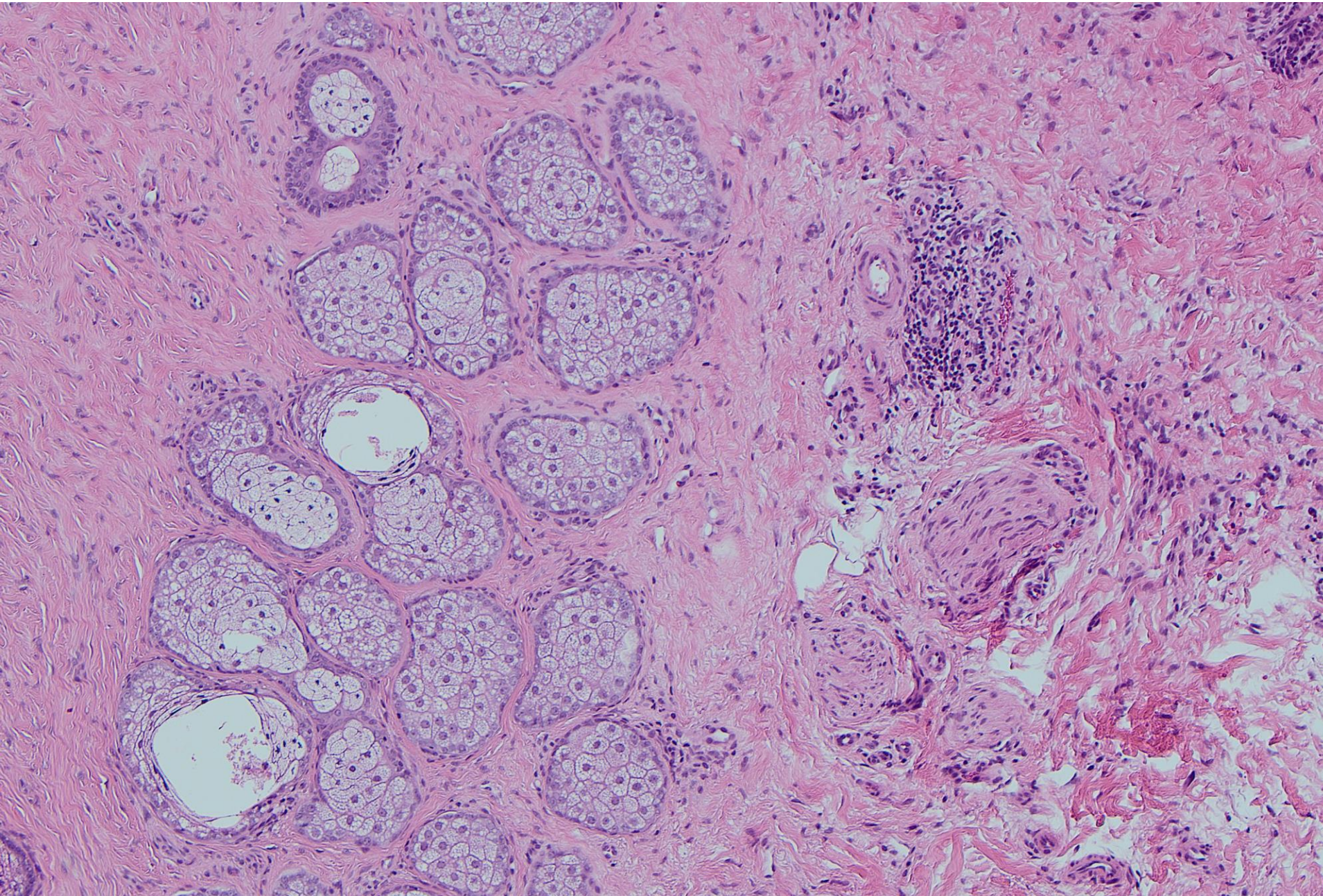


<https://en.wikipedia.org/wiki/Tears>

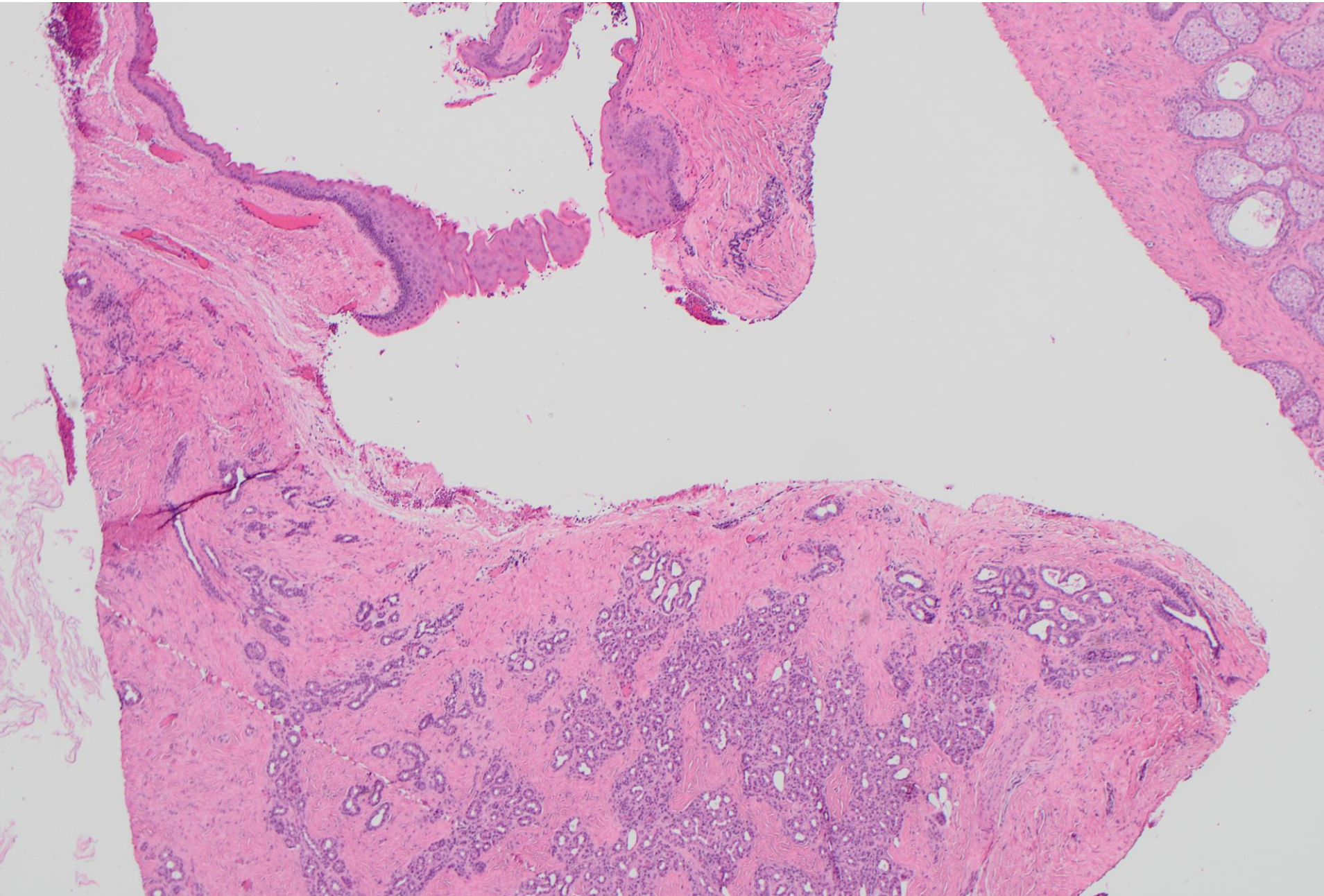


<https://www.ajnr.org/content/20/6/1140>

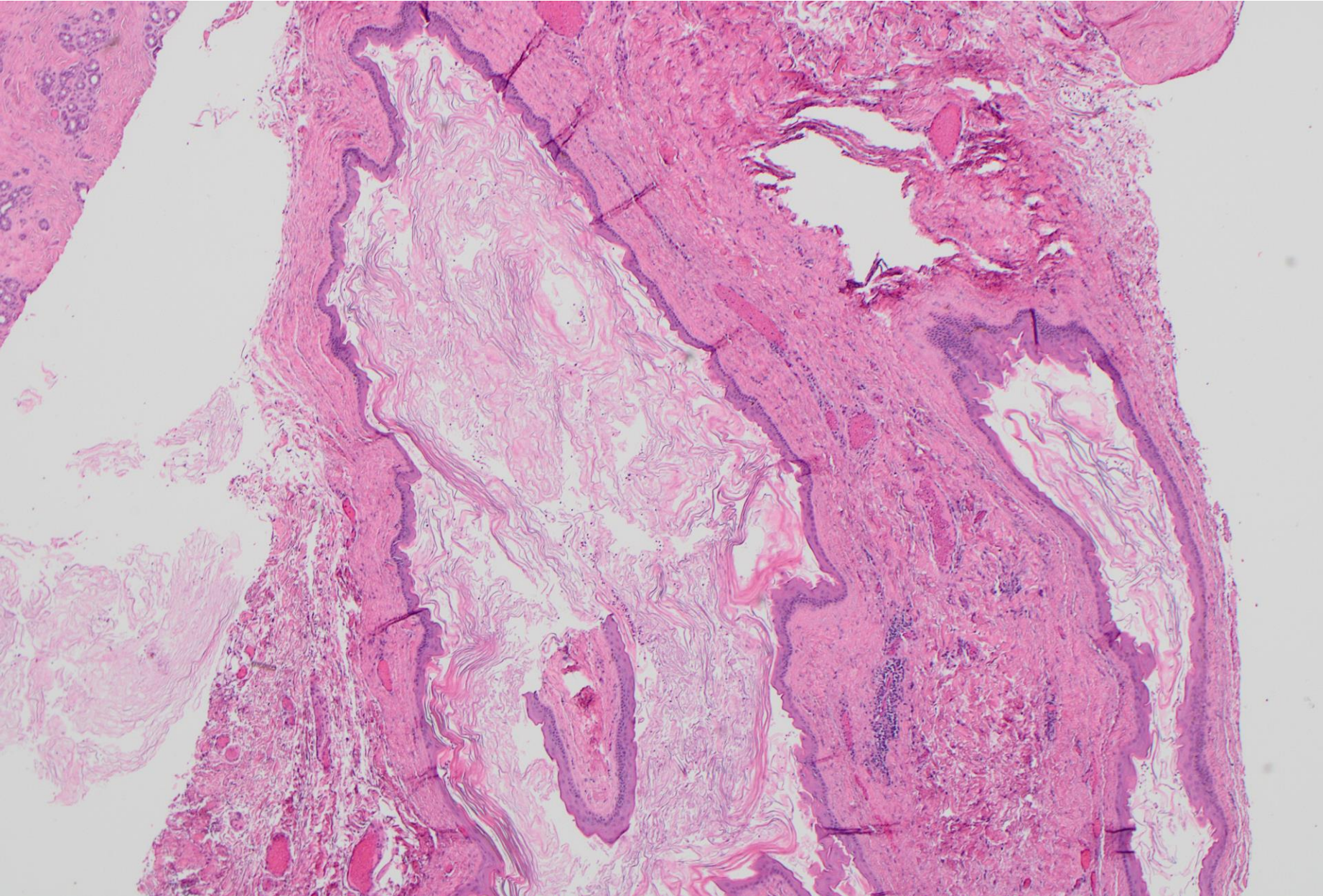
Sebaceous glands in fibrous tissue = Meibomian glands

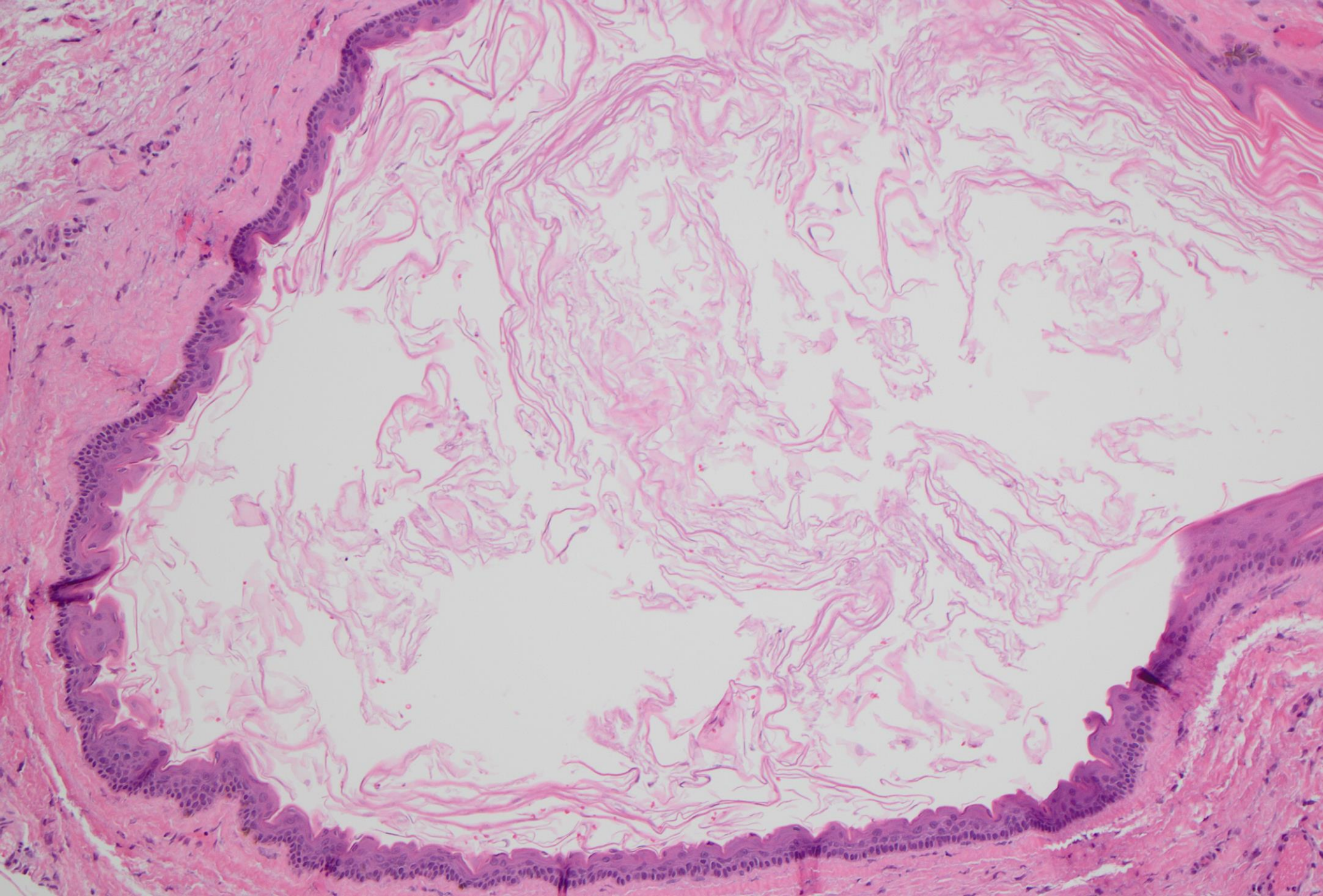


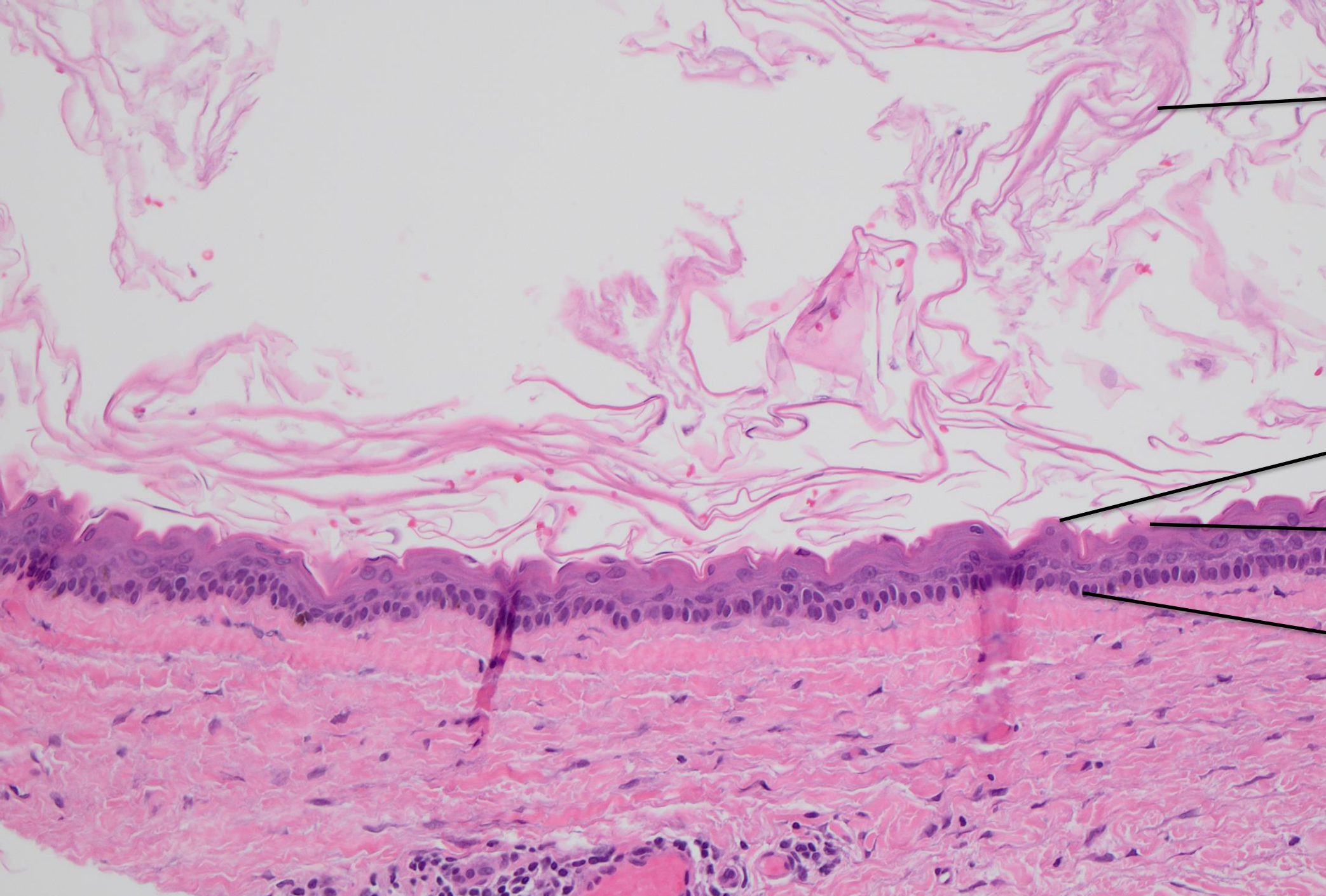
Cyst lining



Cyst lining








Long, stringy pink keratin

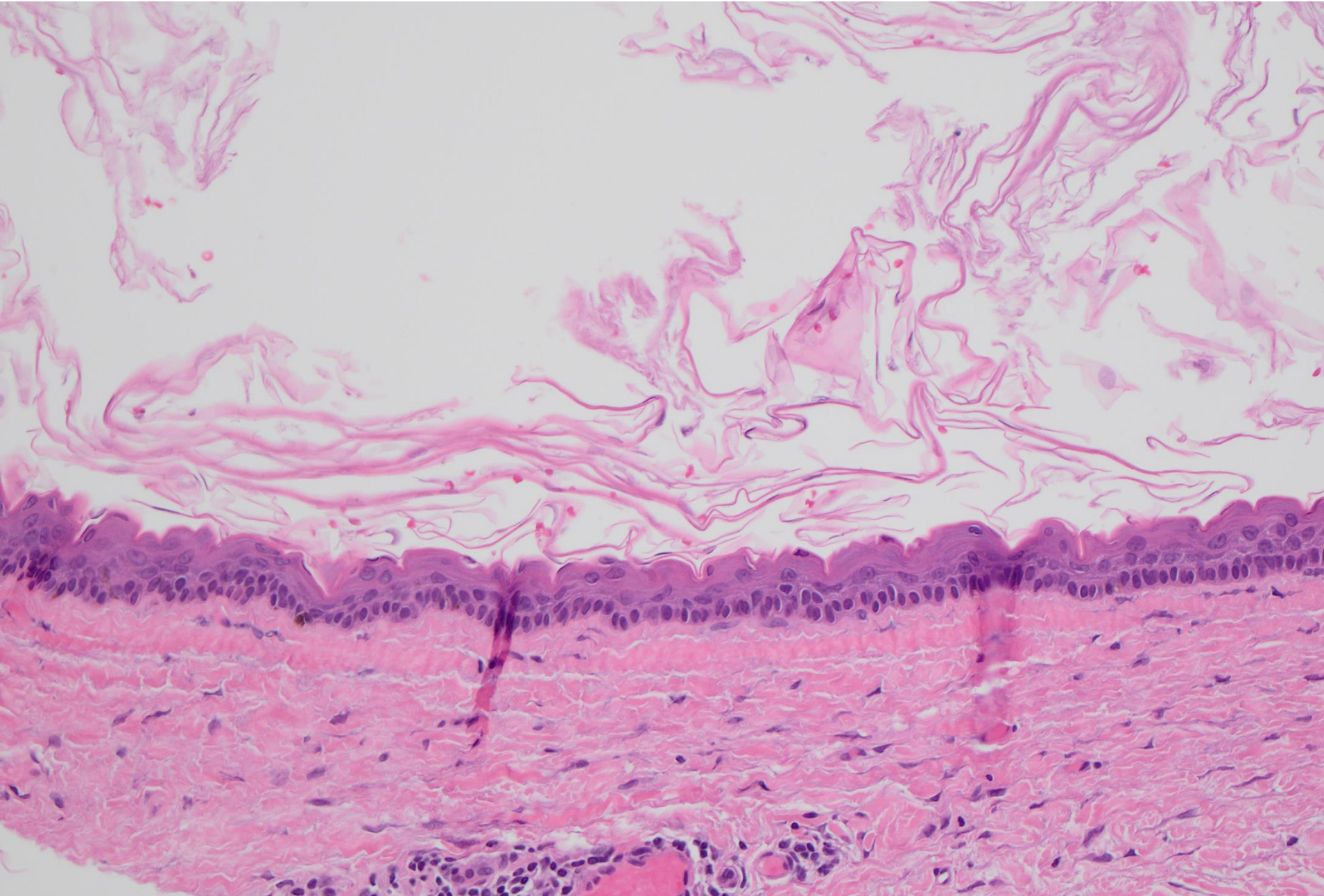
Corrugated surface

Lack of keratohyaline granules

Regimented basal layer

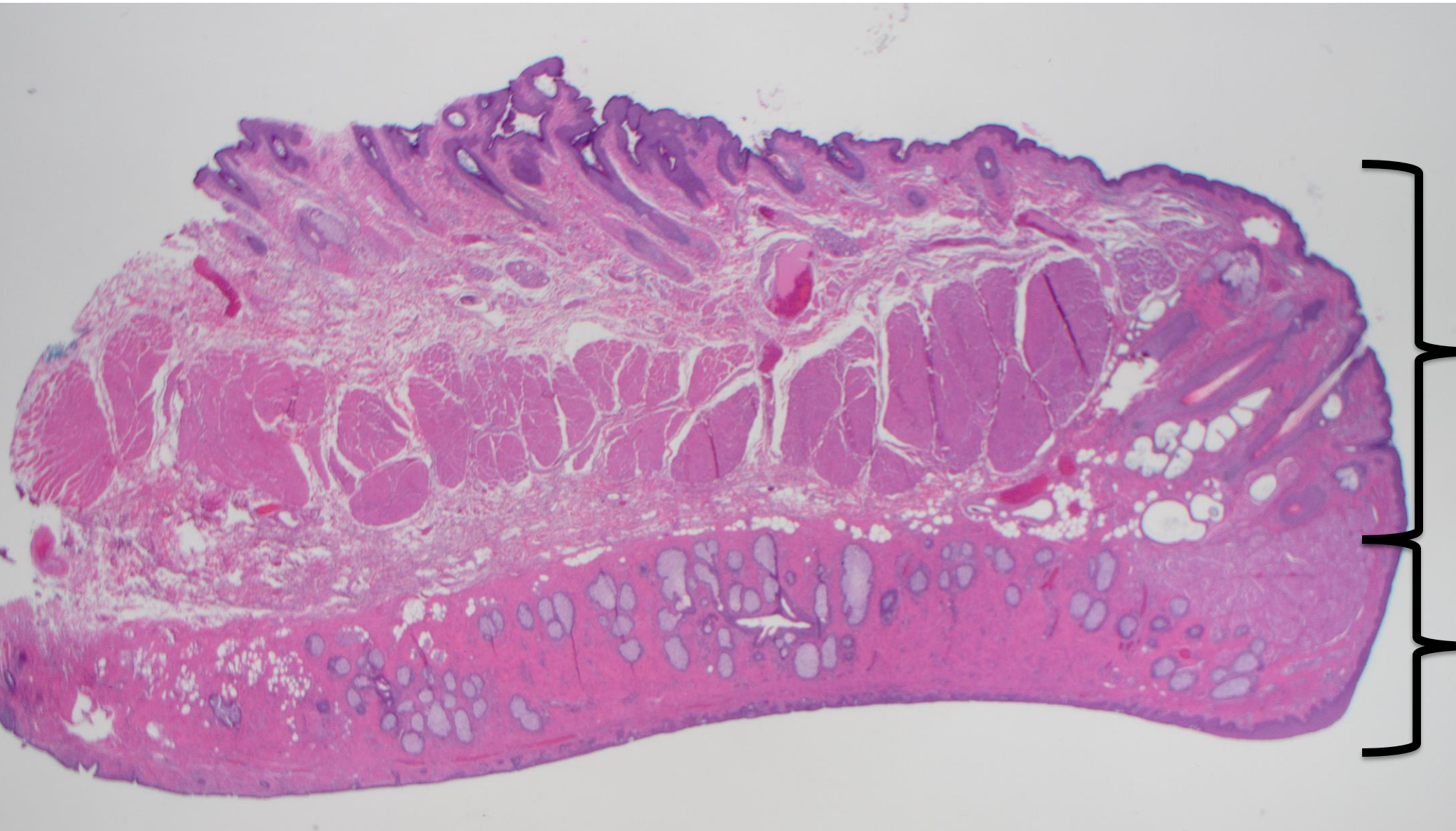


Intratarsal keratinous cyst



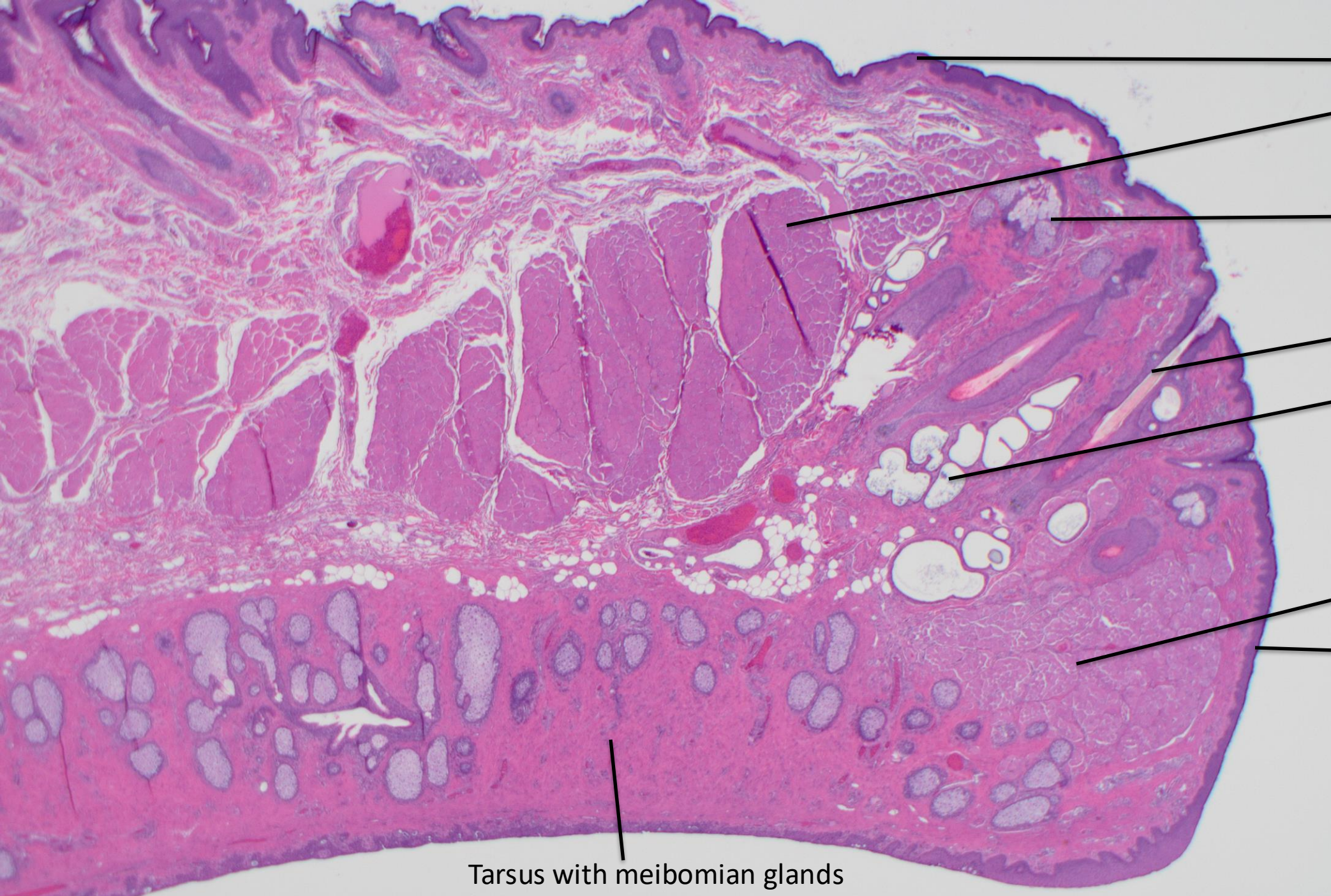
Making sense of the lesion: Normal Eyelid Histology






Anterior lamella:
Skin + orbicularis

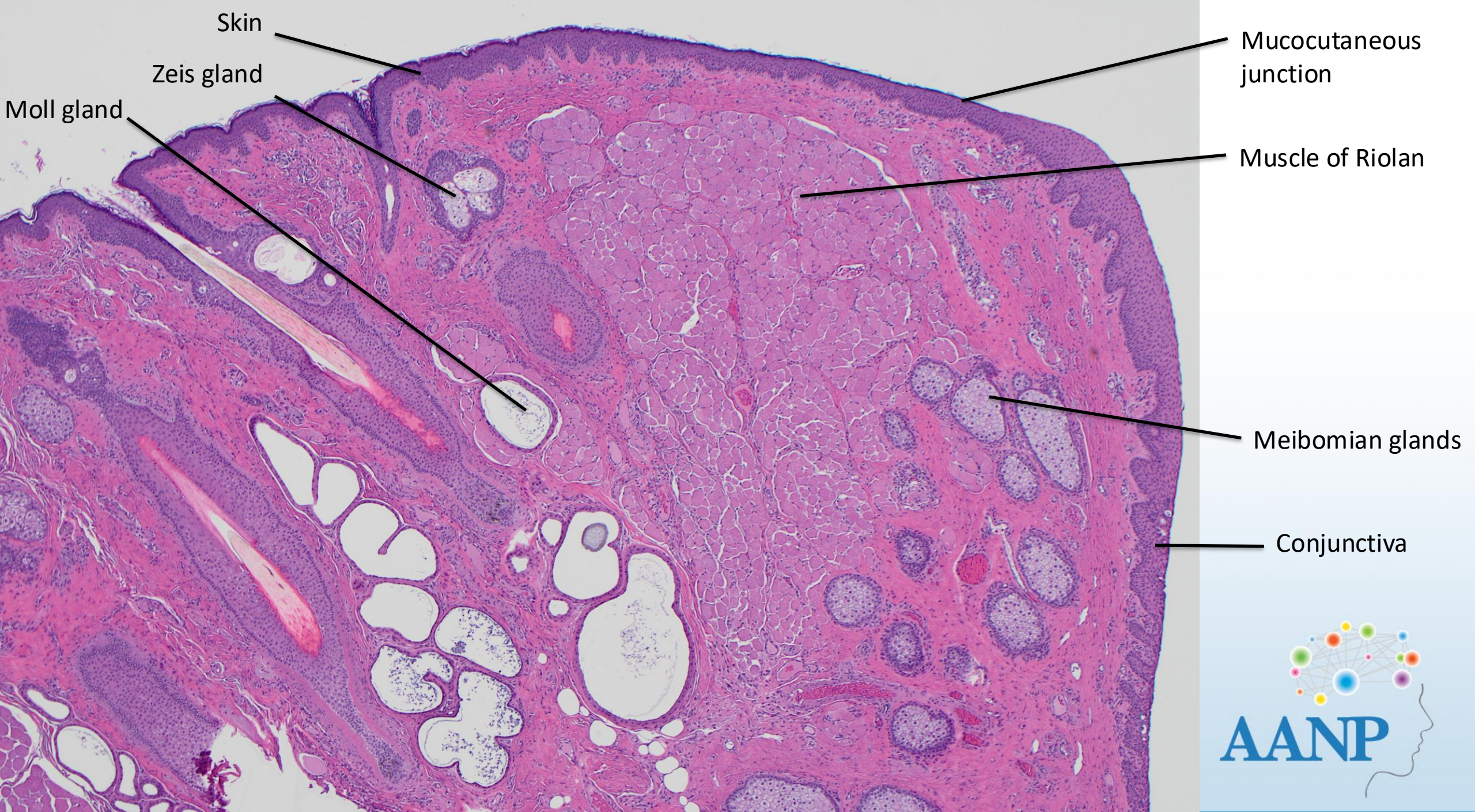
Posterior lamella:
Tarsus +
conjunctiva



- Skin
- Orbicularis oculi muscle
- Sebaceous glands at base of lashes "Glands of Zeis"
- Lashes
- Apocrine glands "Glands of Moll"
- Muscle of Riolan (orbicularis) = "gray line"
- Mucocutaneous junction

Tarsus with meibomian glands





Skin

Zeis gland

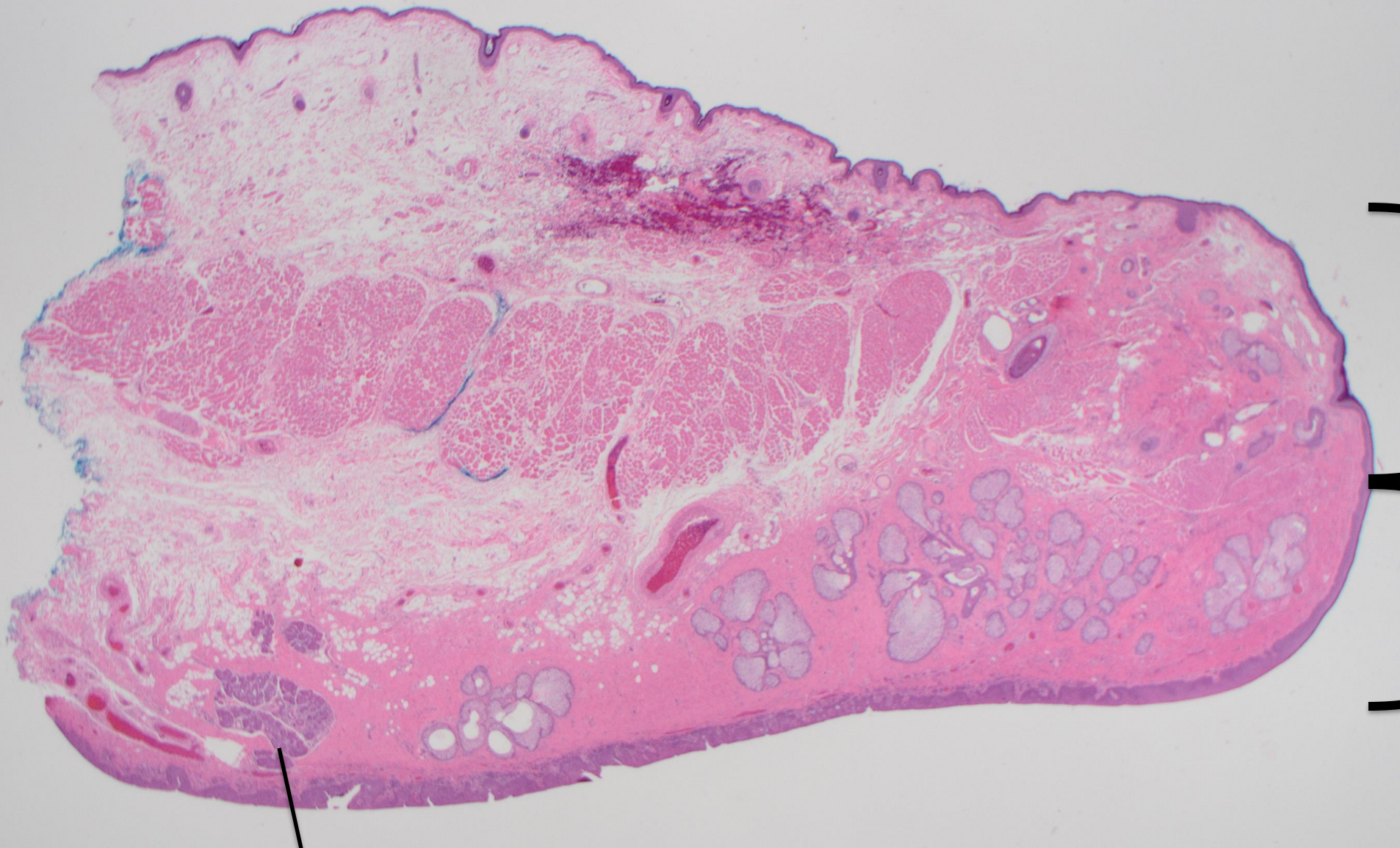
Moll gland

Mucocutaneous junction

Muscle of Riolan

Meibomian glands

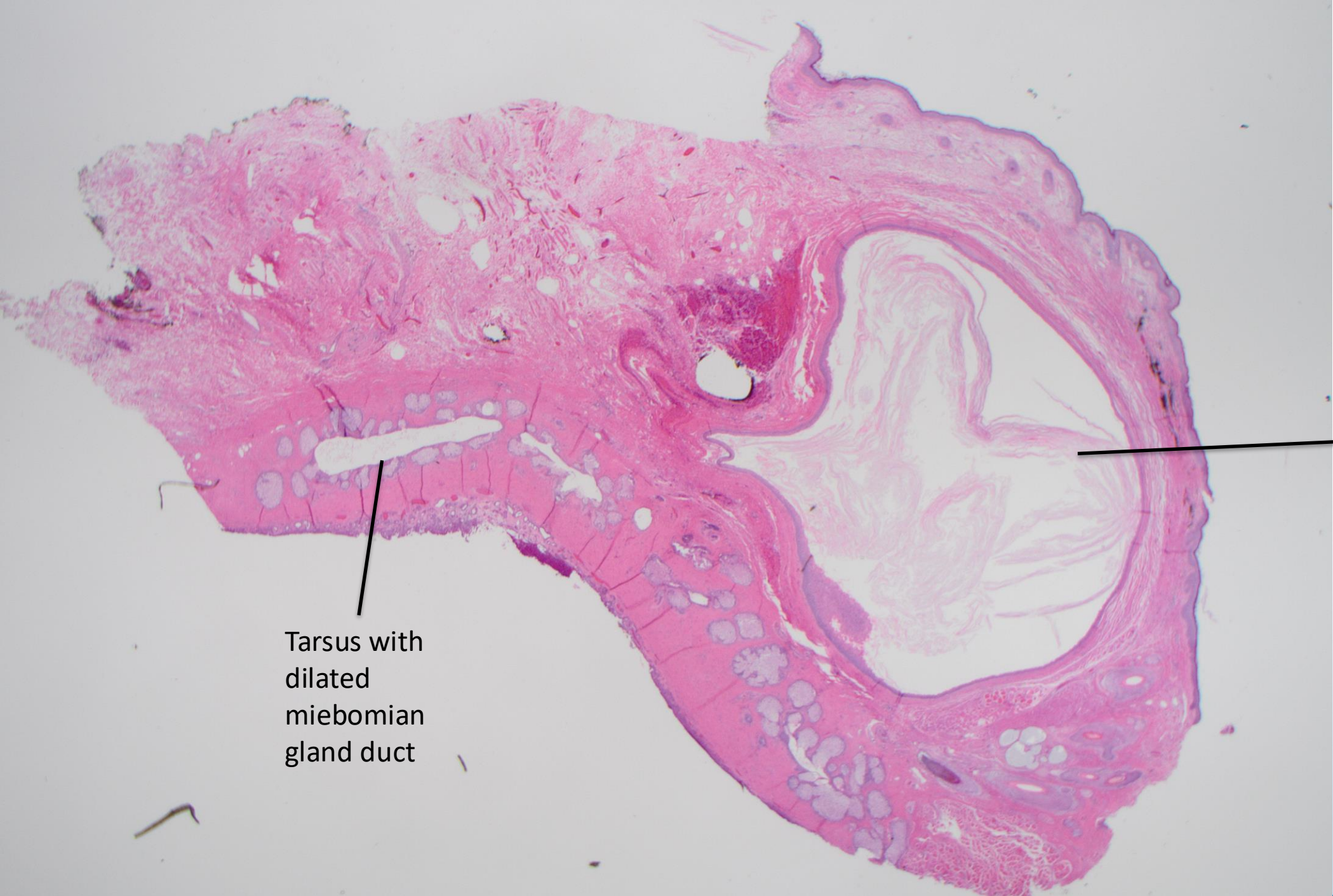Conjunctiva



Anterior lamella:
Skin + orbicularis

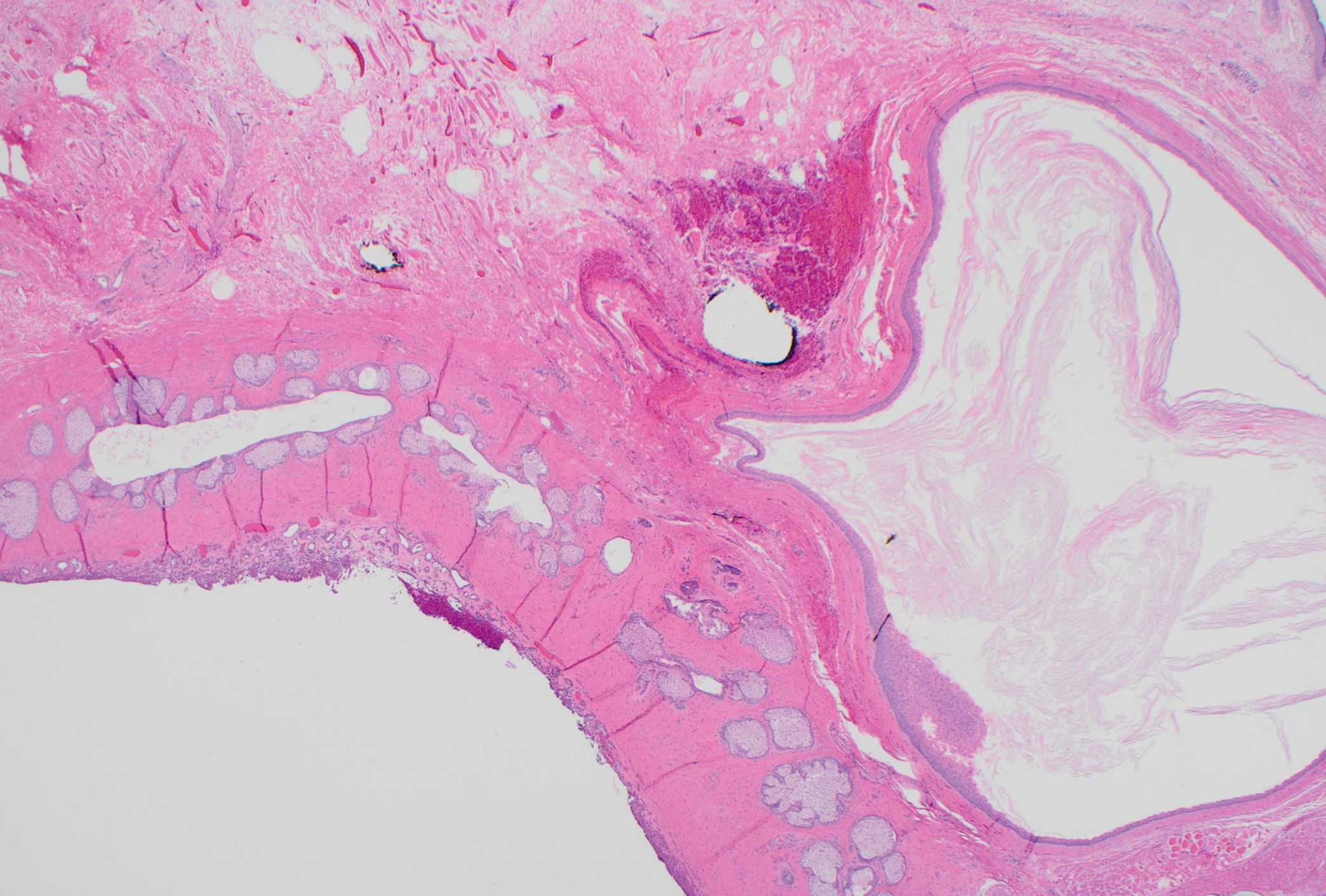
Posterior lamella:
Tarsus +
conjunctiva

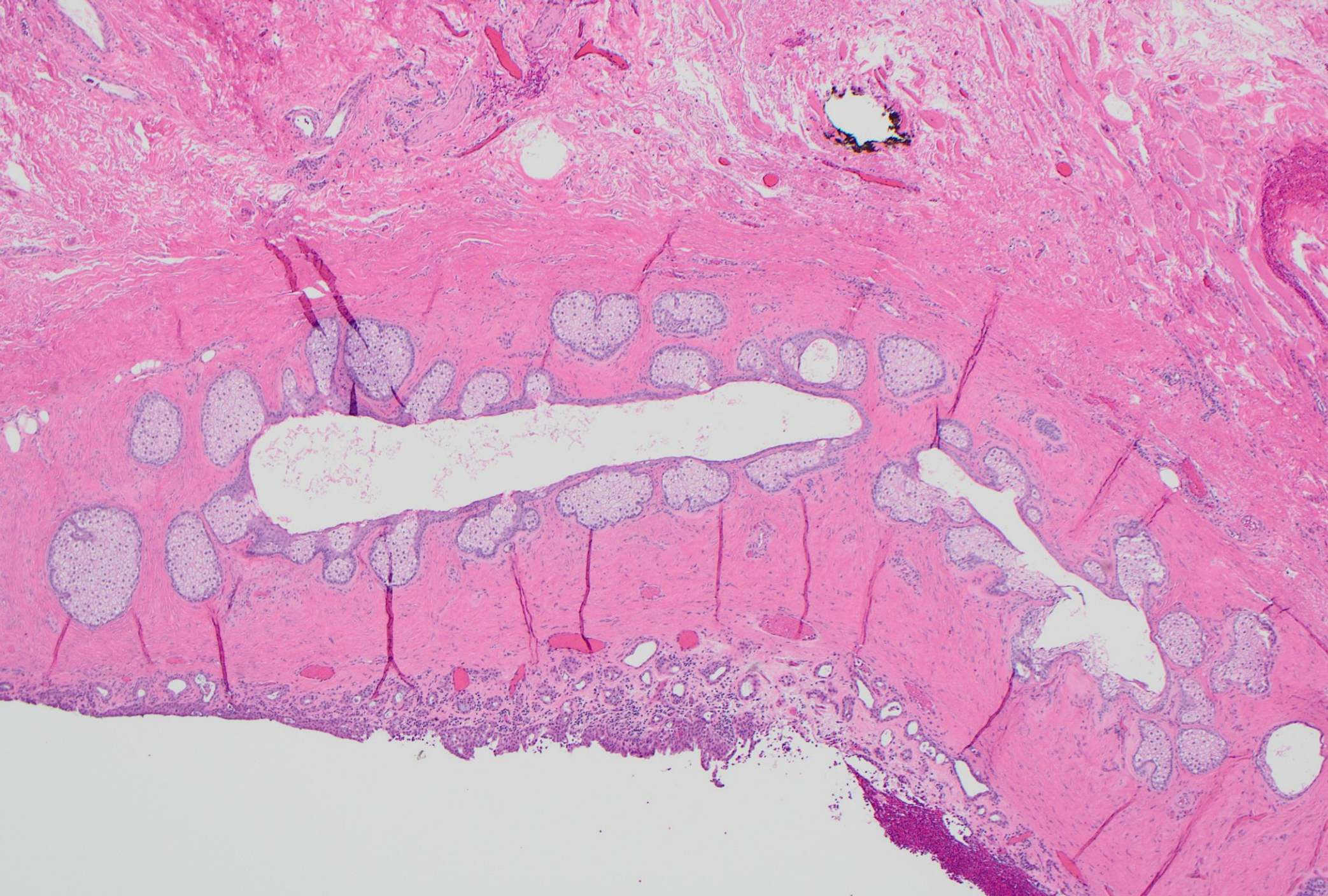
Accessory lacrimal gland of Wolfring



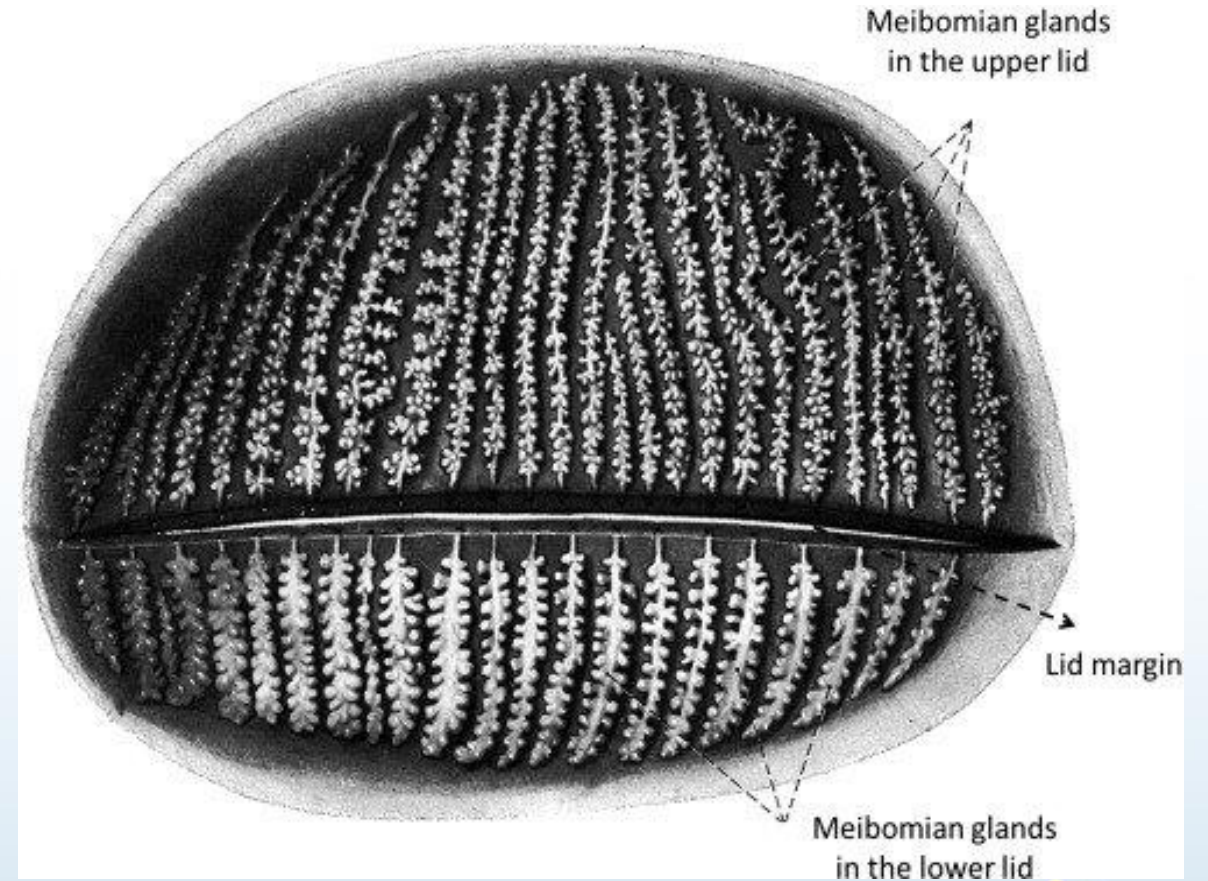
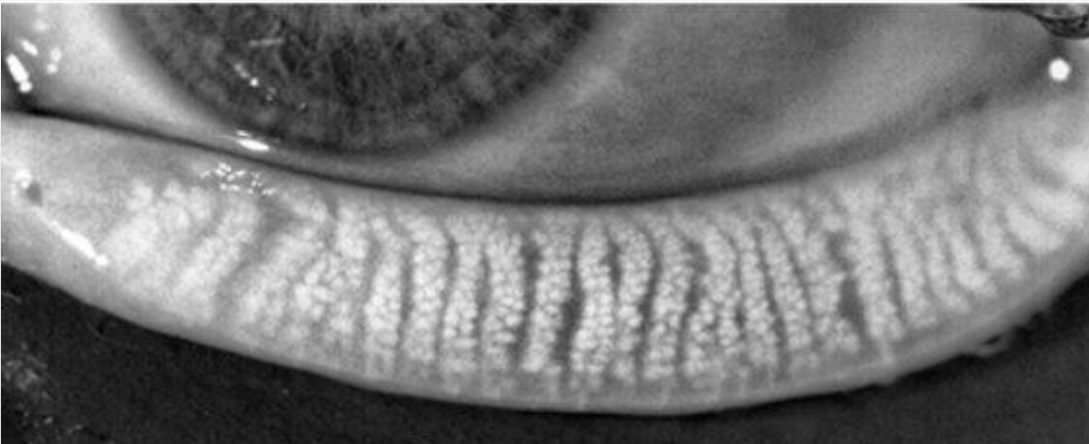
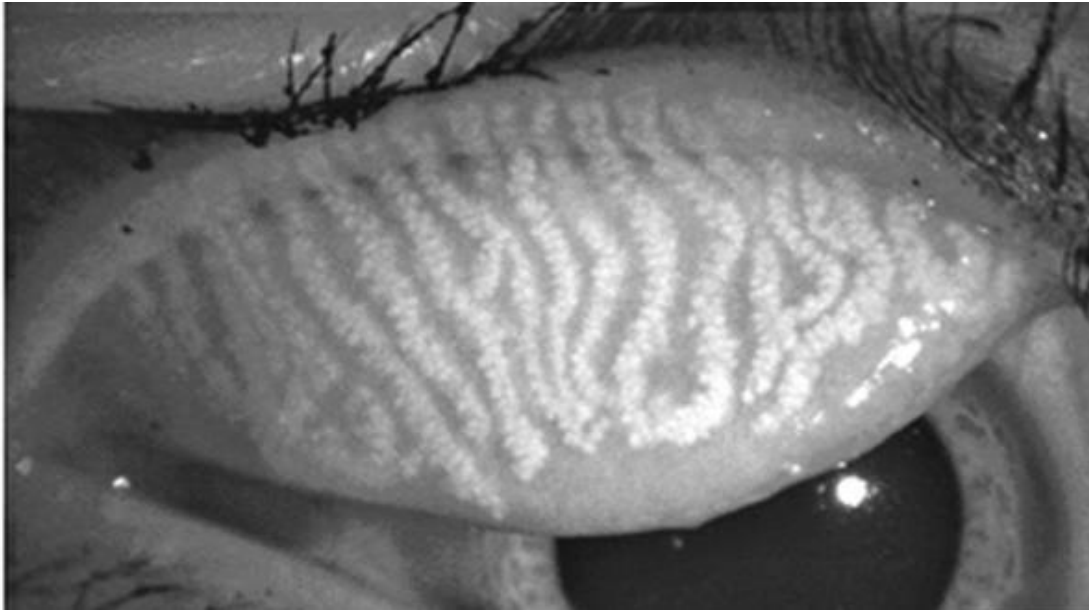
Cyst

Tarsus with
dilated
meibomian
gland duct






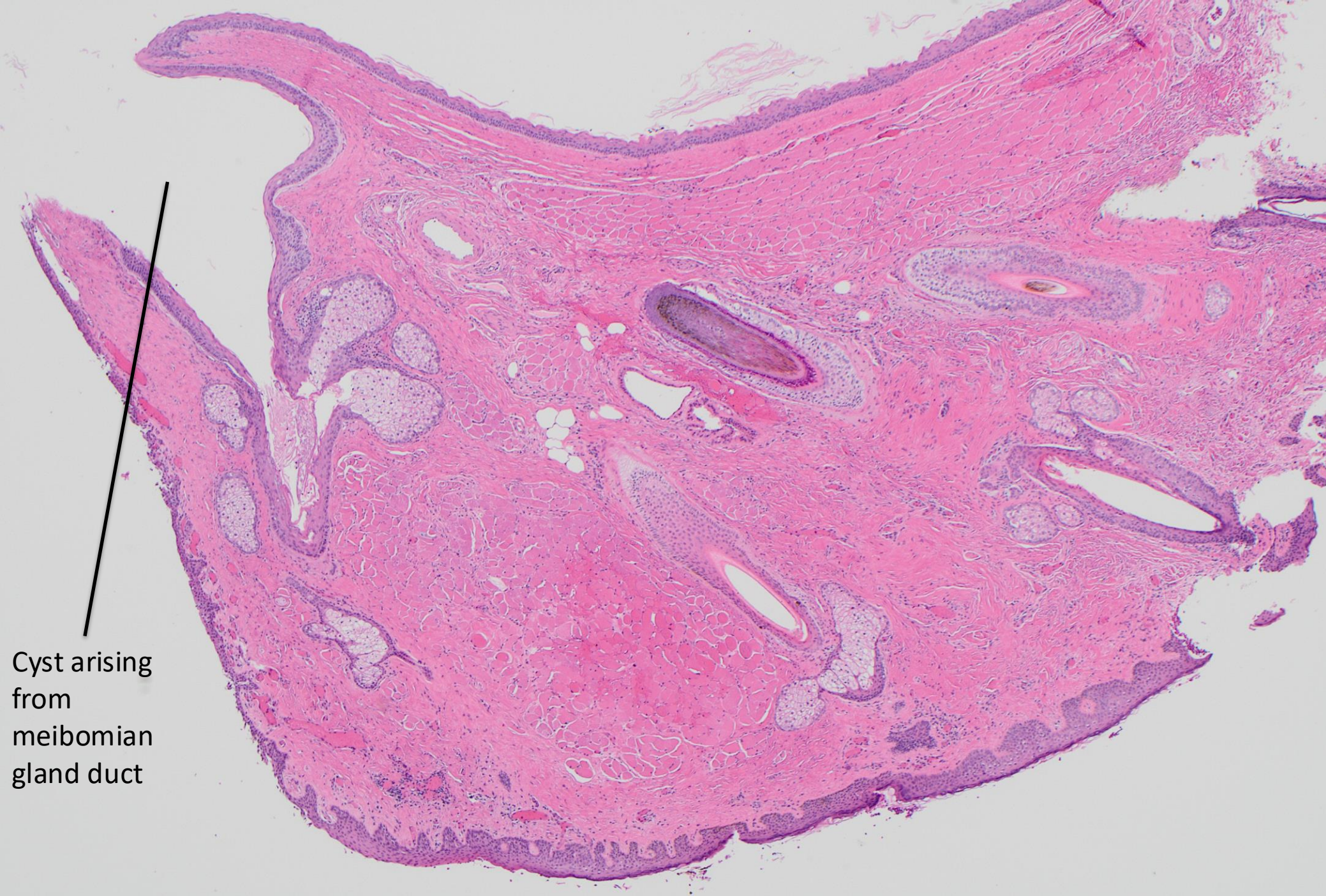
Meibomian glands



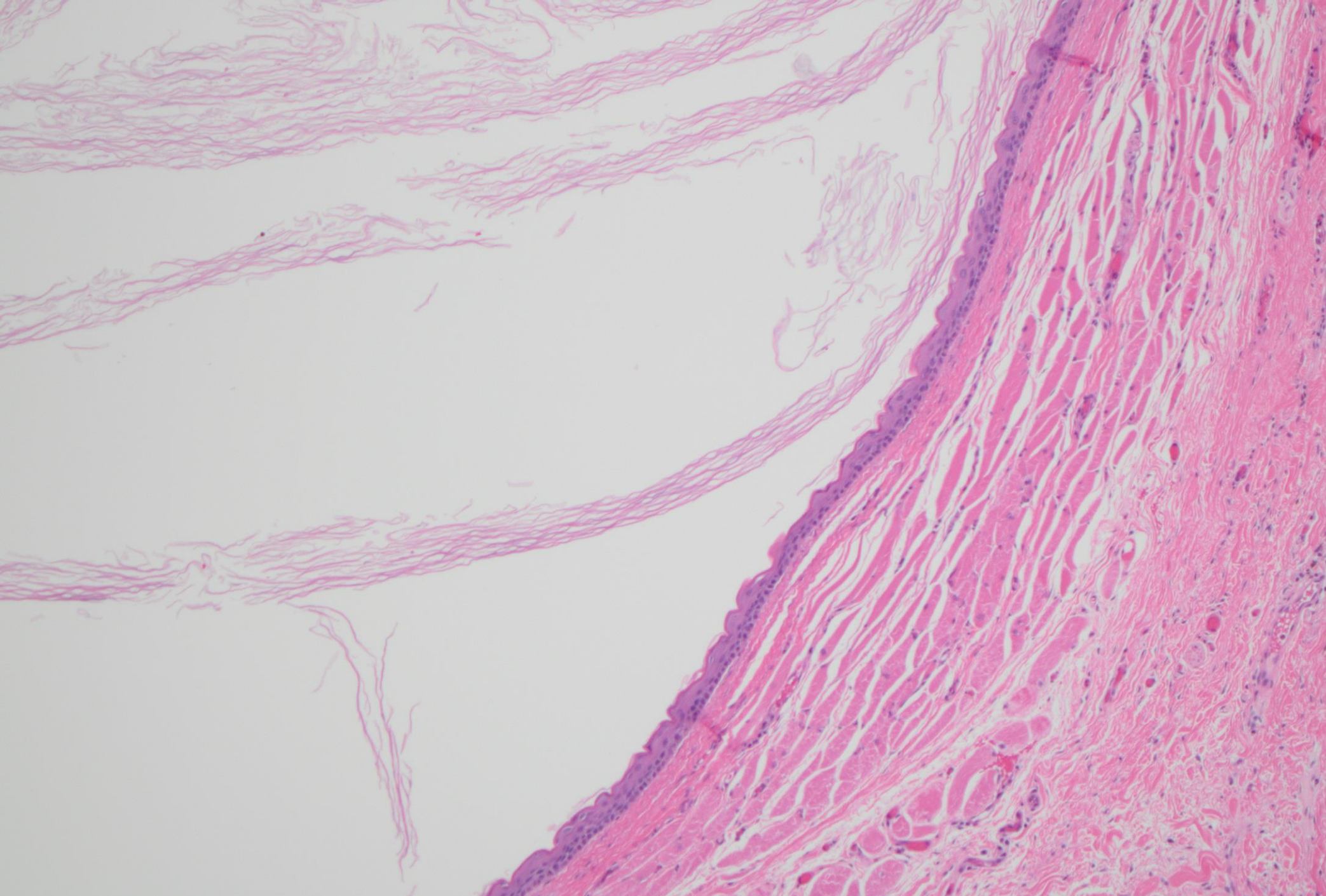
<https://www.reviewofoptometry.com/article/improve-your-understanding-of-meibomian-gland-function-and-dysfunction>

<https://glaucomatoday.com/articles/2021-nov-dec/treating-dry-eye-associated-with-meibomian-gland-dysfunction>

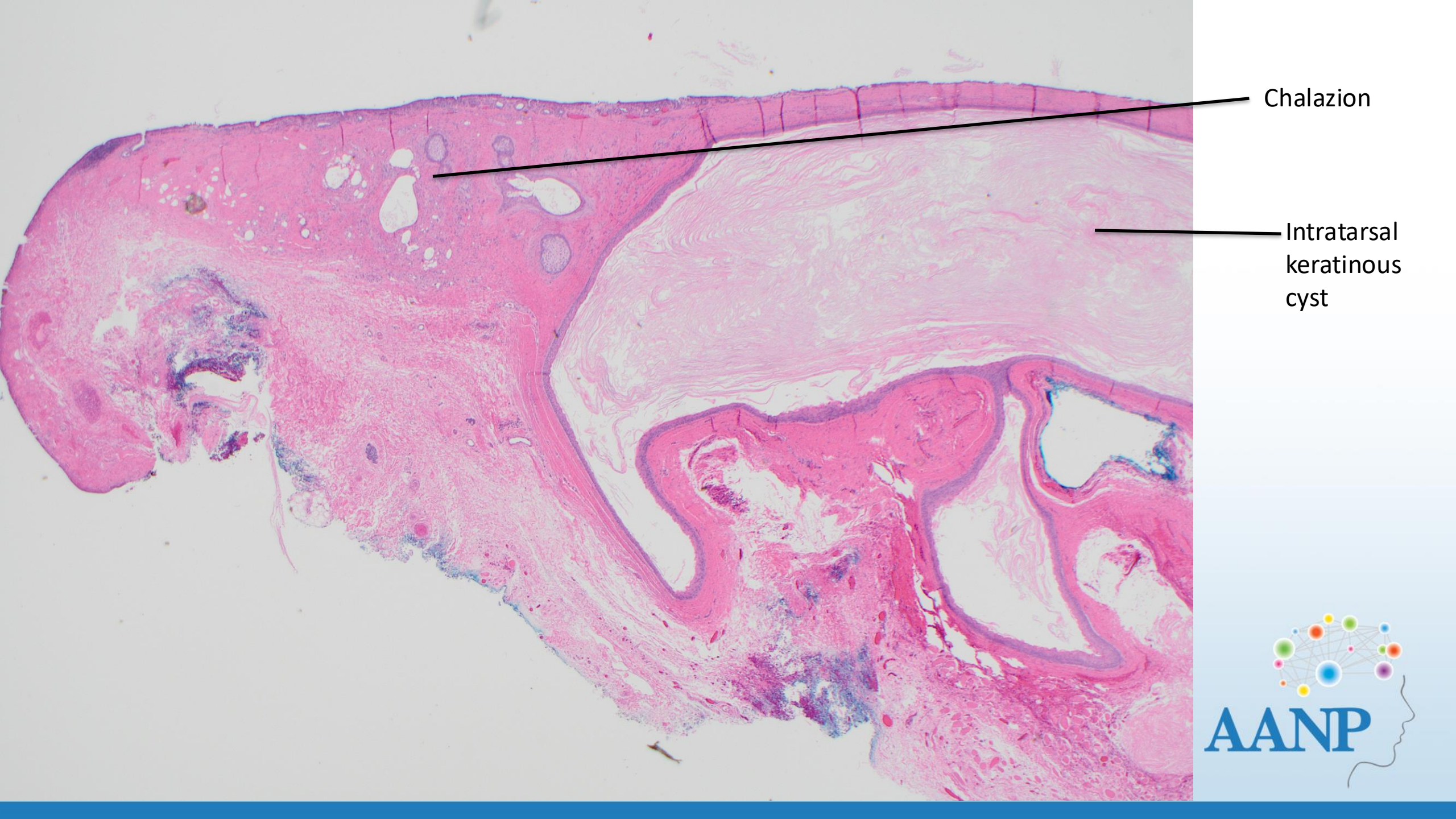



Cyst arising
from
meibomian
gland duct

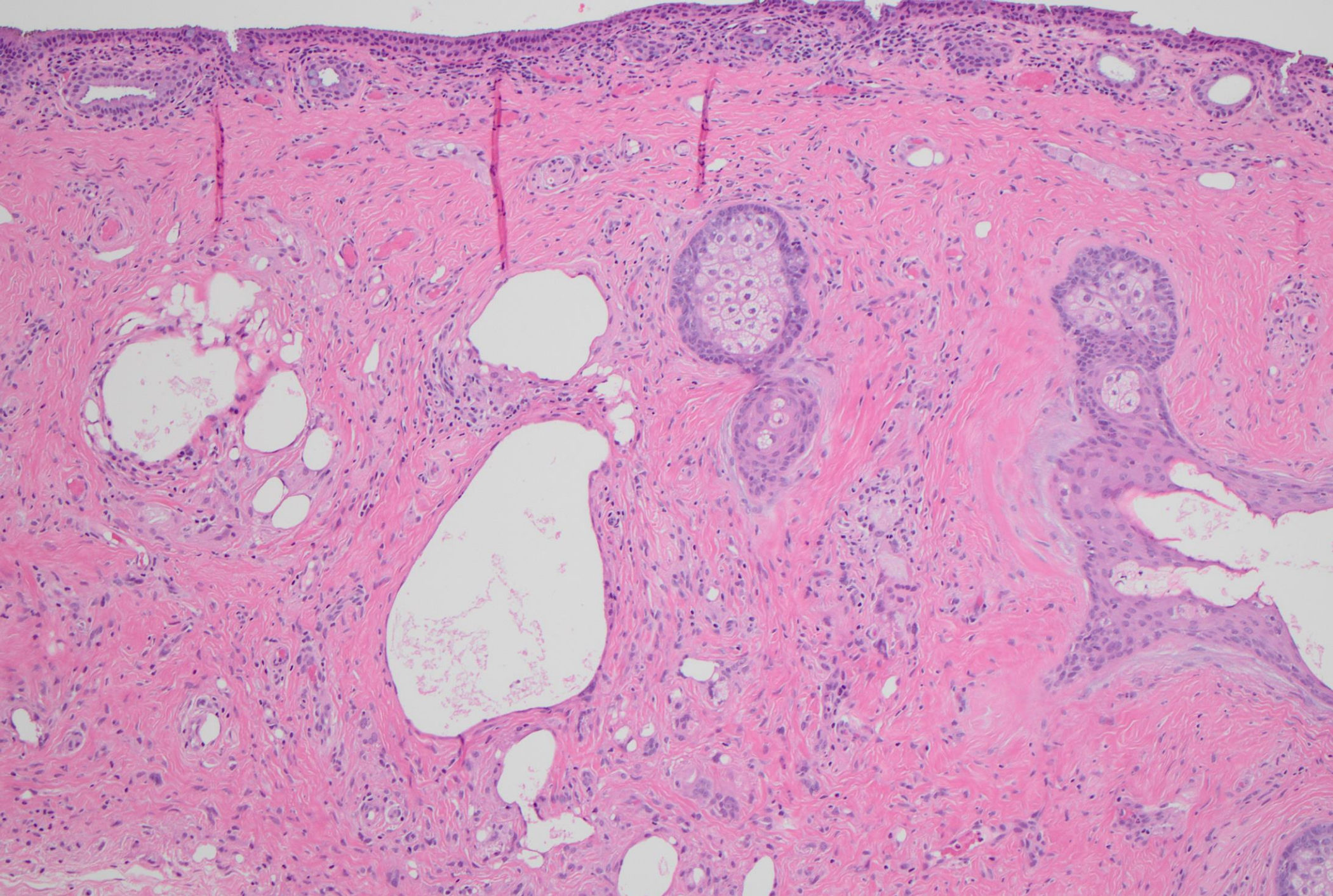


Intratarsal keratinous cyst

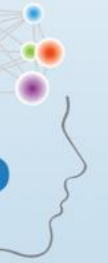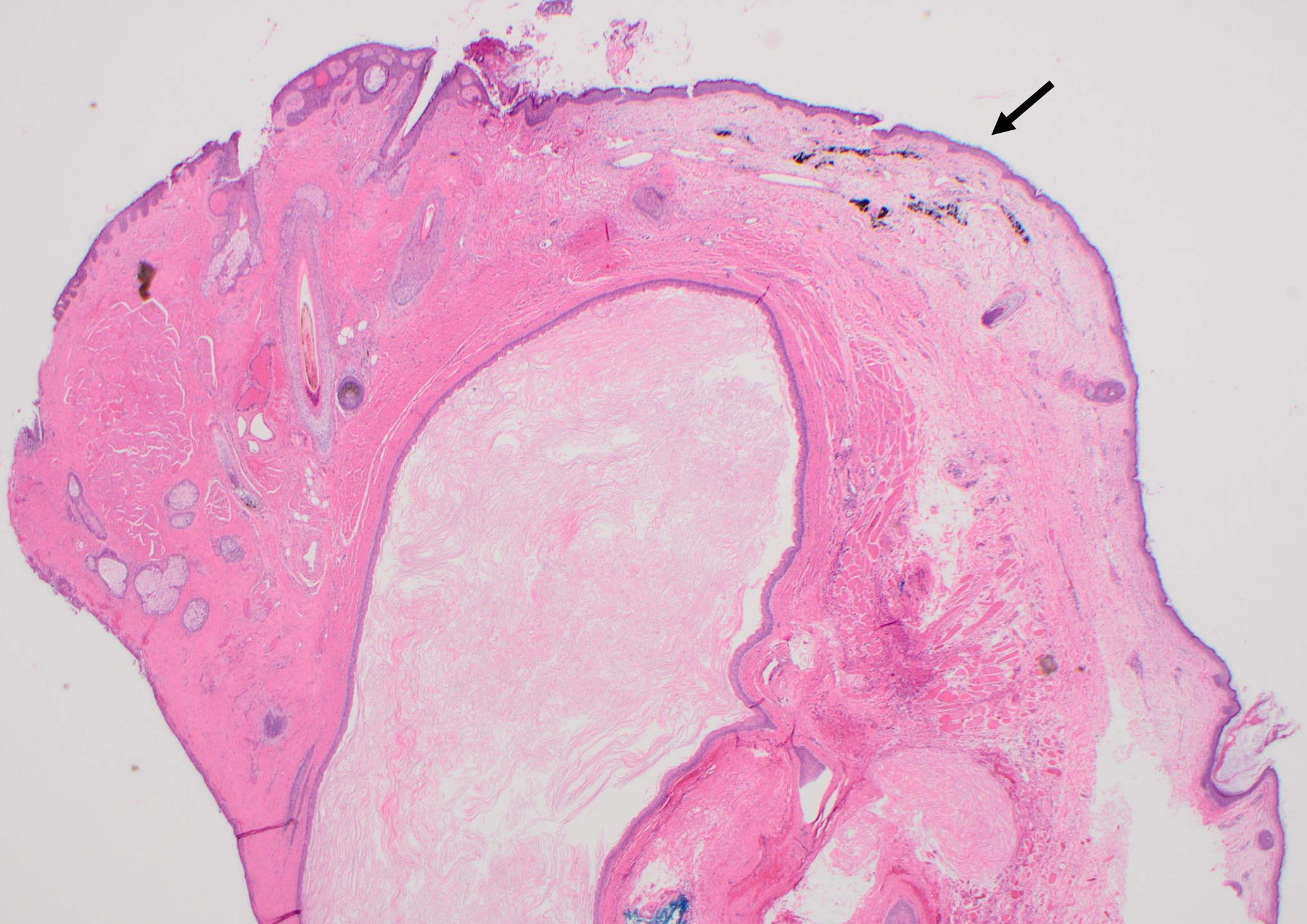


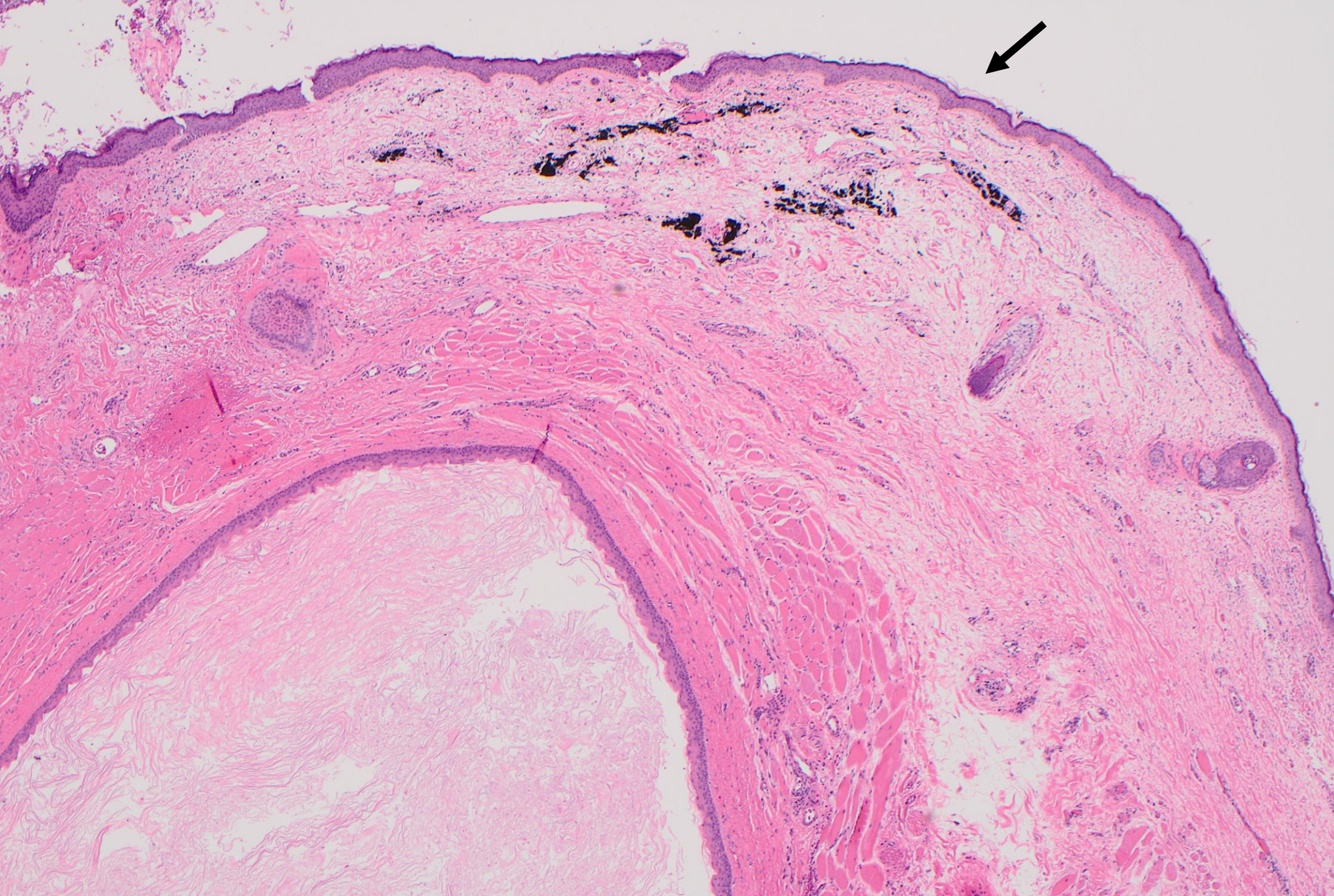
Chalazion

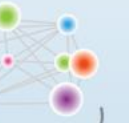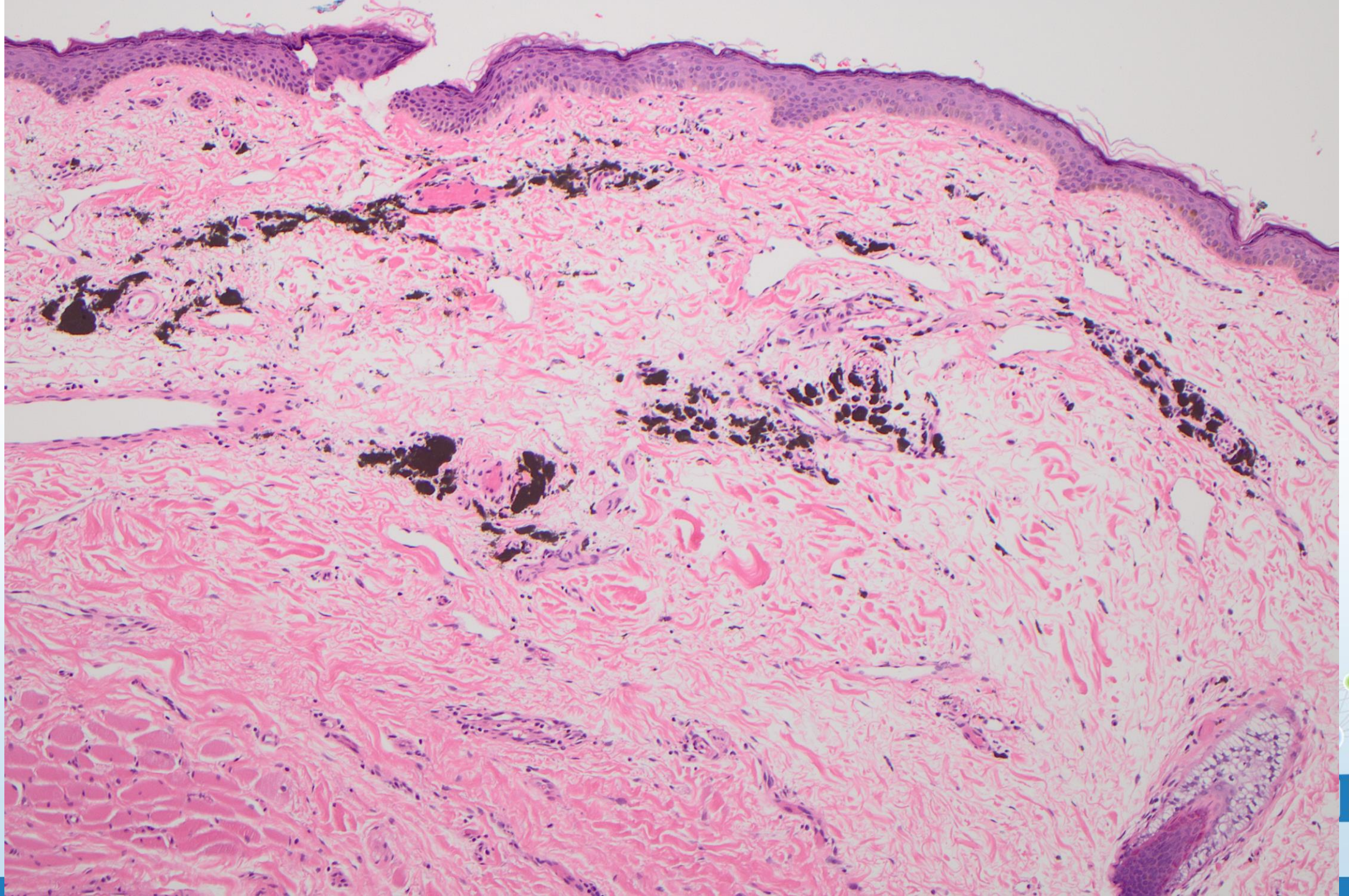
Intratarsal
keratinous
cyst



**Small
chalazion**






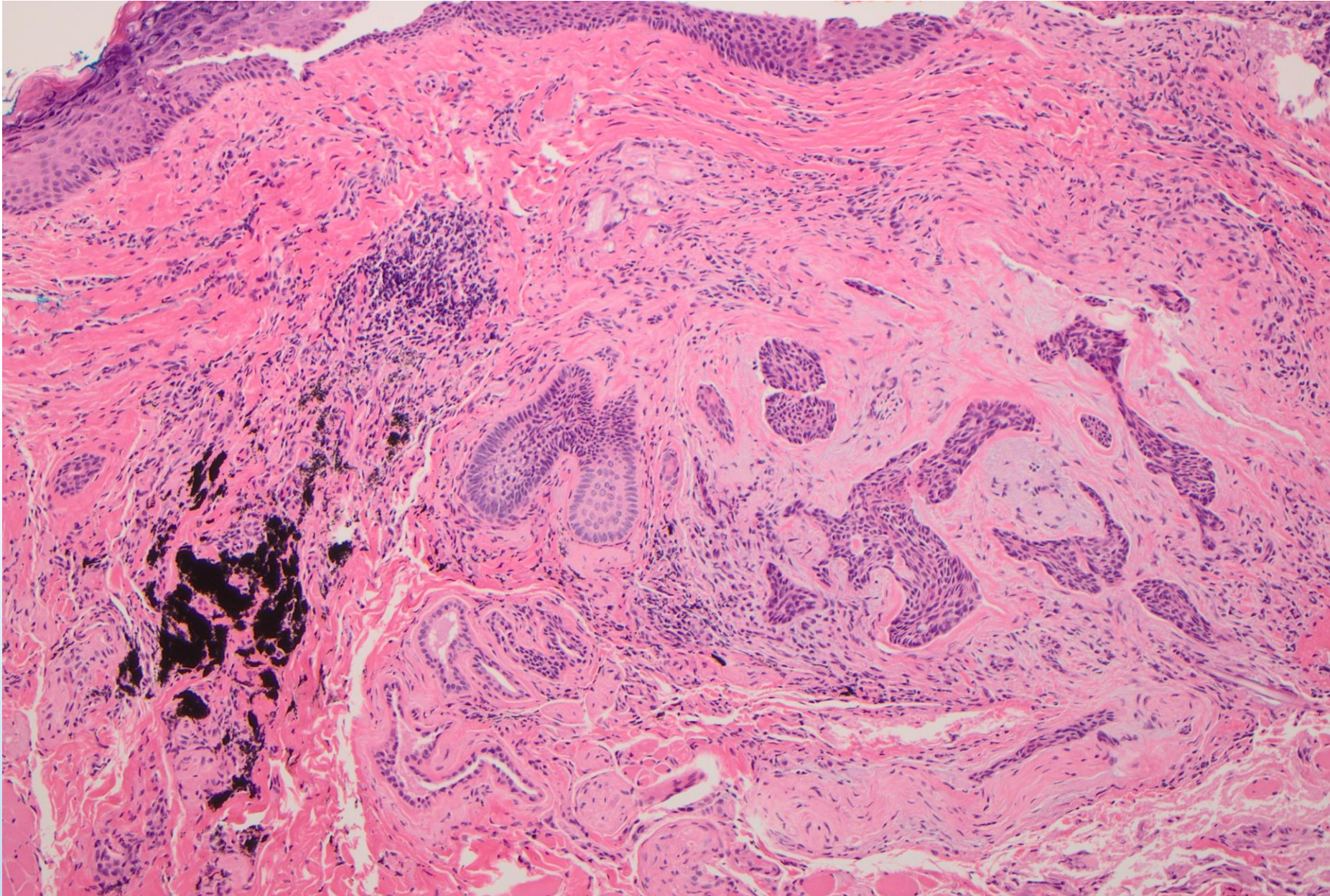


P

Incidental Tattoo Eyeliner



Basal cell carcinoma with adjacent eyeliner tattoo

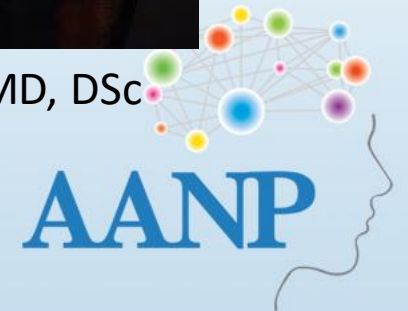


Intratarsal keratinous cyst -- Relevance

- Gorlin Syndrome (Nevoid basal cell carcinoma syndrome)
- Ensure entire cyst has been excised
- Clinical differential diagnosis

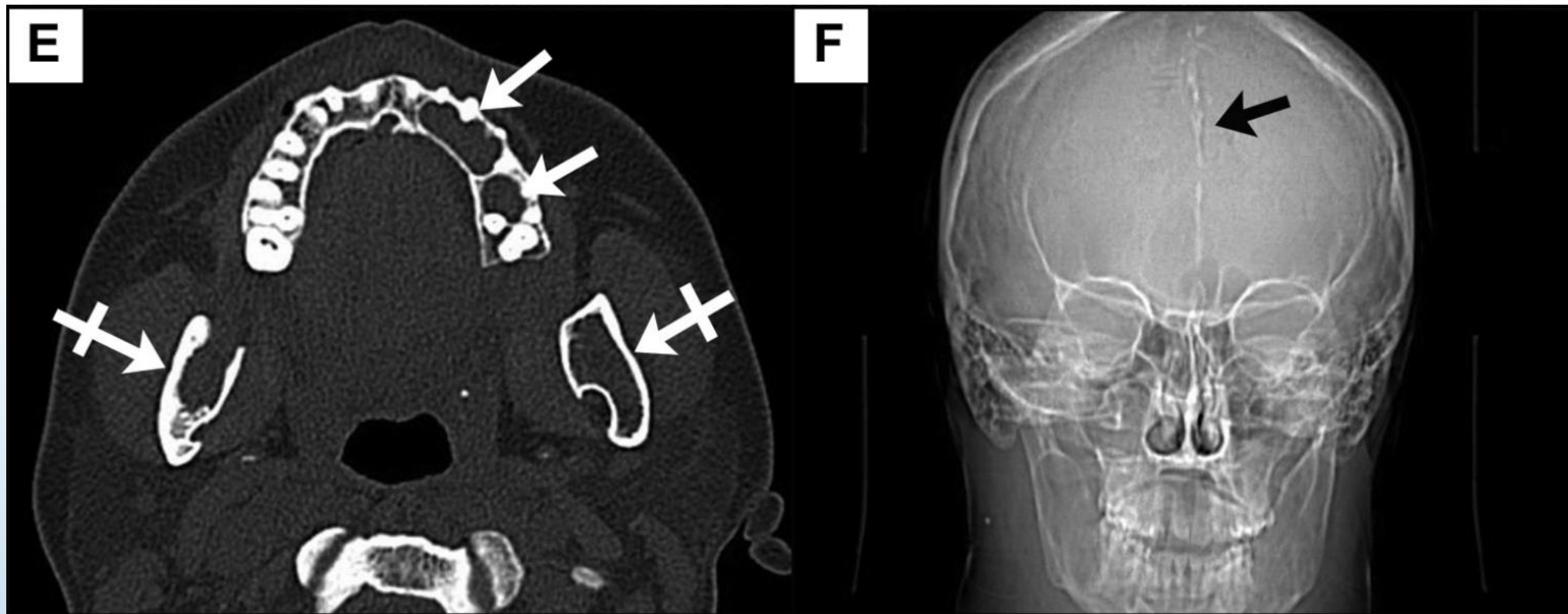


Frederick A. Jakobiec, MD, DSc
"King of cysts"



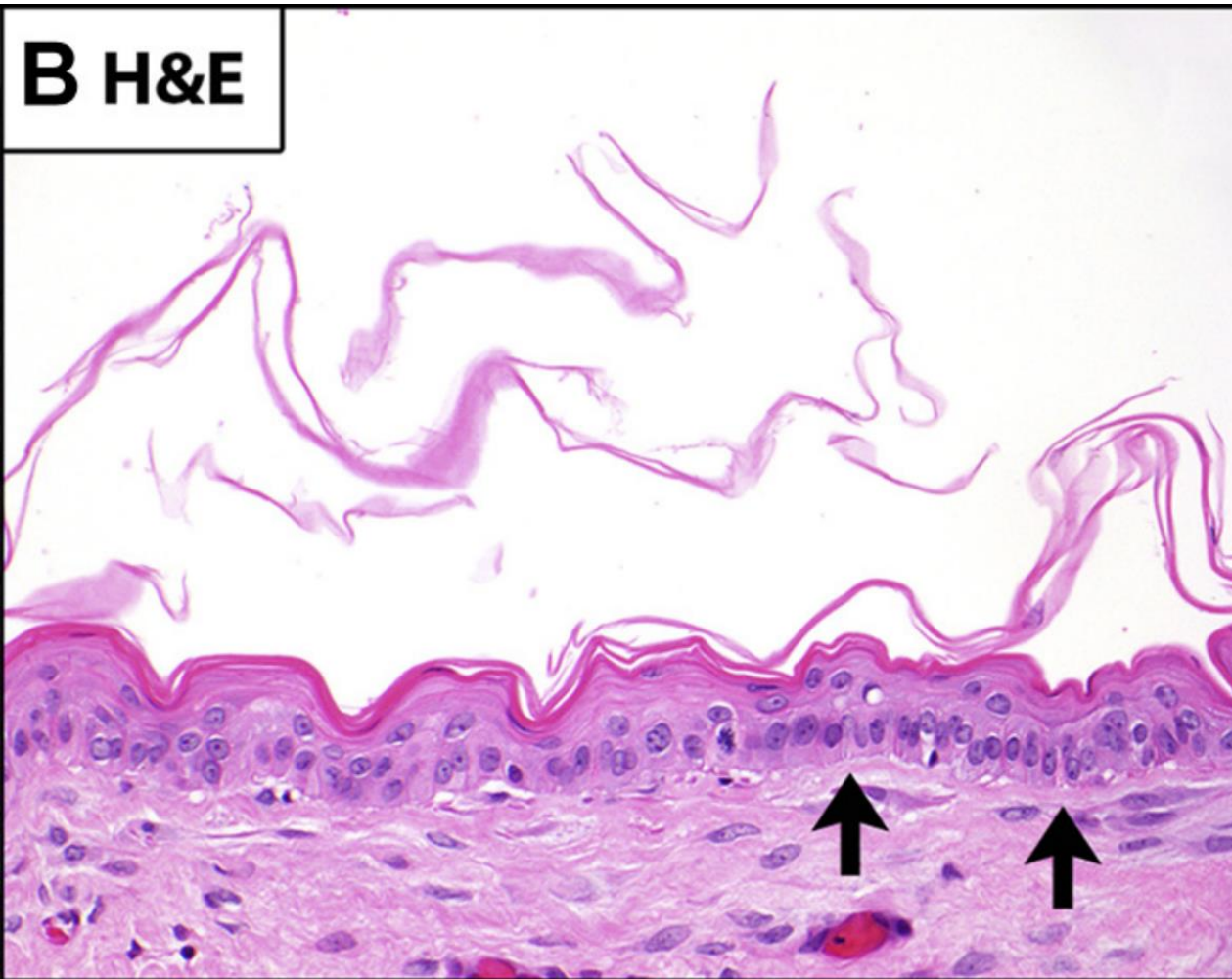Gorlin Syndrome (Nevoid basal cell carcinoma syndrome)

- Autosomal dominant
- Mutation in PTCH1 gene
- Findings: **basal cell carcinoma** at a younger age and numerous basal cells, jaw cysts (odontogenic keratocysts), calcified falx cerebri, palmar and plantar pits, frontal bossing, intratarsal keratinous cysts , bifid ribs

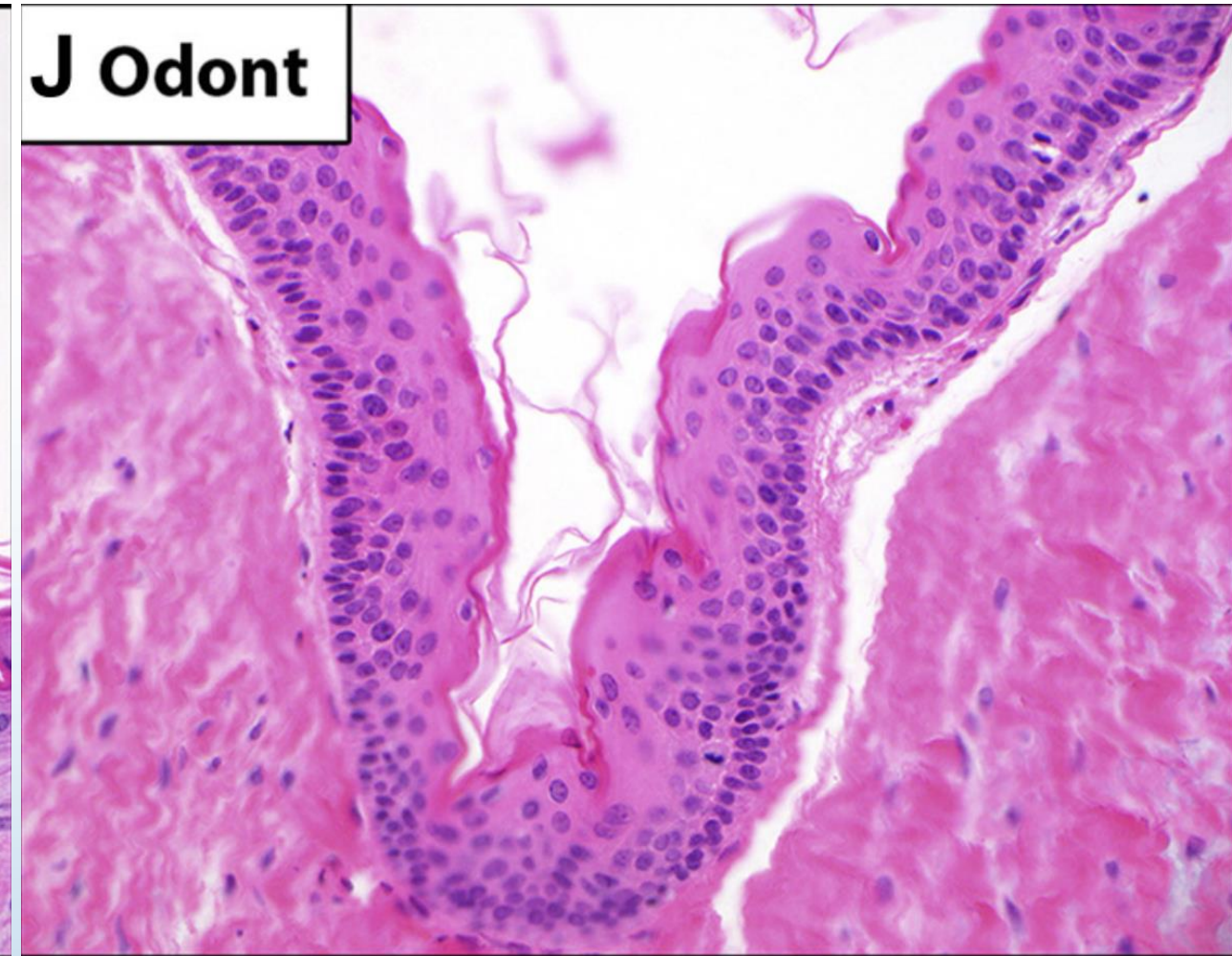


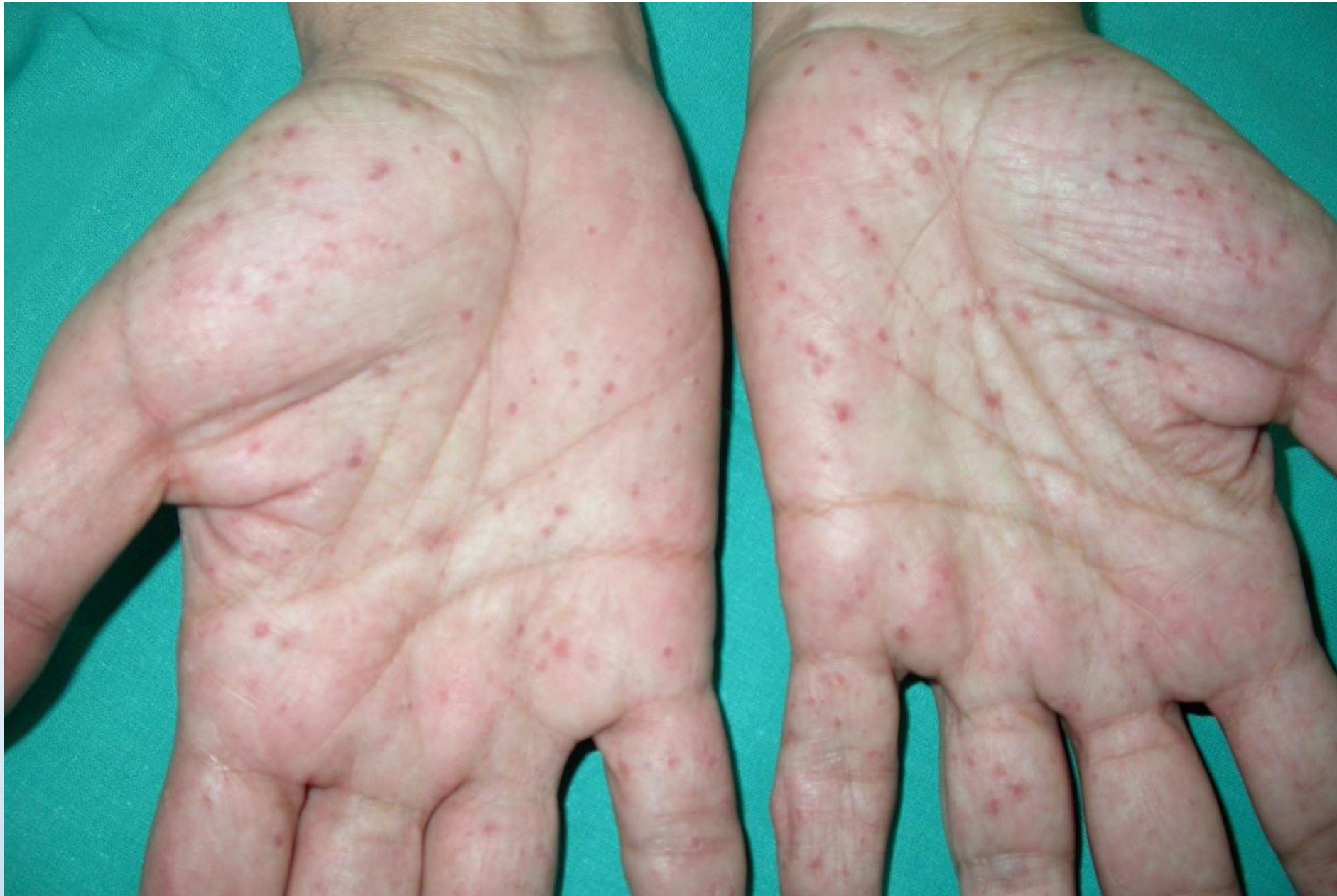Wolkow N, Jakobiec FA, Yoon MK. Intratarsal keratinous eyelid cysts in Gorlin syndrome: A review and reappraisal. *Surv Ophthalmol.* 2018 Sep-Oct;63(5):711-718. doi: 10.1016/j.survophthal.2017.12.007. Epub 2017 Dec 27. PMID: 29287708.

Intratarsal keratinous cyst



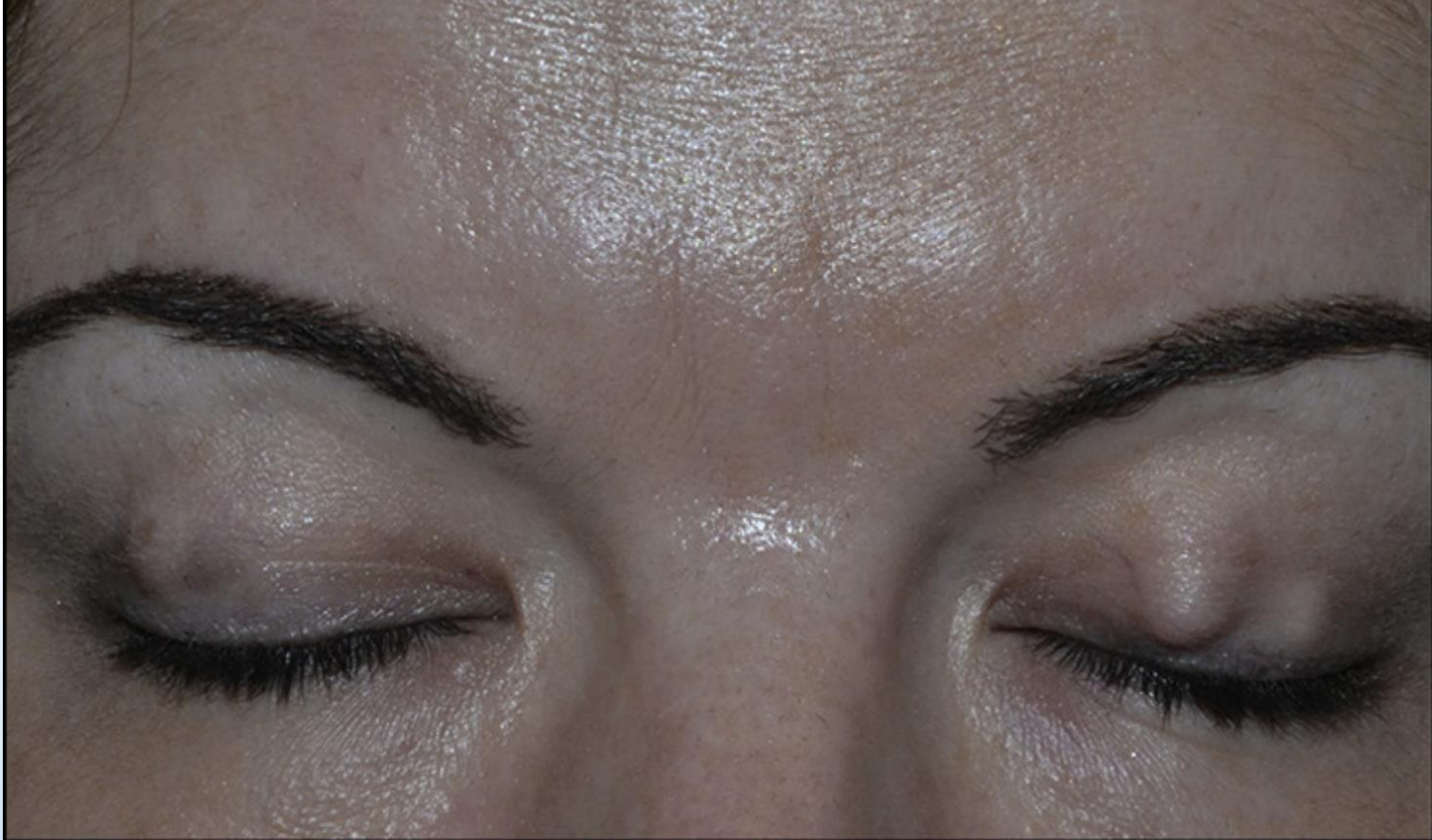Odontogenic keratocyst






<https://www.actasdermo.org/en-gorlin-syndrome-articulo-S1578219018300040>

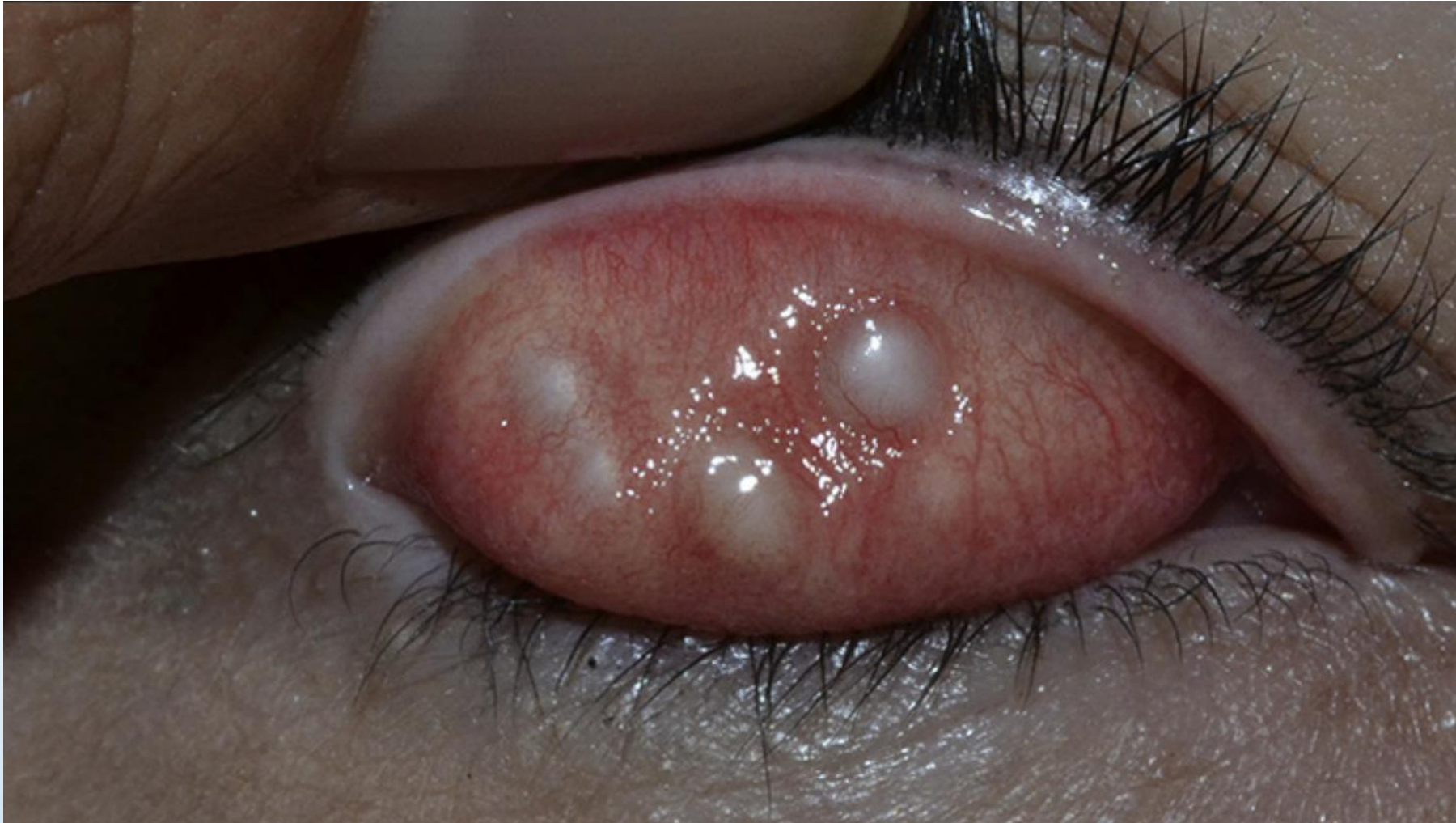




Wolkow N, Jakobiec FA, Yoon MK. Intratarsal keratinous eyelid cysts in Gorlin syndrome: A review and reappraisal. *Surv Ophthalmol.* 2018 Sep-Oct;63(5):711-718. doi: 10.1016/j.survophthal.2017.12.007. Epub 2017 Dec 27. PMID: 29287708.



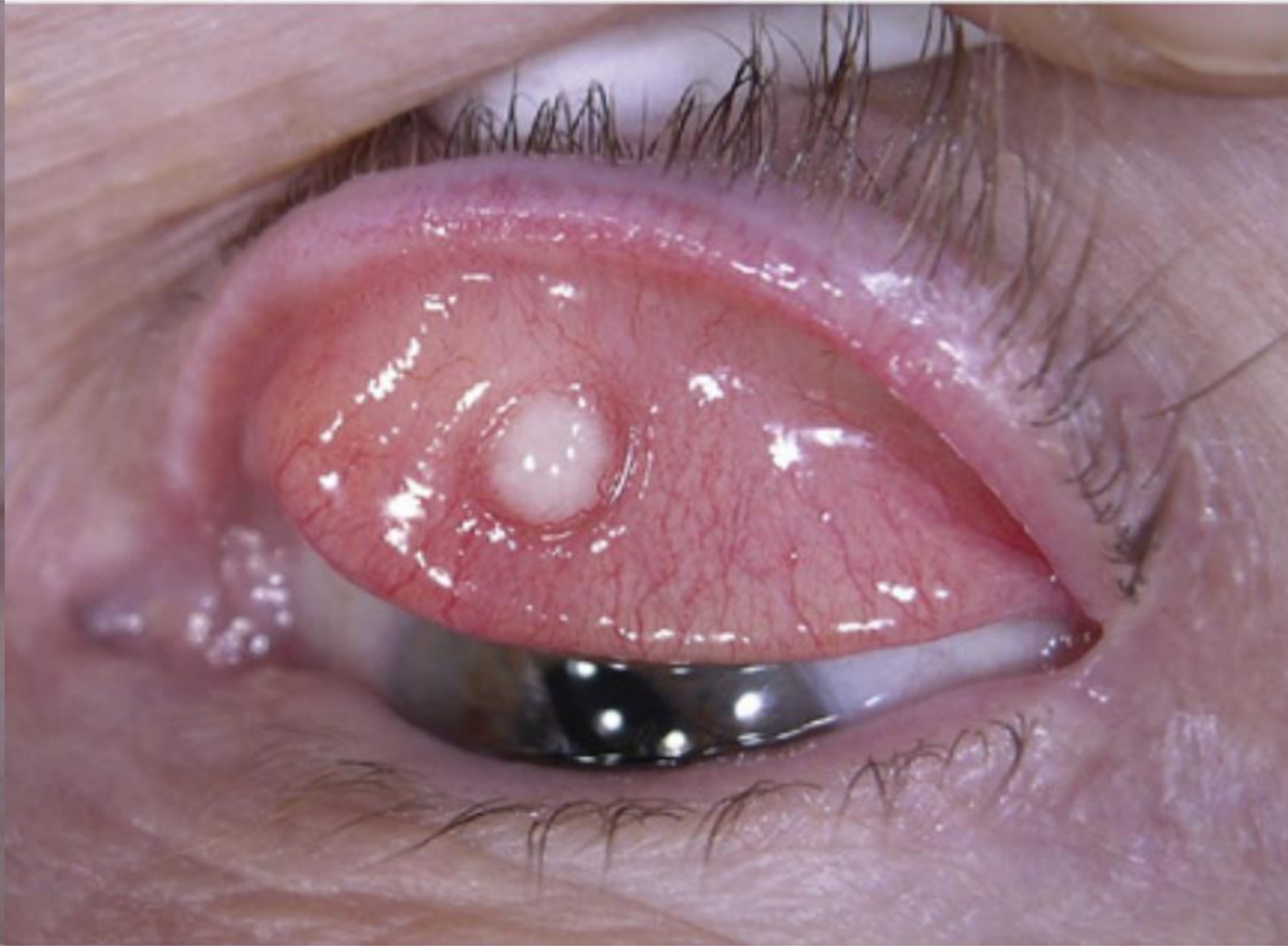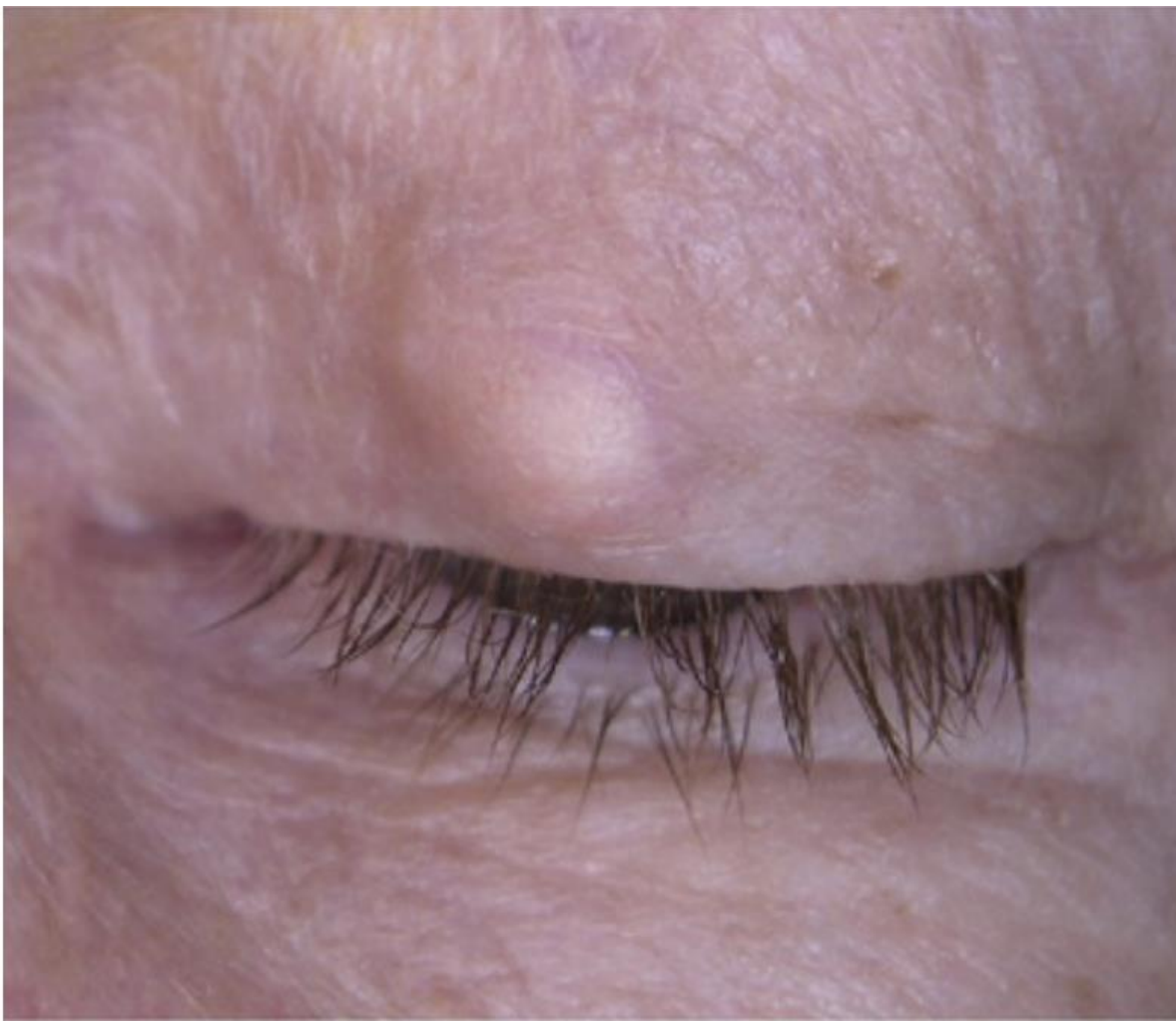Multiple cysts at a younger age -> suggests Gorlin syndrome



Wolkow N, Jakobiec FA, Yoon MK. Intratarsal keratinous eyelid cysts in Gorlin syndrome: A review and reappraisal. *Surv Ophthalmol.* 2018 Sep-Oct;63(5):711-718. doi: 10.1016/j.survophthal.2017.12.007. Epub 2017 Dec 27. PMID: 29287708.

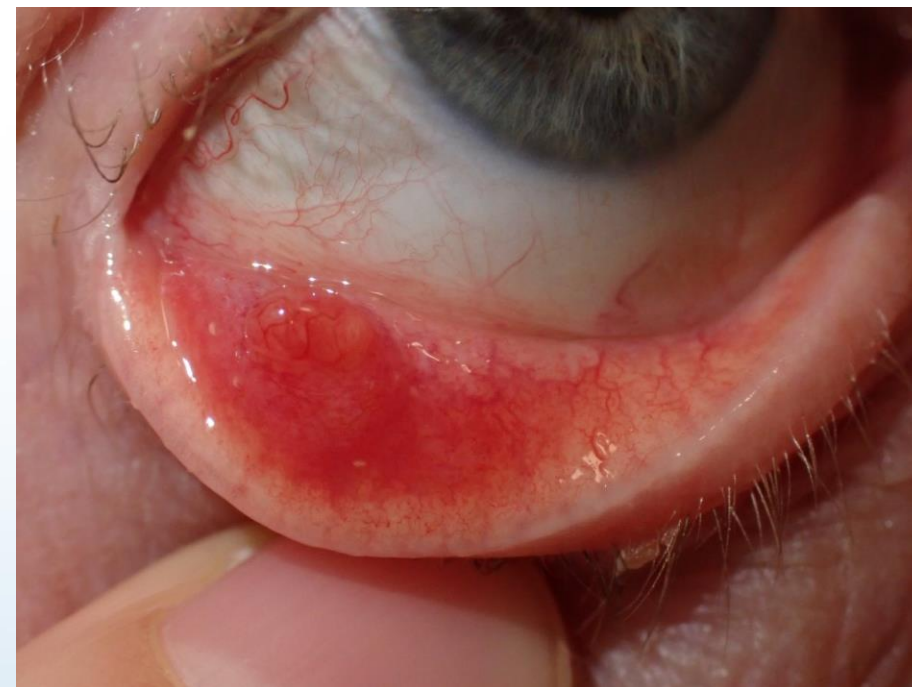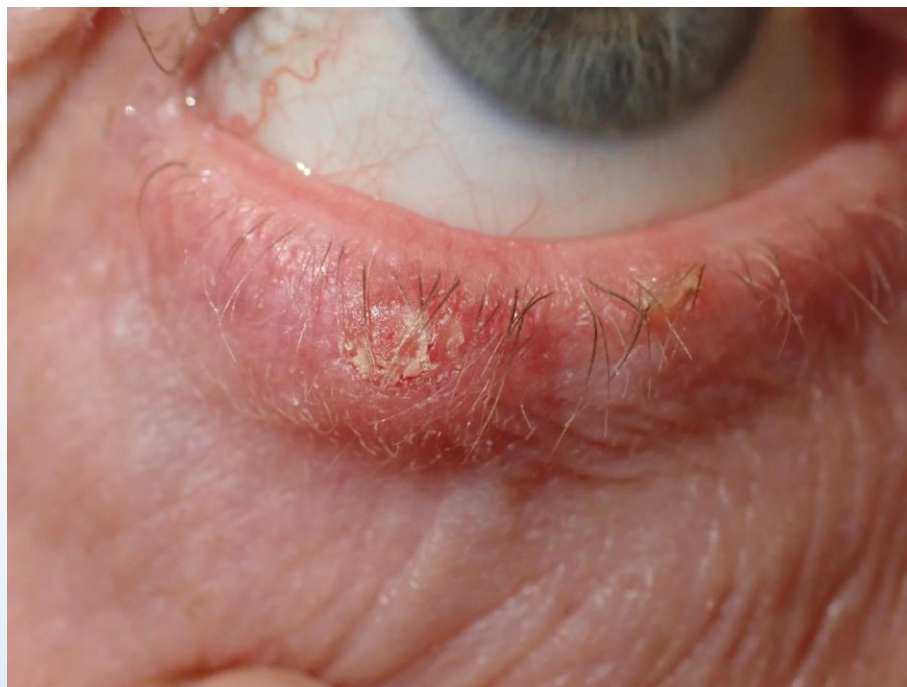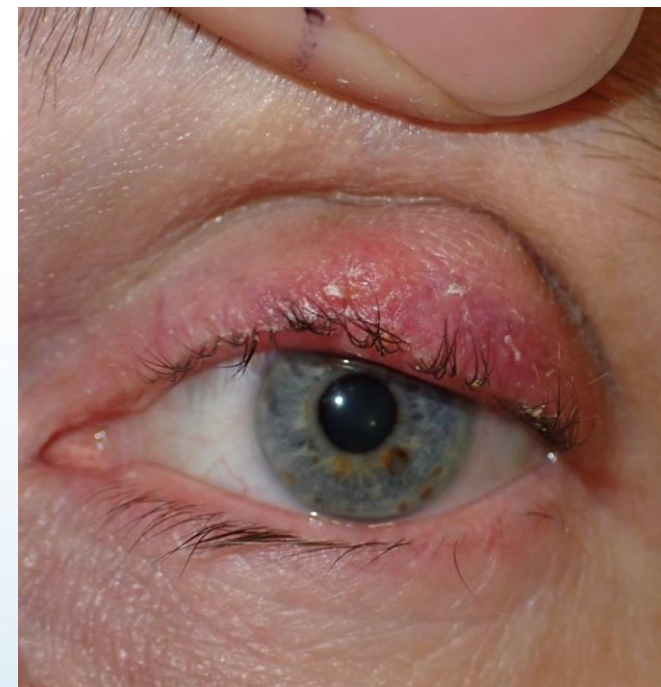


Single cyst, older age --> more likely sporadic

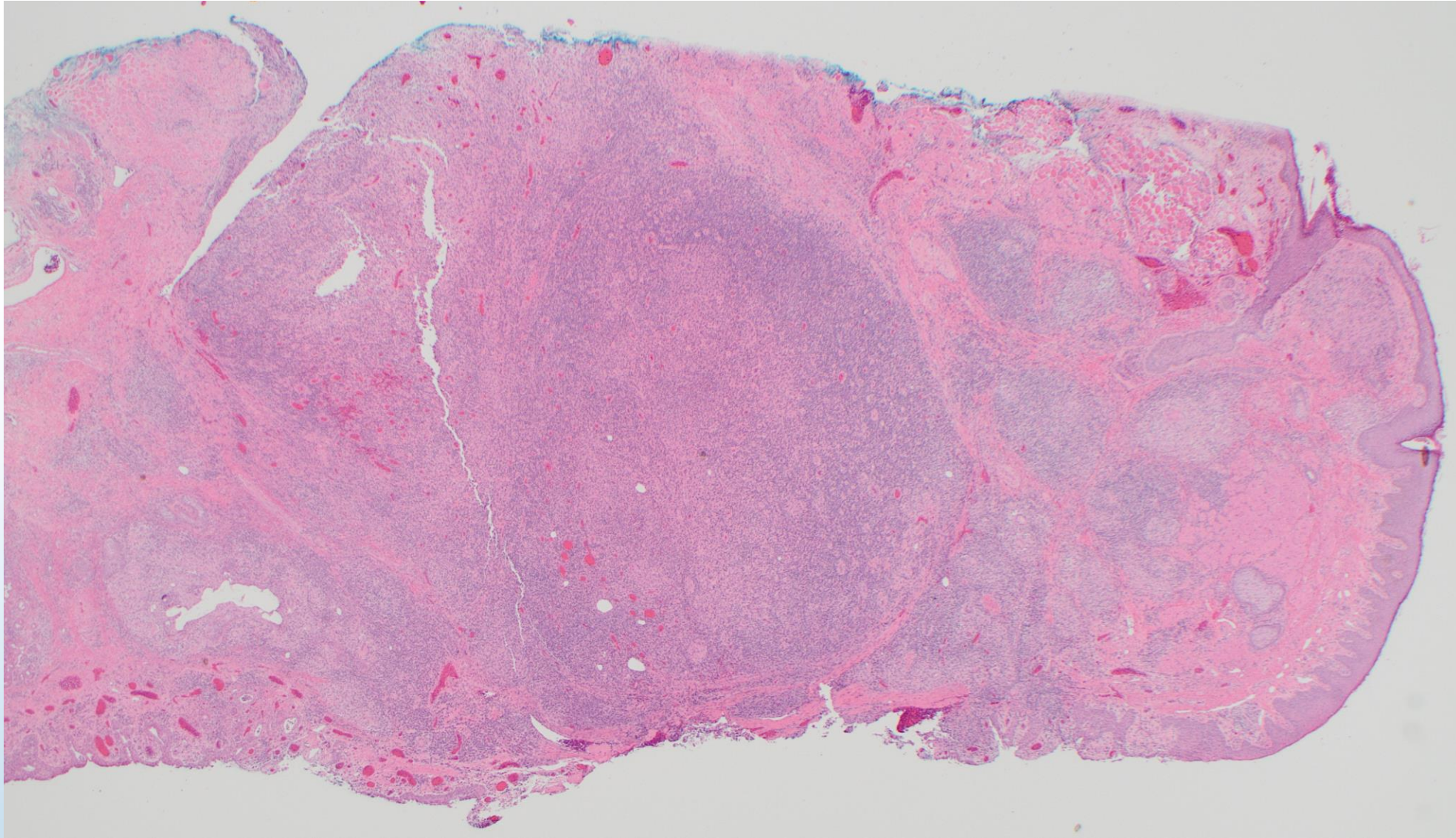


Wolkow N, Jakobiec FA, Yoon MK. Intratarsal keratinous eyelid cysts in Gorlin syndrome: A review and reappraisal. *Surv Ophthalmol.* 2018 Sep-Oct;63(5):711-718. doi: 10.1016/j.survophthal.2017.12.007. Epub 2017 Dec 27. PMID: 29287708.

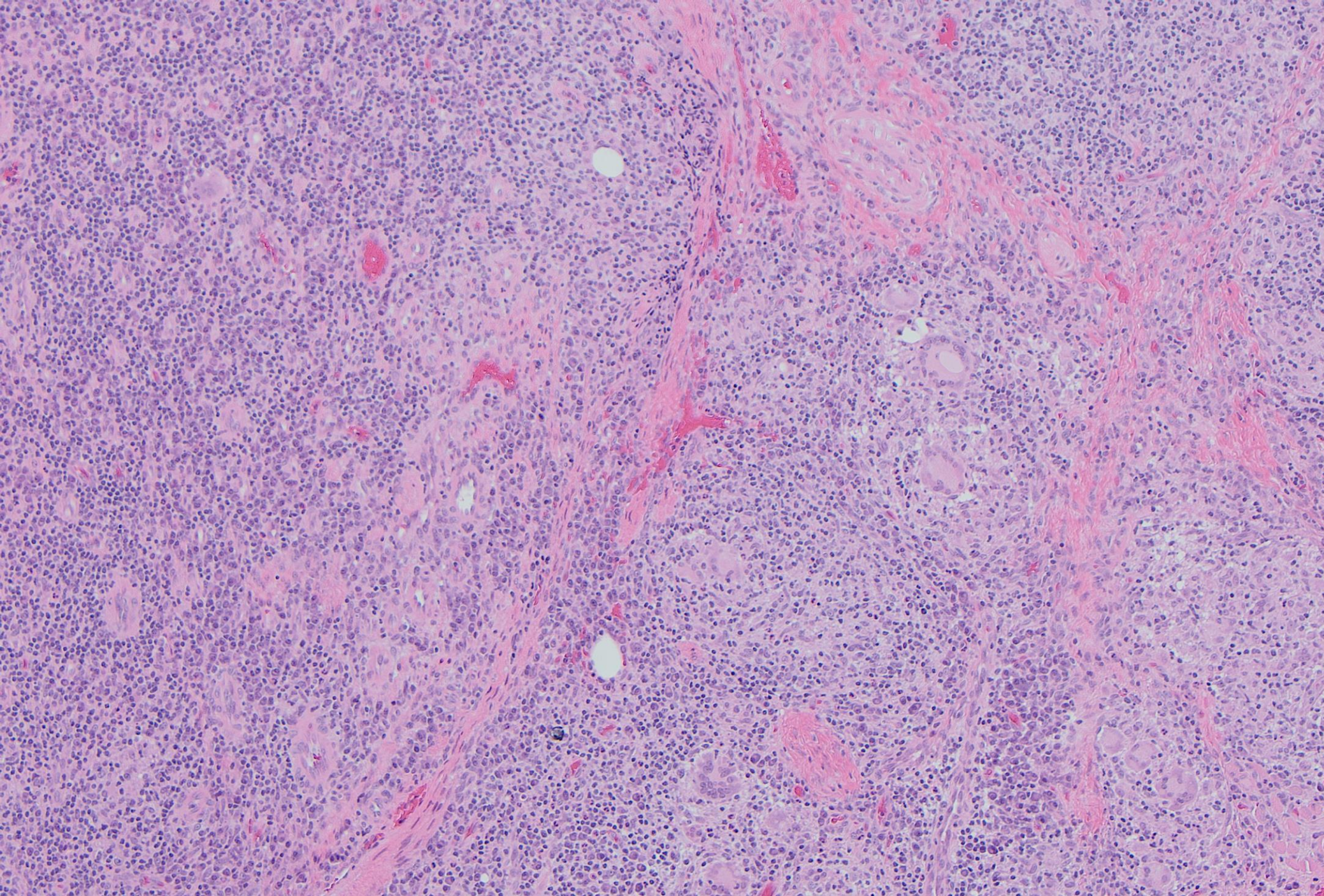
Clinical Differential Diagnosis: Chalazion



Chalazion

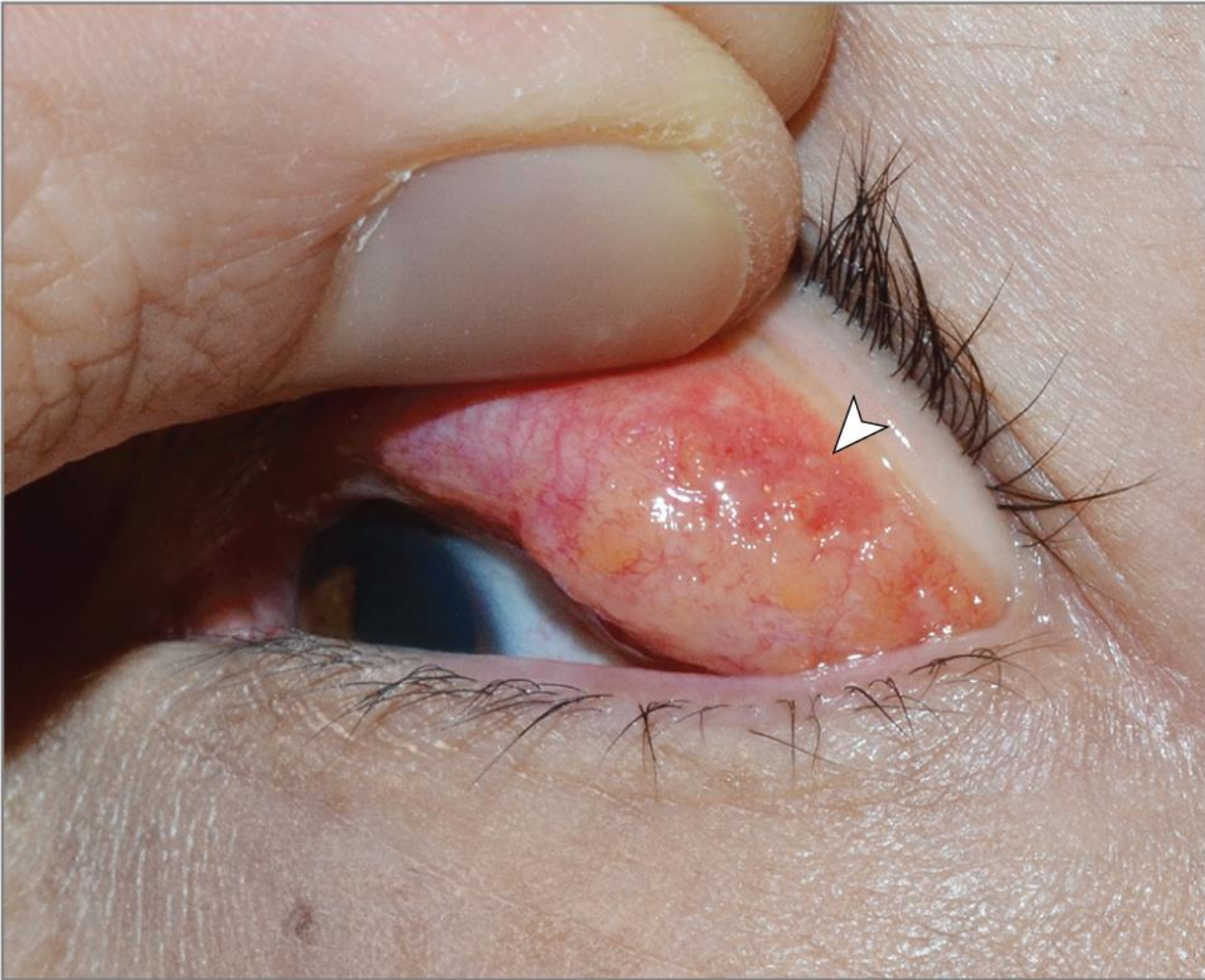

Chalazion

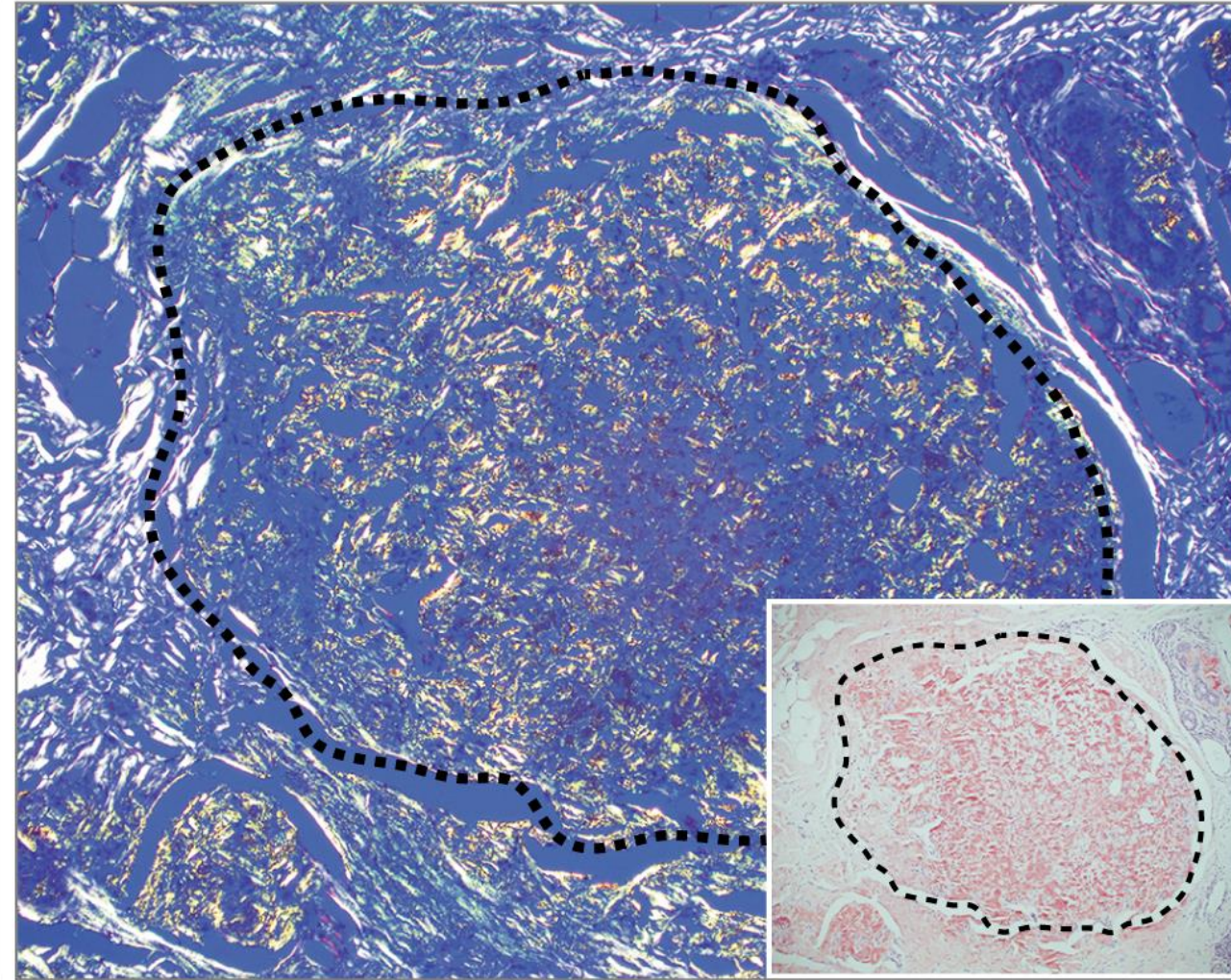


Clinical Differential Diagnosis: Localized amyloidosis

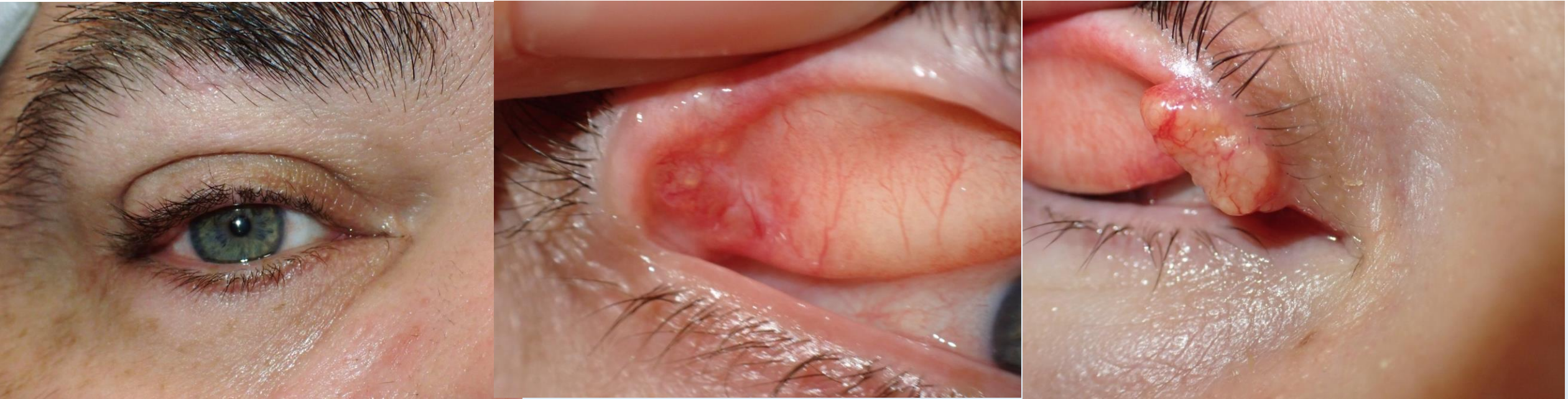A Everted upper eyelid



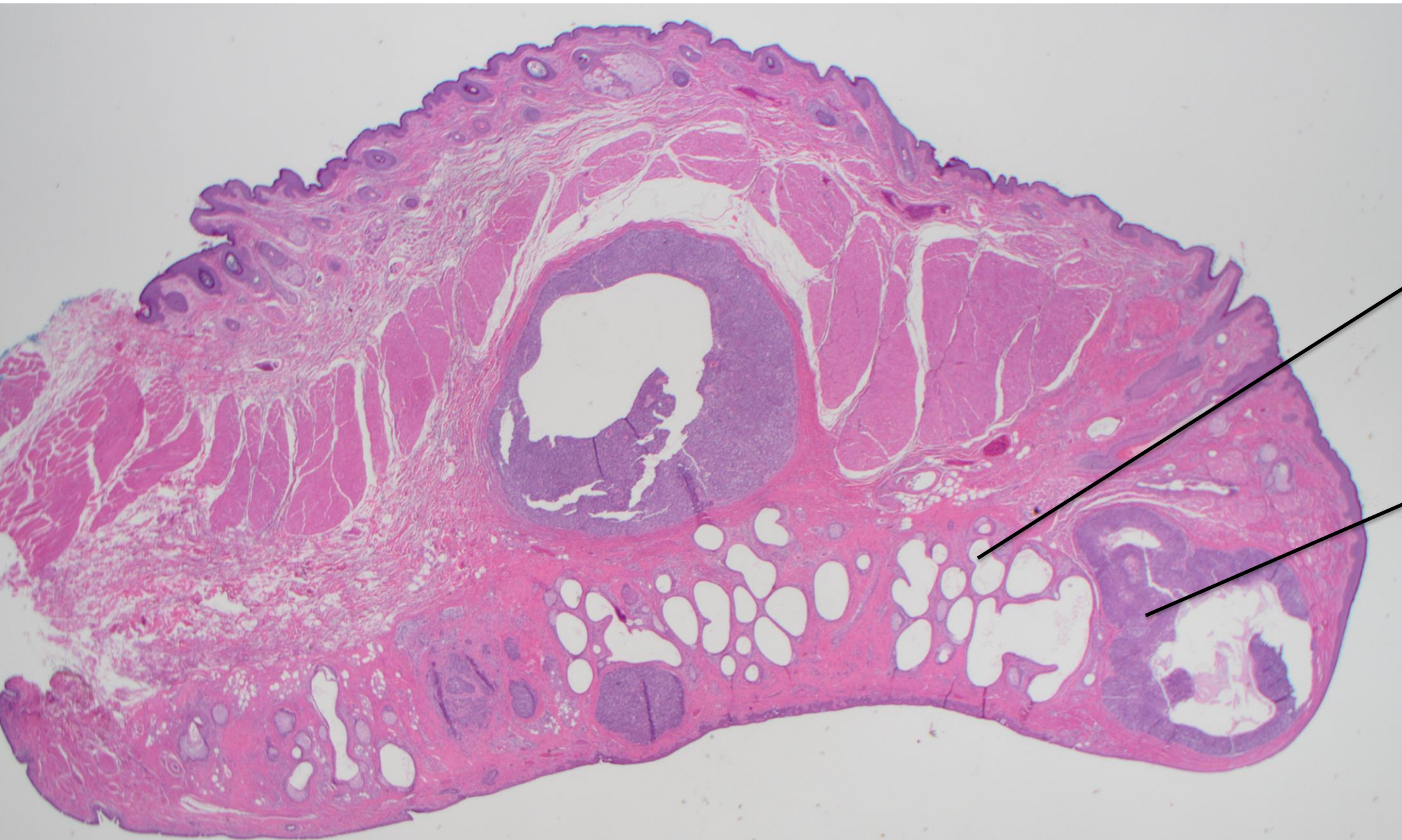
B Histopathologic appearance of the lesion



Clinical differential diagnosis: Sebaceous carcinoma



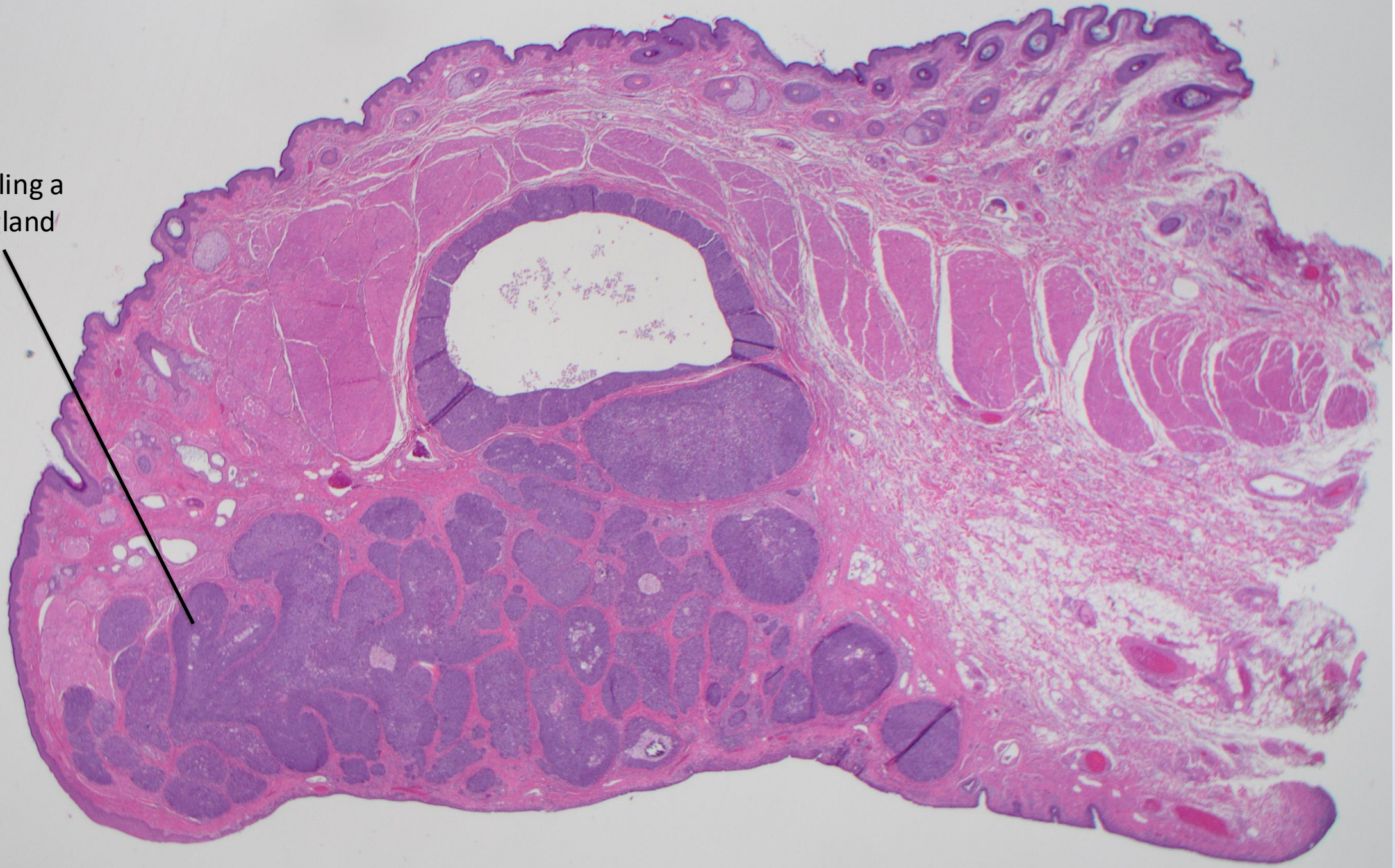
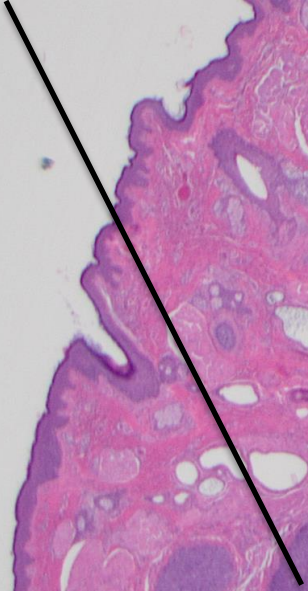
Sebaceous carcinoma

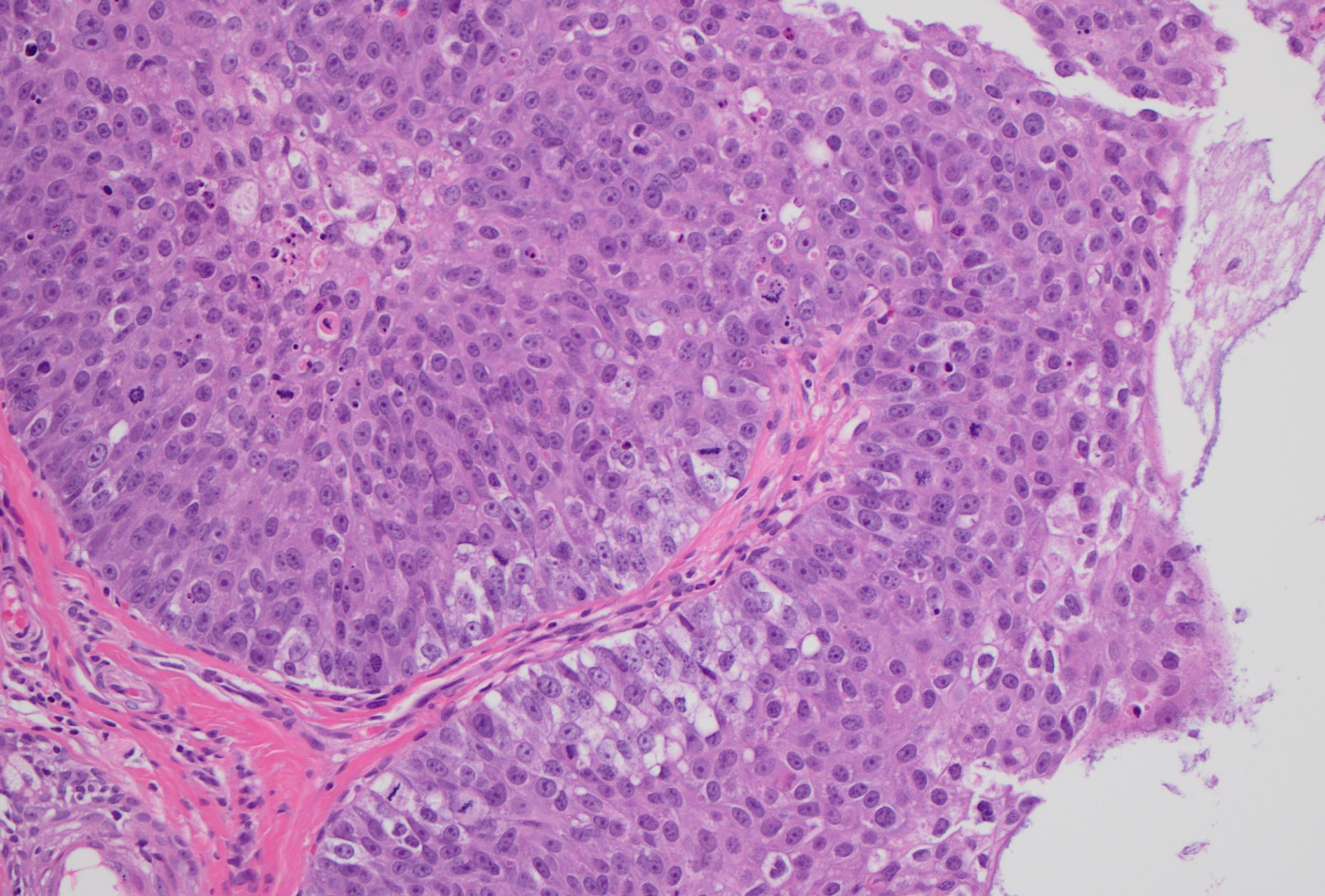


Dilated
meibomian
gland duct

Sebaceous
carcinoma

Sebaceous carcinoma filling a meibomian gland

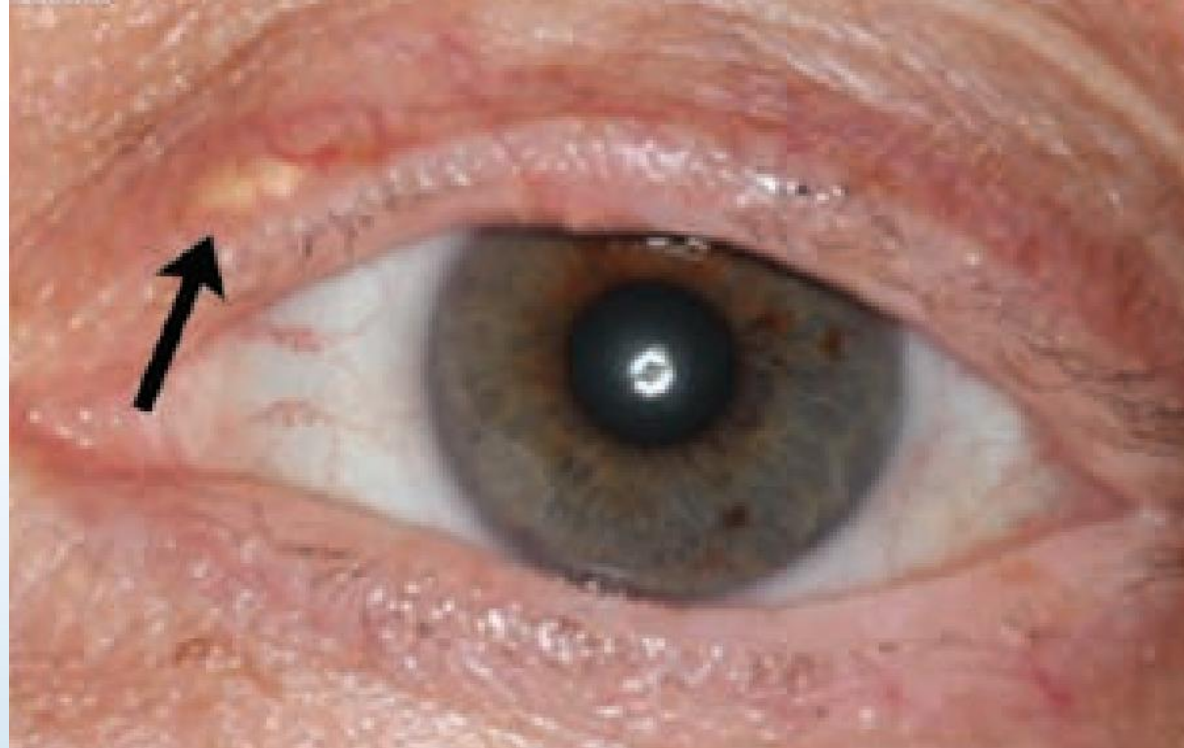



Sebaceous carcinoma

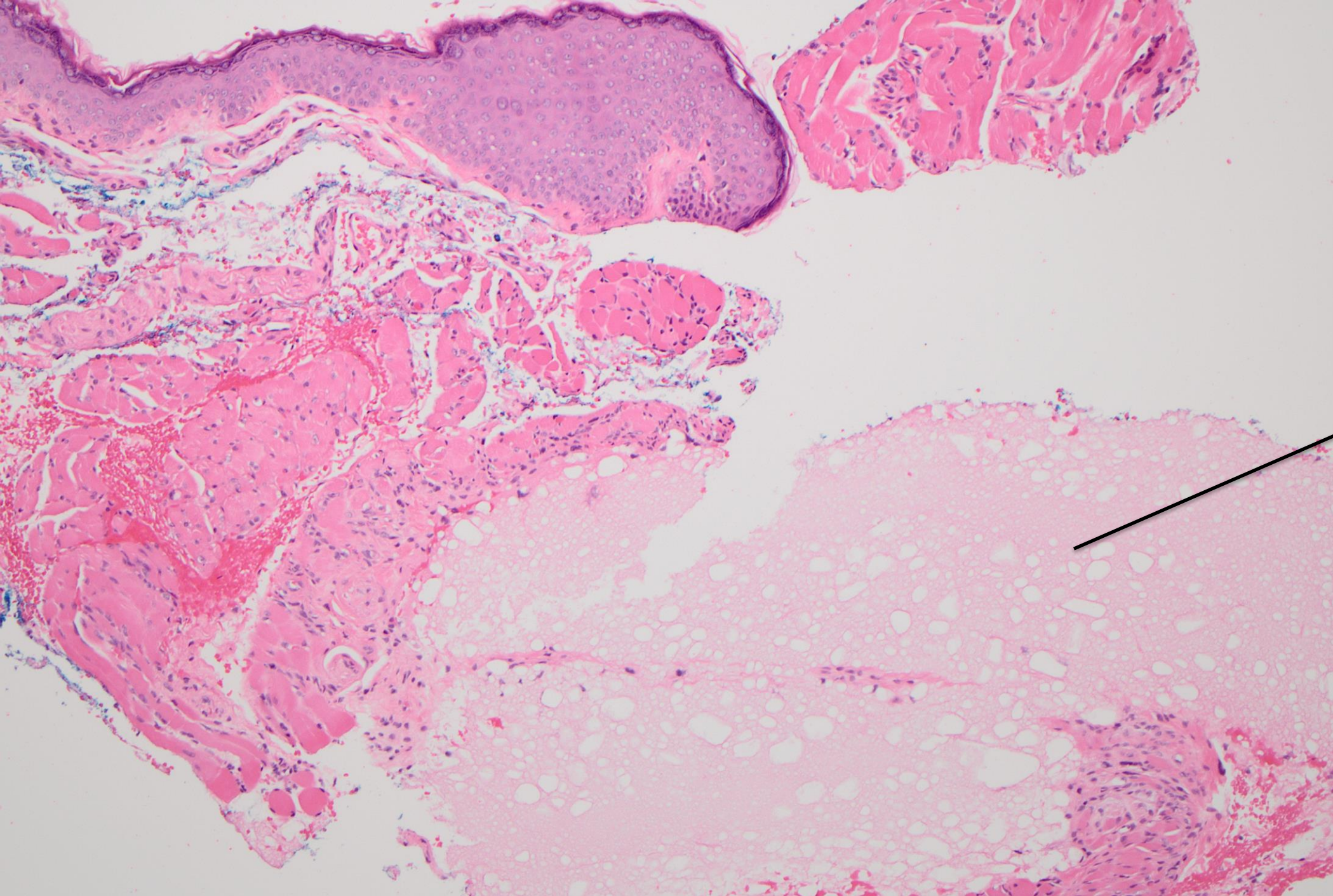


Clinical differential diagnosis: injected triamcinolone acetonide



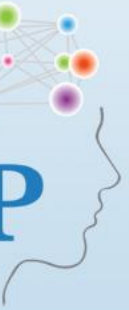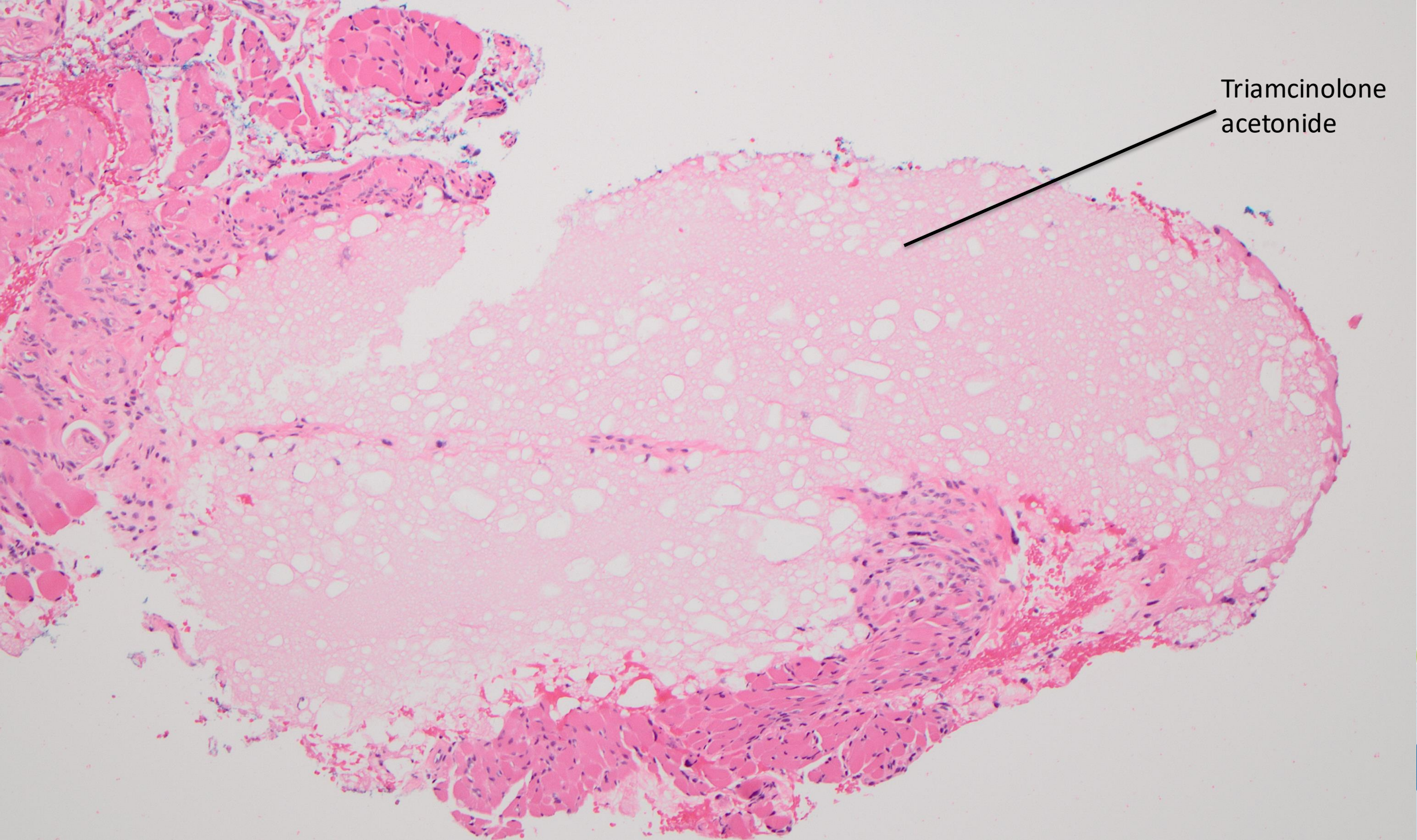
Wolkow N, Jakobiec FA, Hatton MP. A Common Procedure With an Uncommon Pathology: Triamcinolone Acetonide Eyelid Injection. *Ophthalmic Plast Reconstr Surg.* 2018 May/Jun;34(3):e72-e73. PMID: 29346171.





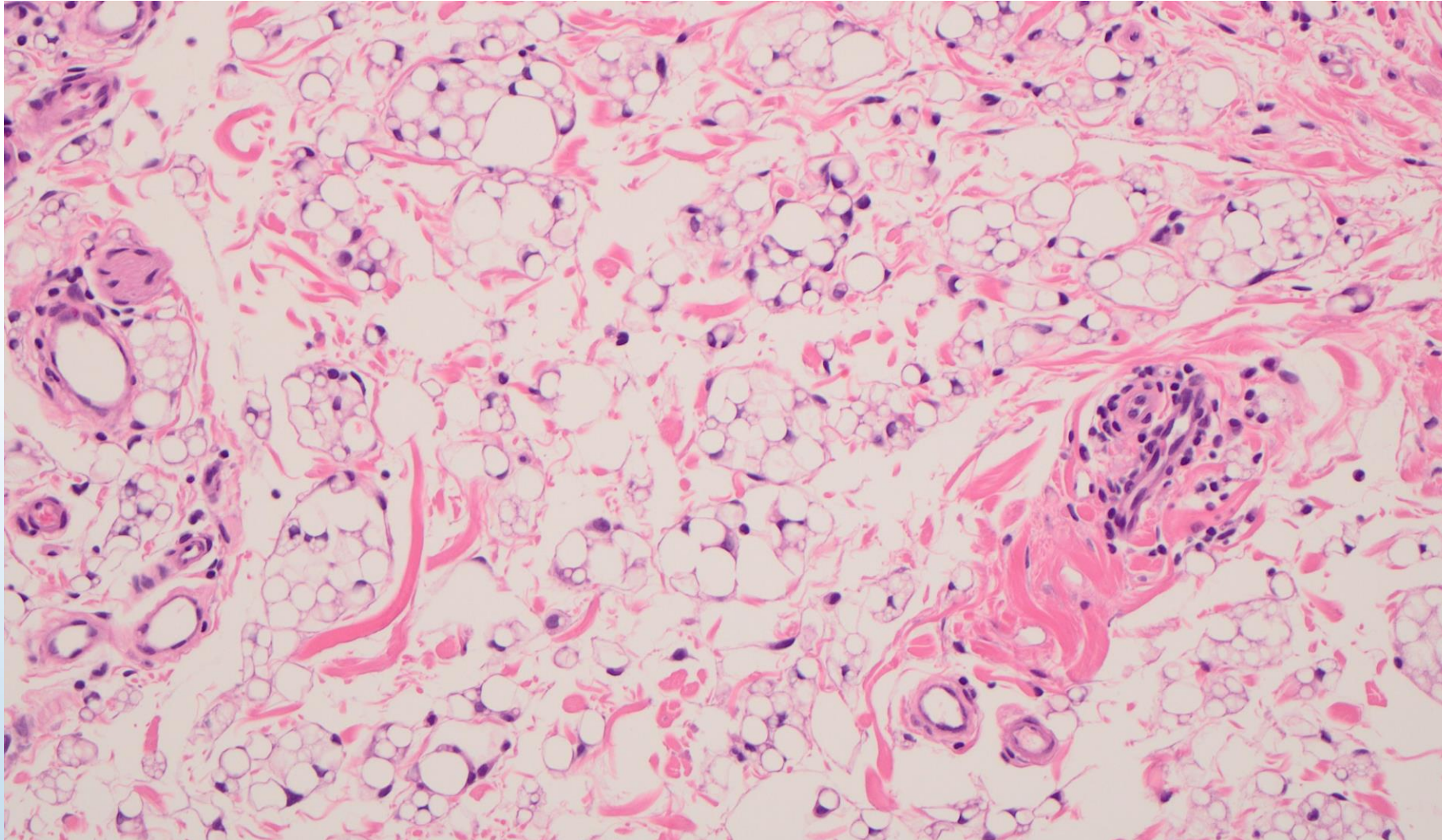
Triamcinolone
acetonide

Triamcinolone
acetonide



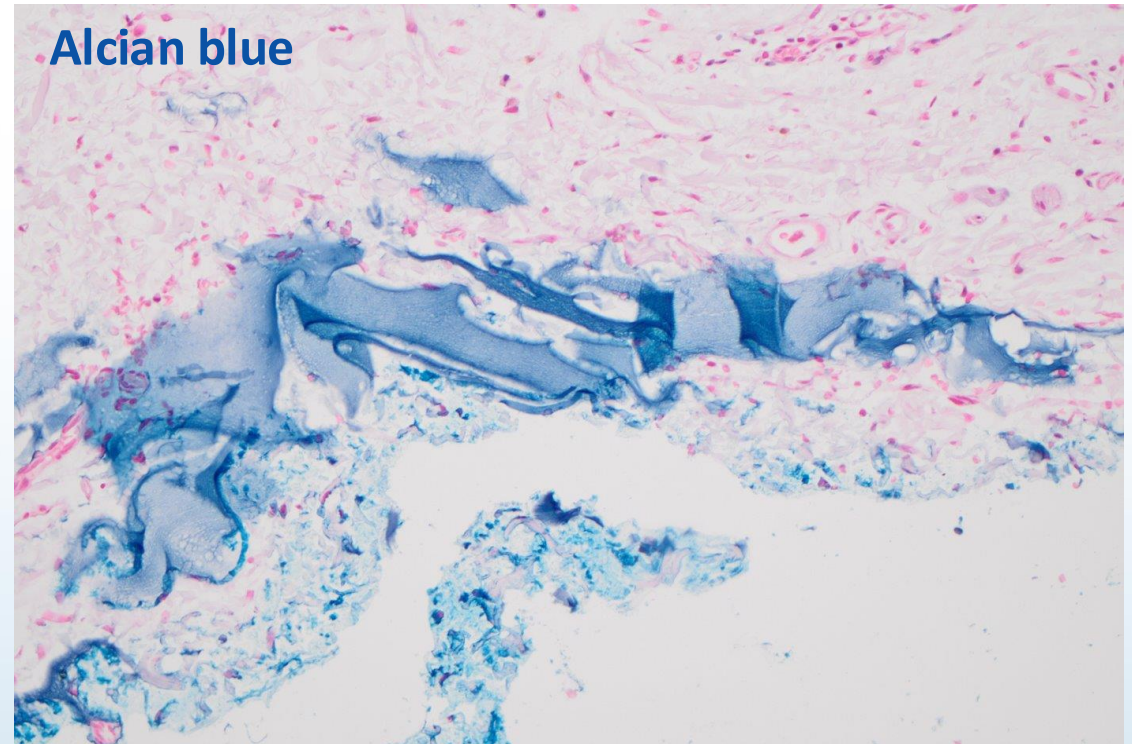
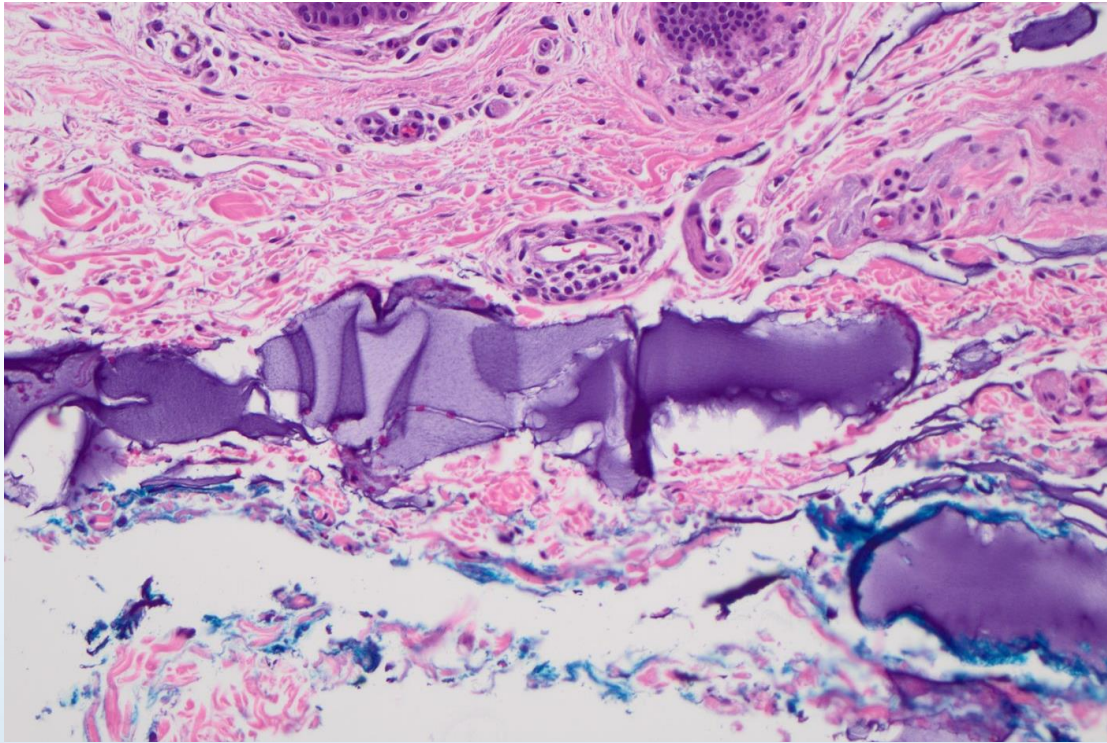
Foreign materials are commonly found in eyelid specimens

Silicone



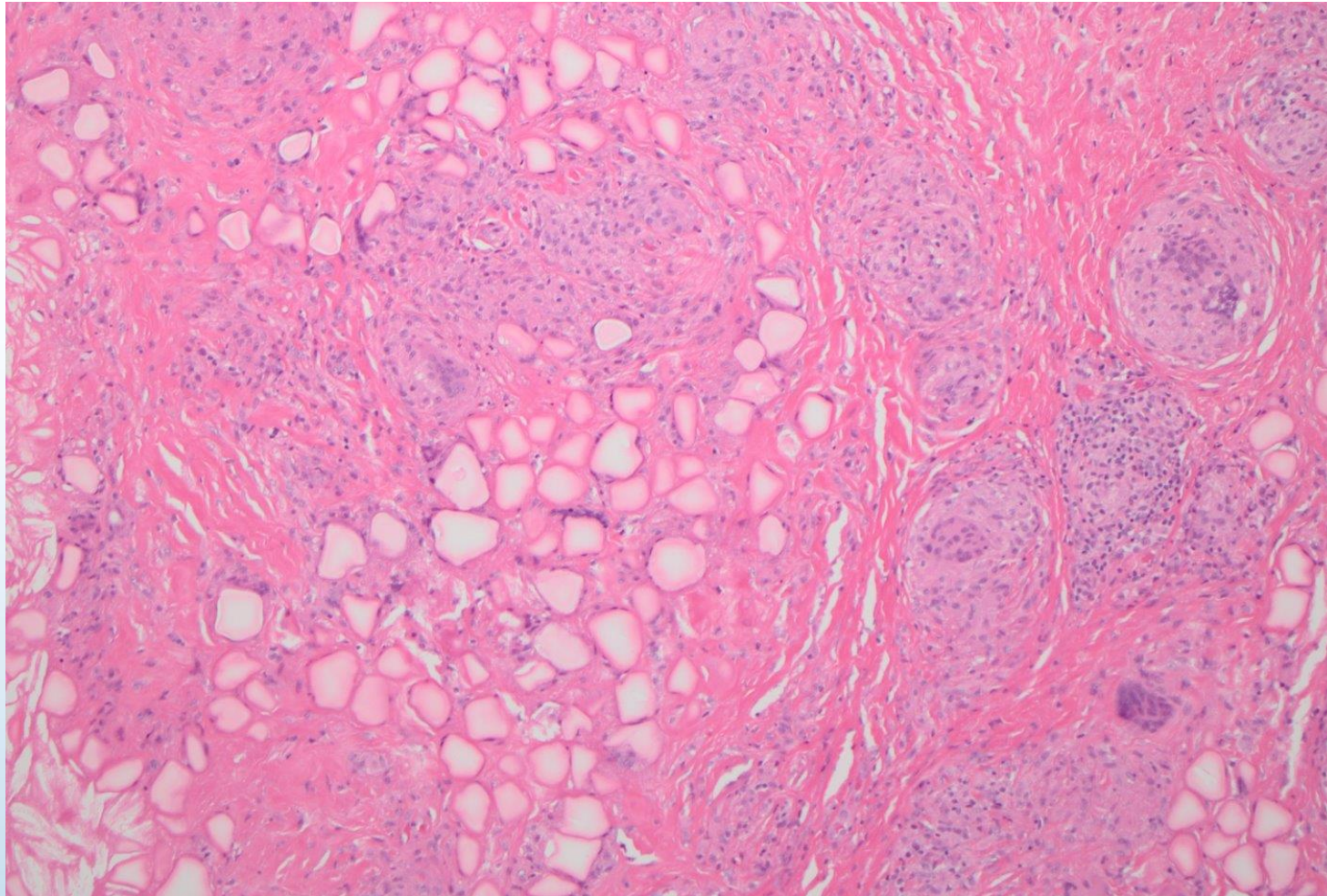
Foreign materials are commonly found in eyelid specimens

Hyaluronic acid



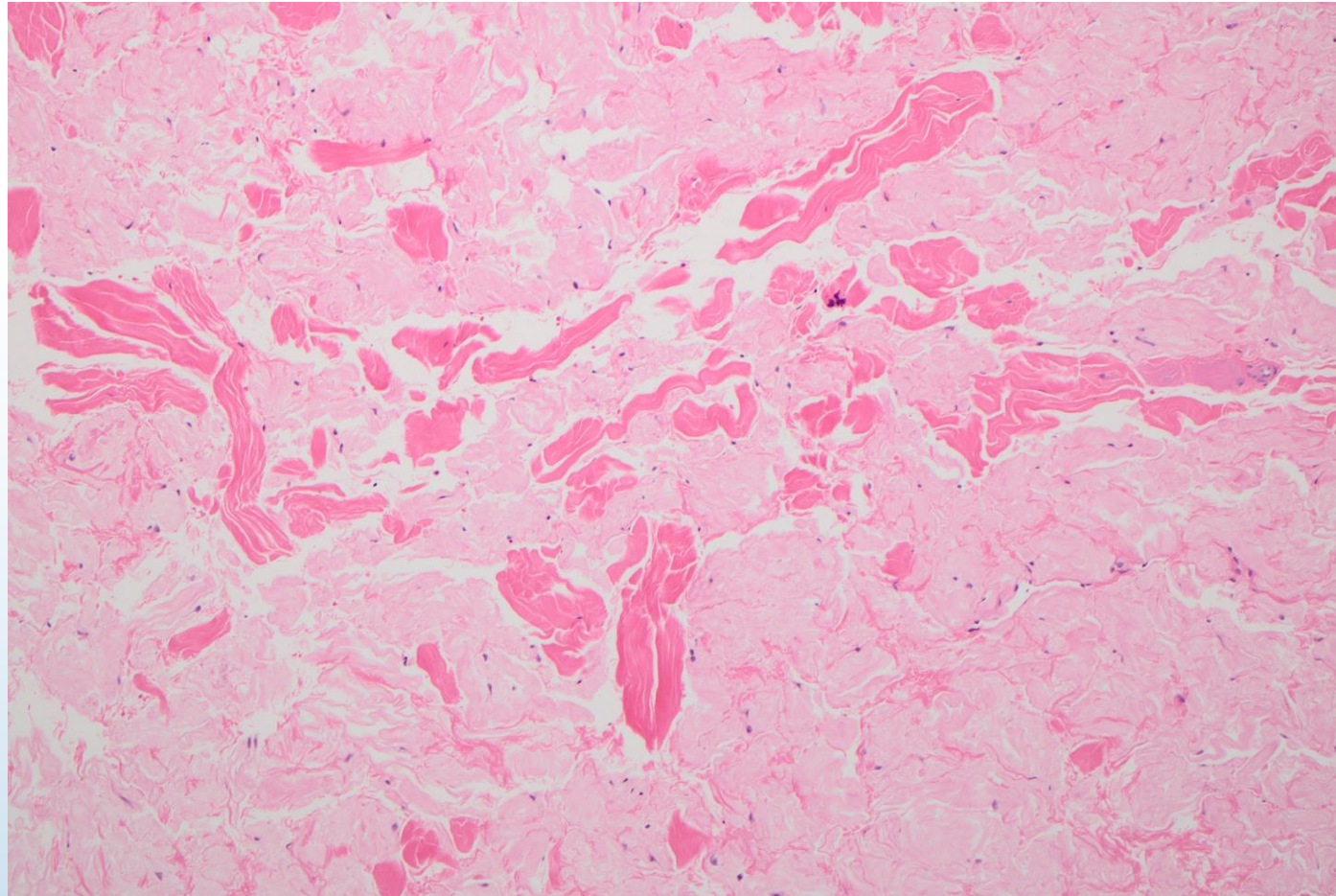
Foreign materials are commonly found in eyelid specimens

Acrylic particles



Foreign materials are commonly found in eyelid specimens

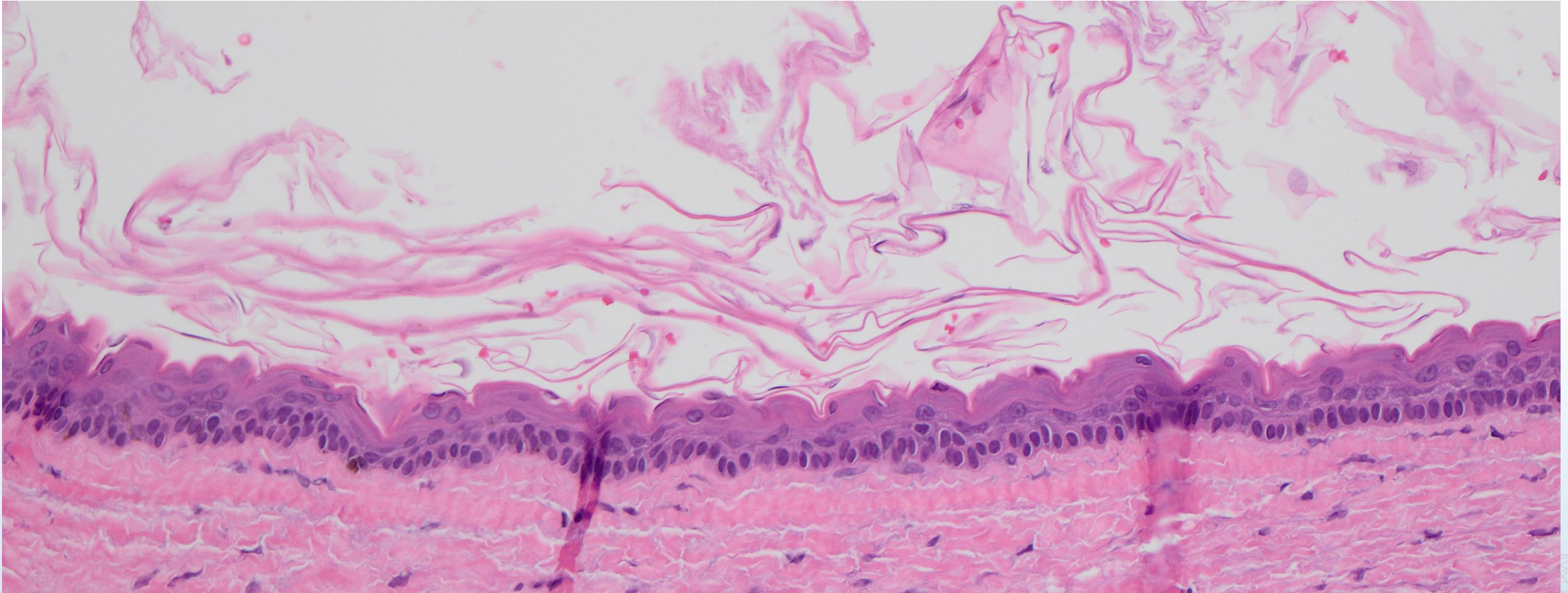
Porcine collagen



Wolkow N, Jakobiec FA, Dryja TP, Lefebvre DR. Mild Complications or Unusual Persistence of Porcine Collagen and Hyaluronic Acid Gel Following Periocular Filler Injections. *Ophthalmic Plast Reconstr Surg.* 2018 Sep/Oct;34(5):e143-e146.

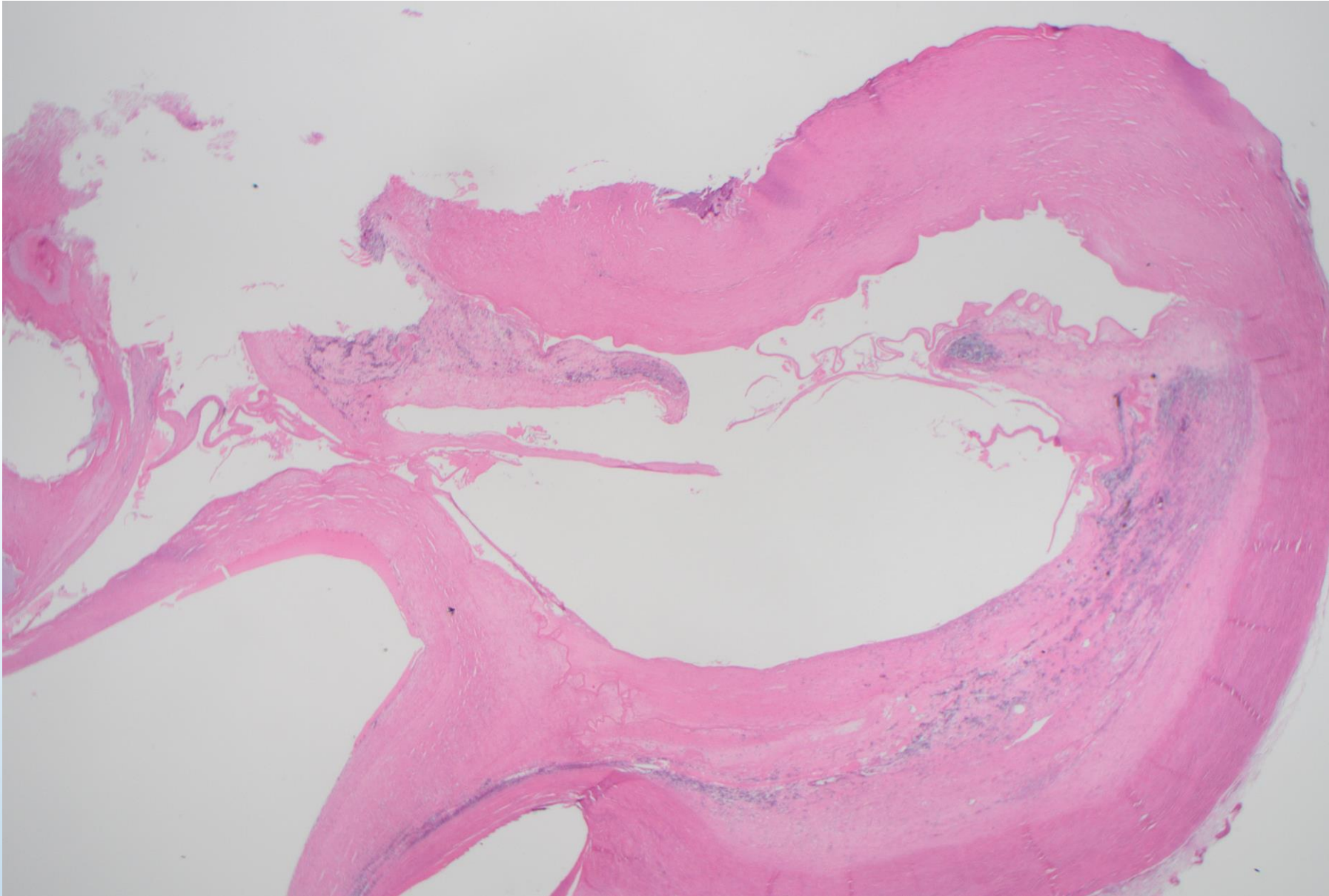


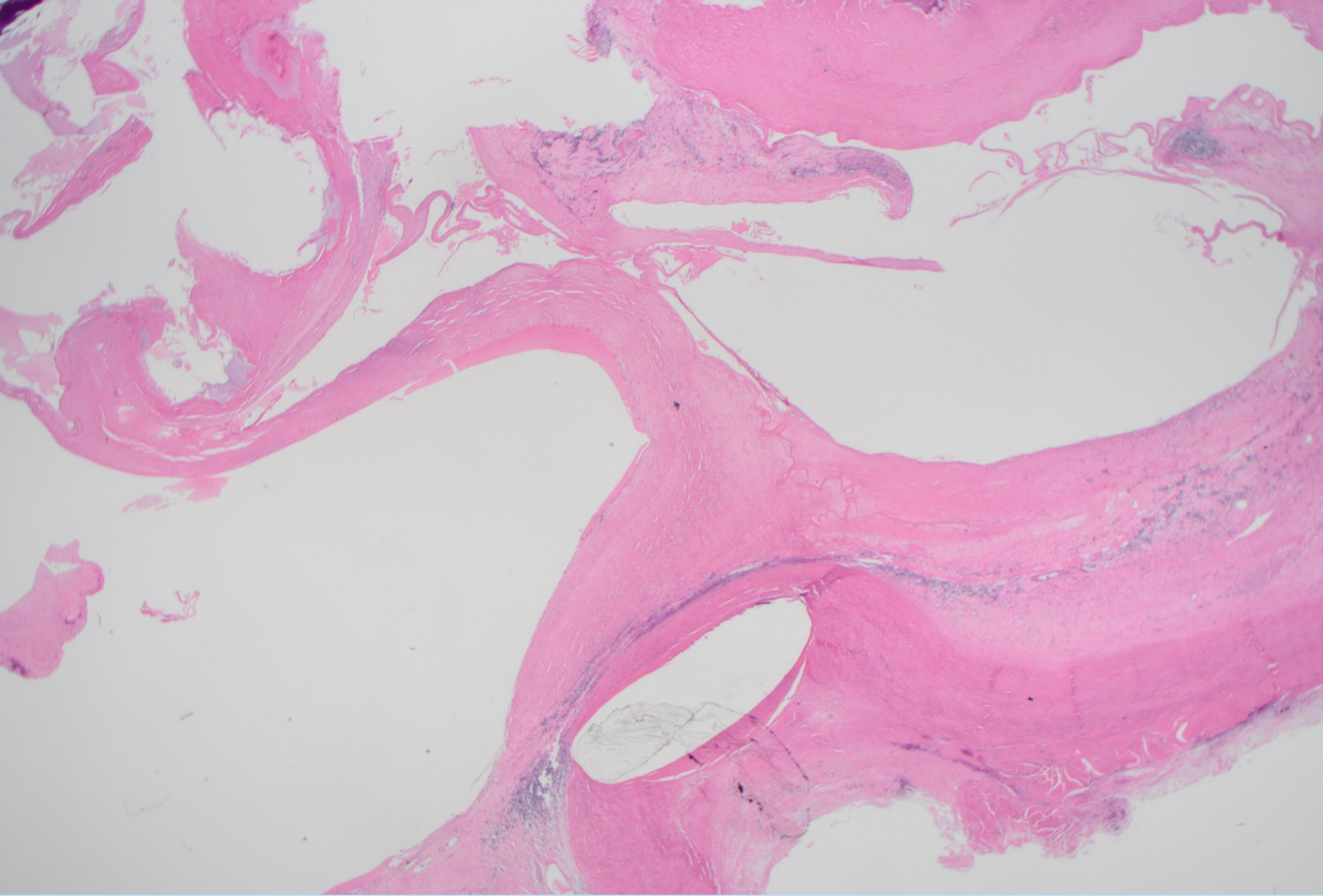
Summary – Case 2: Intratarsal Keratinous Cyst

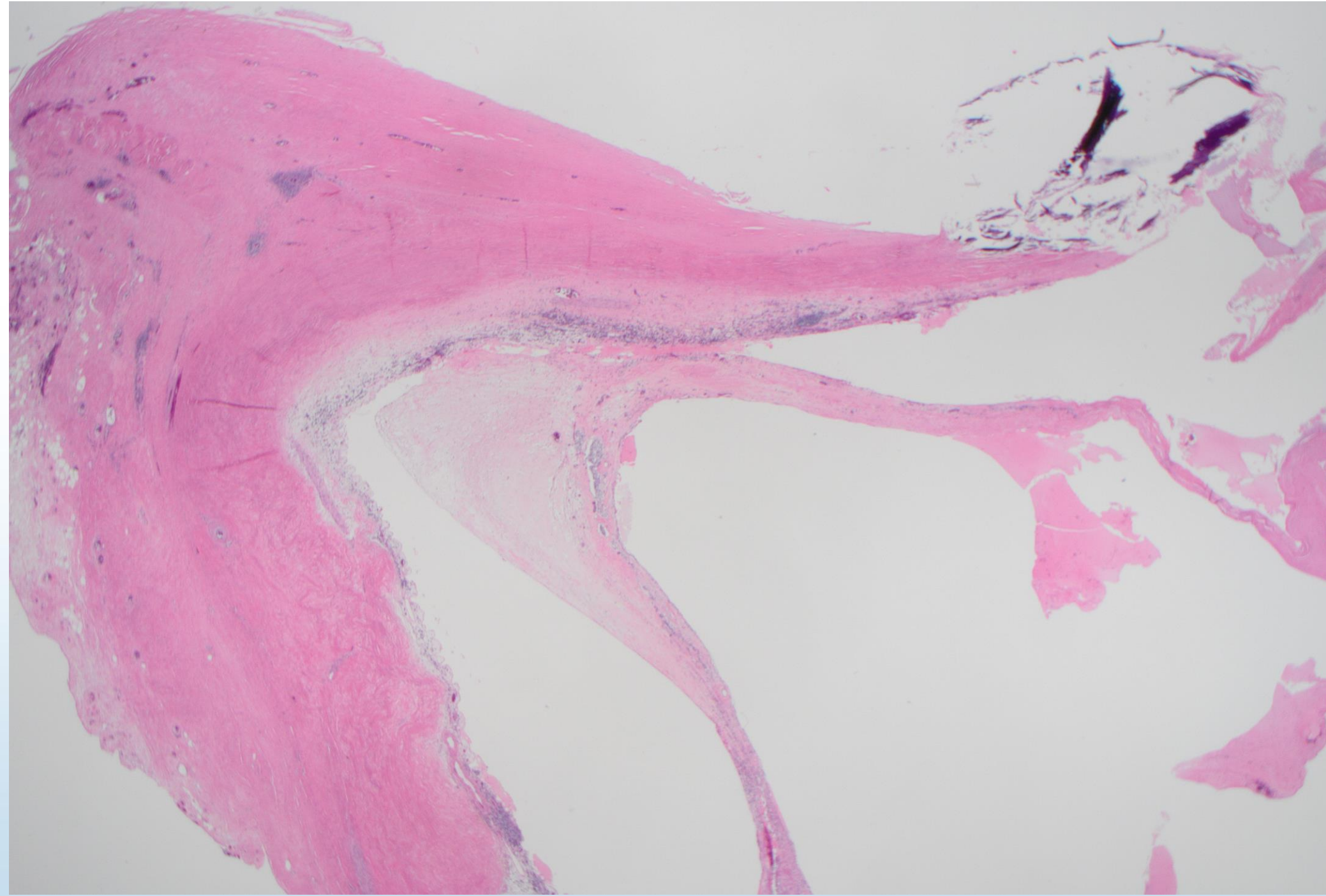


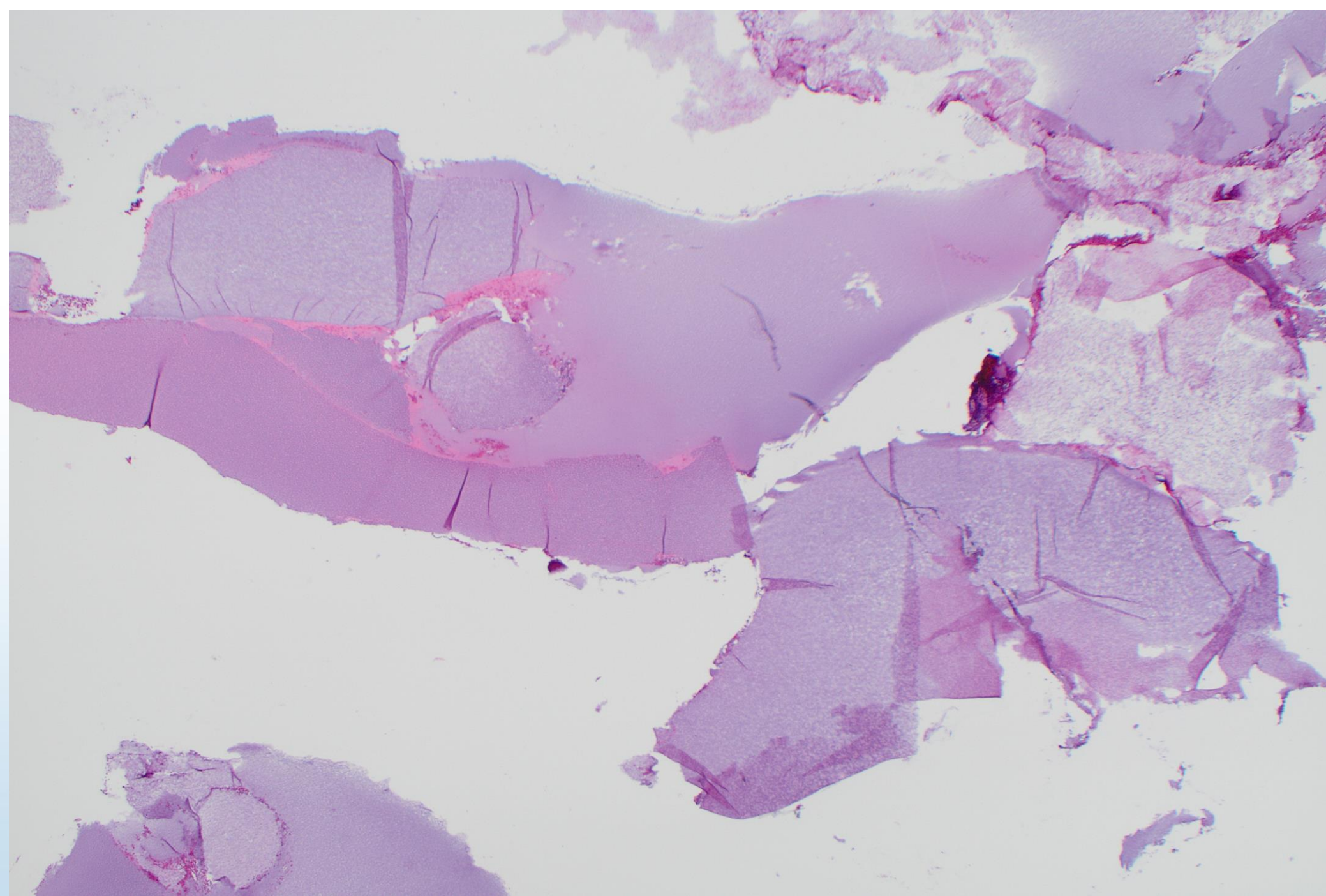


Case #3: Blind painful eye

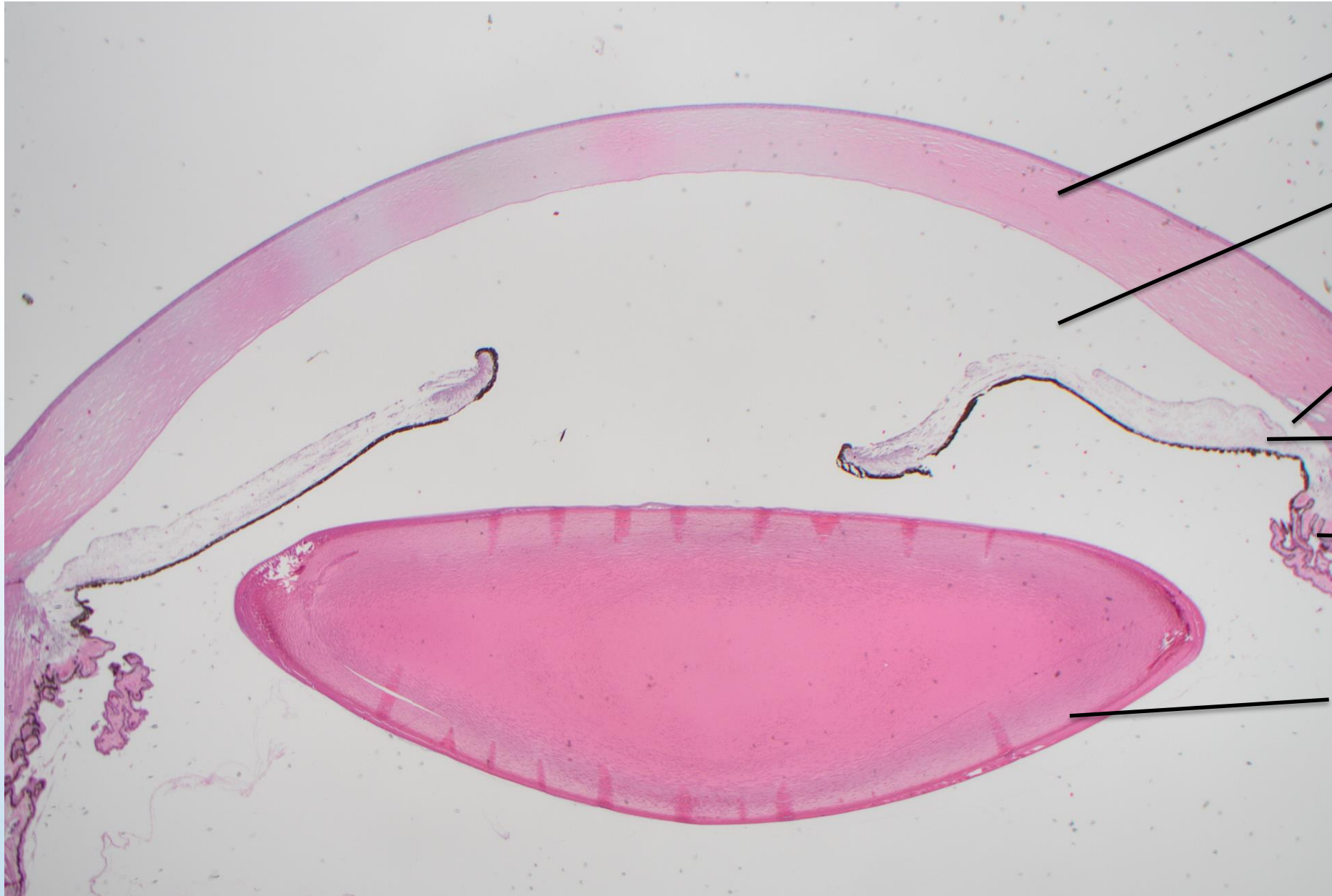







Review: Normal Eye Histology



Cornea

Anterior chamber

Angle

Iris

Ciliary body

Lens



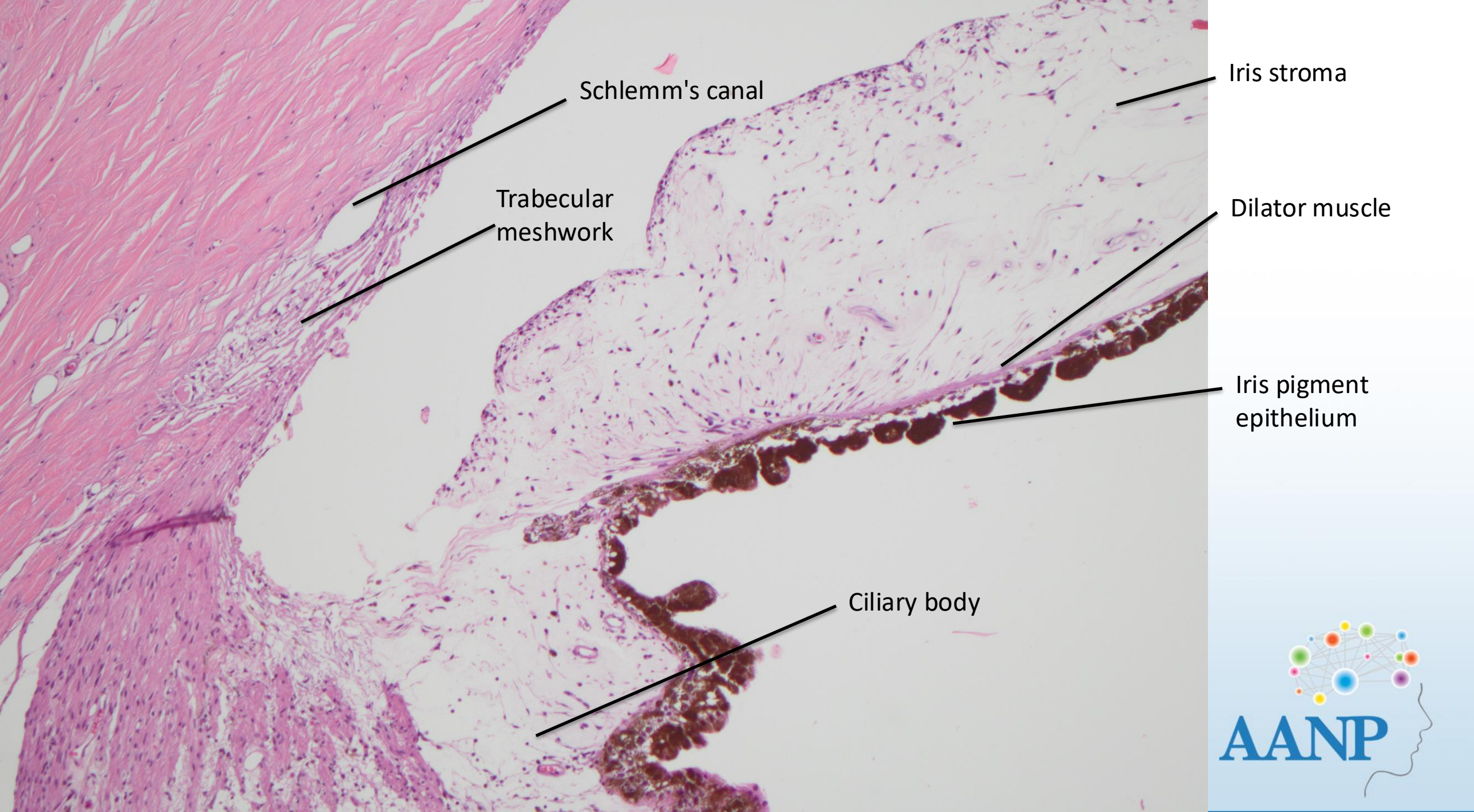Cornea

Iris sphincter
muscle

Trabecular
meshwork

Ciliary body





Schlemm's canal


Trabecular meshwork

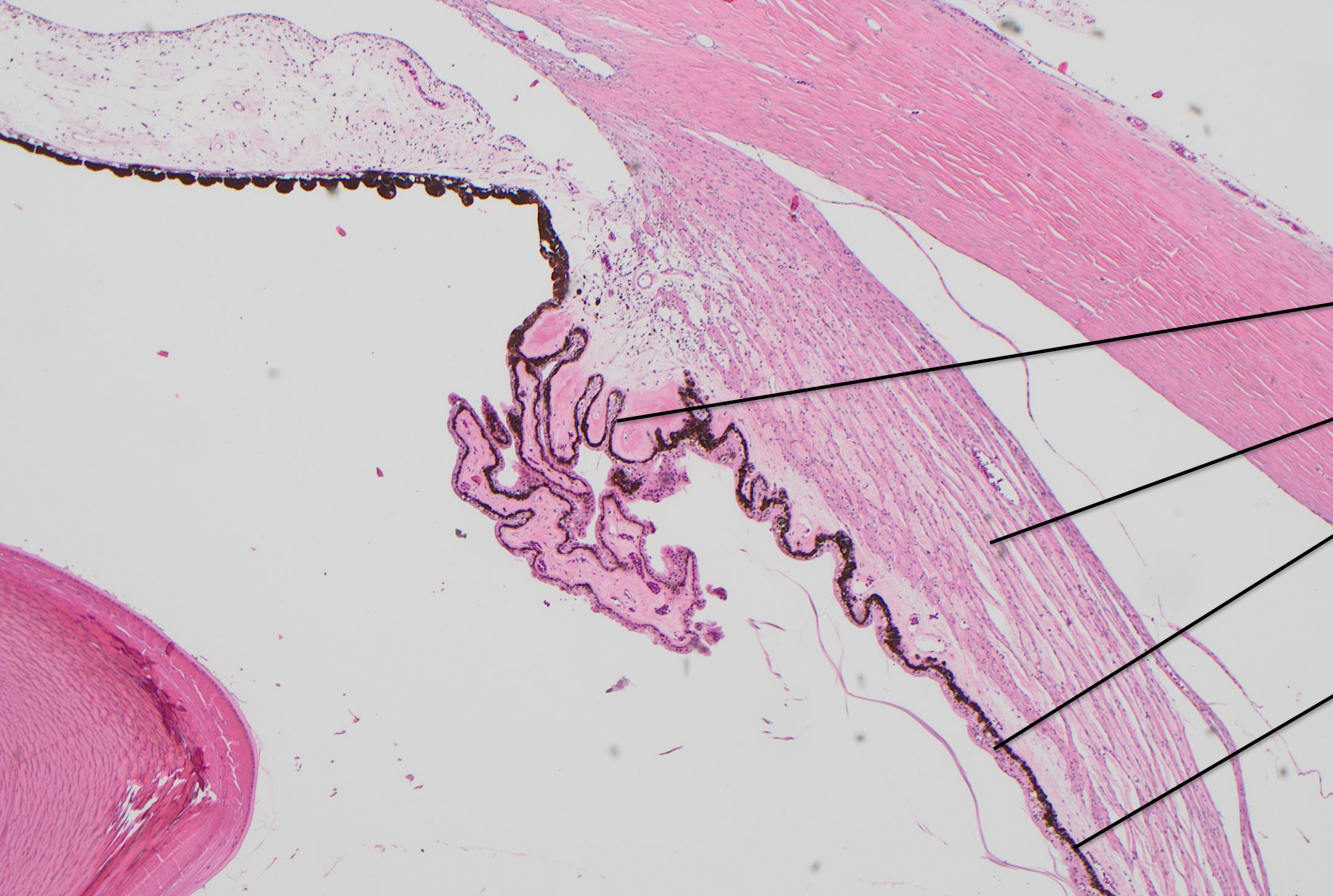
Iris stroma

Dilator muscle

Iris pigment epithelium

Ciliary body






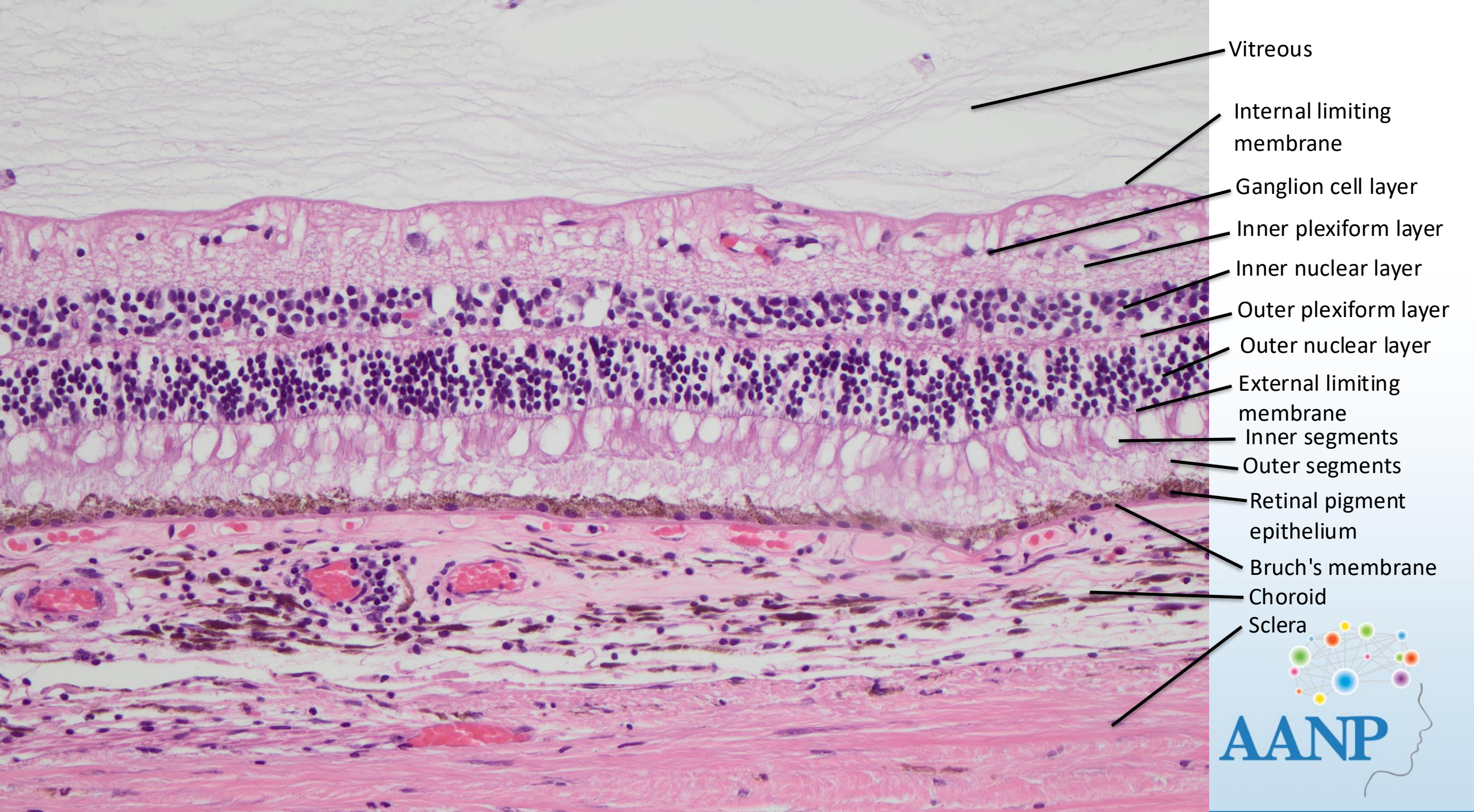
Pars plicata of ciliary body

Ciliary muscle

Ciliary epithelium (pigmented and nonpigmented)

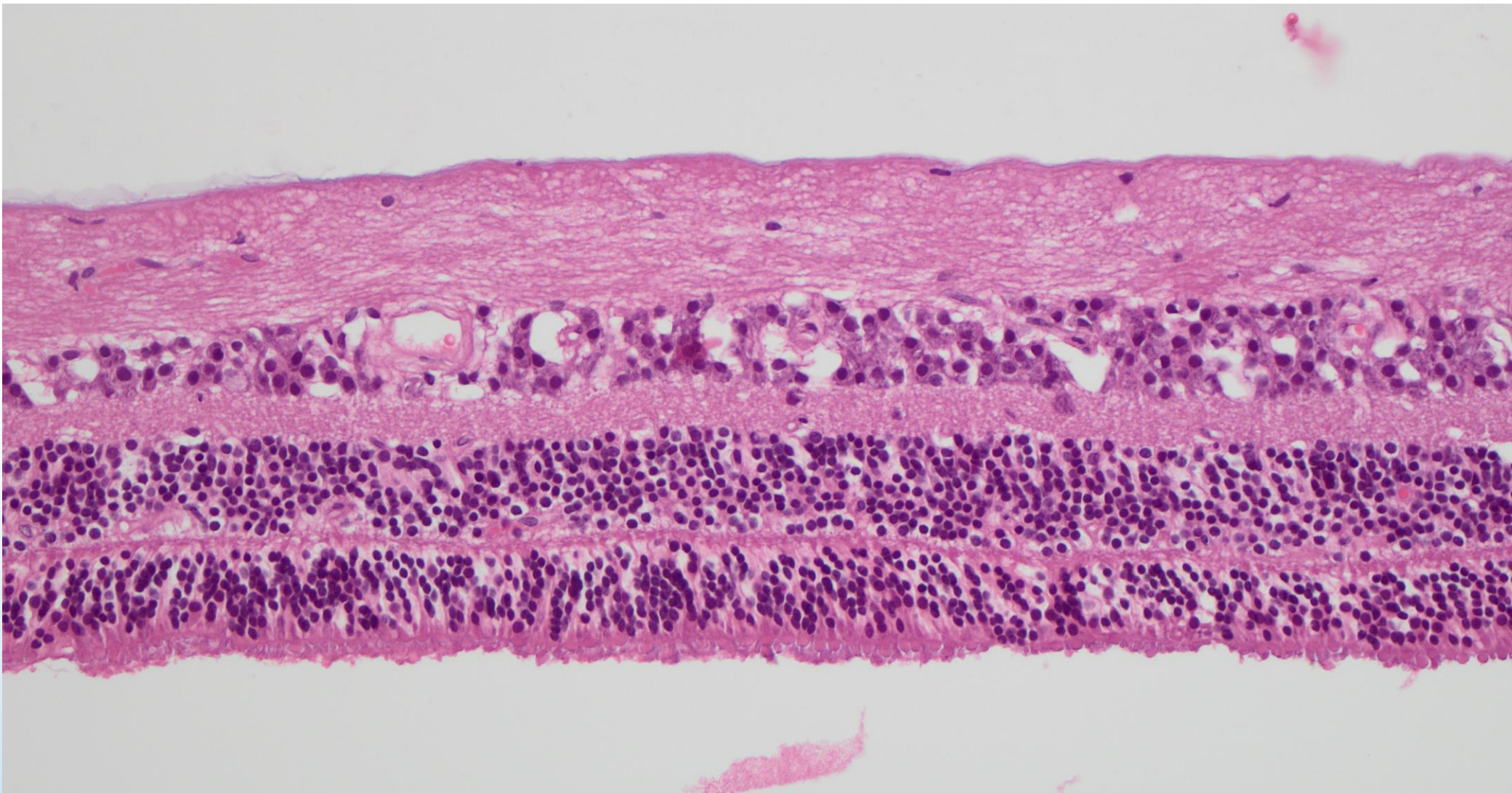
Pars plana of ciliary body

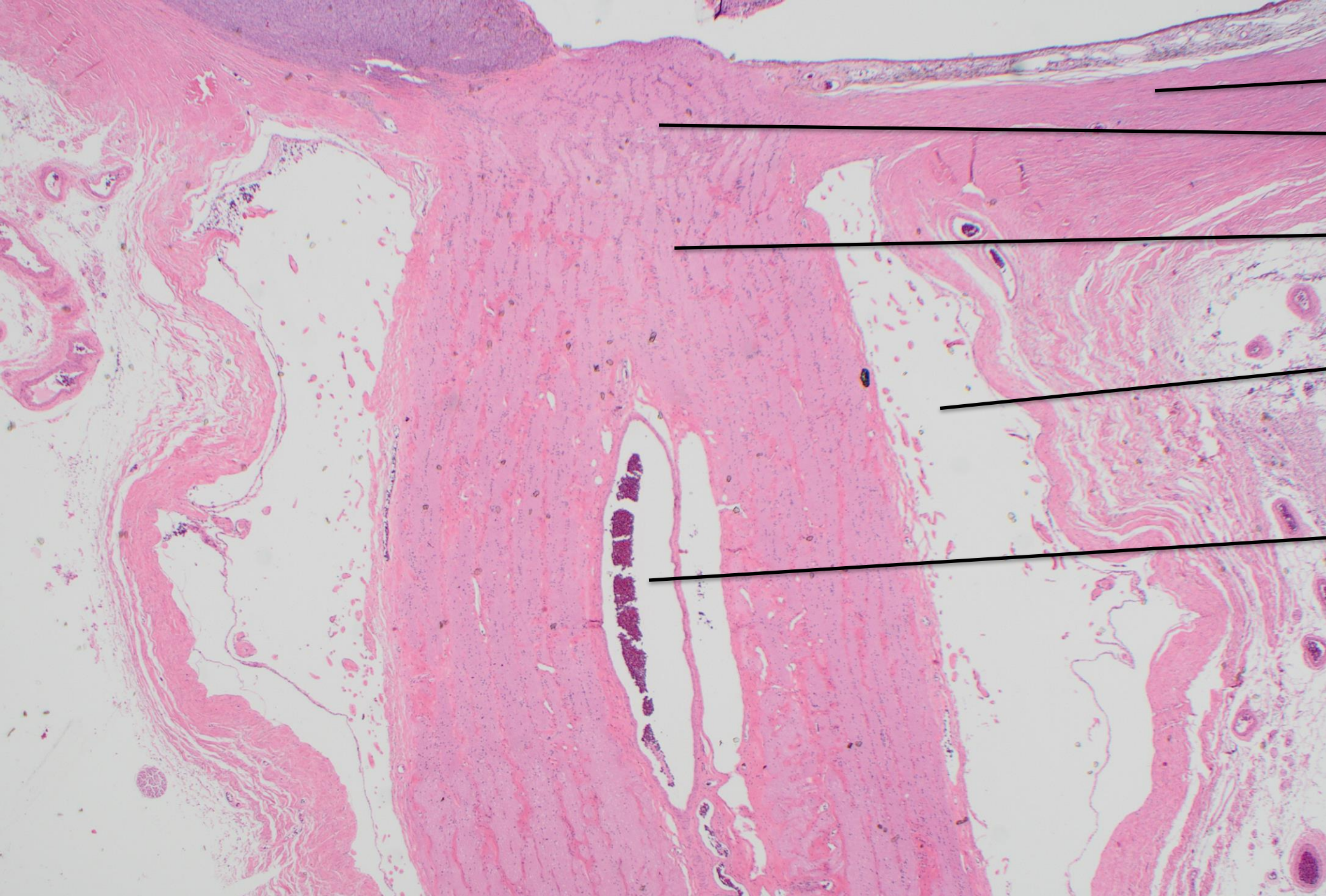




- Vitreous
- Internal limiting membrane
- Ganglion cell layer
- Inner plexiform layer
- Inner nuclear layer
- Outer plexiform layer
- Outer nuclear layer
- External limiting membrane
- Inner segments
- Outer segments
- Retinal pigment epithelium
- Bruch's membrane
- Choroid
- Sclera

Macula: multilayered ganglion cell layer





Sclera

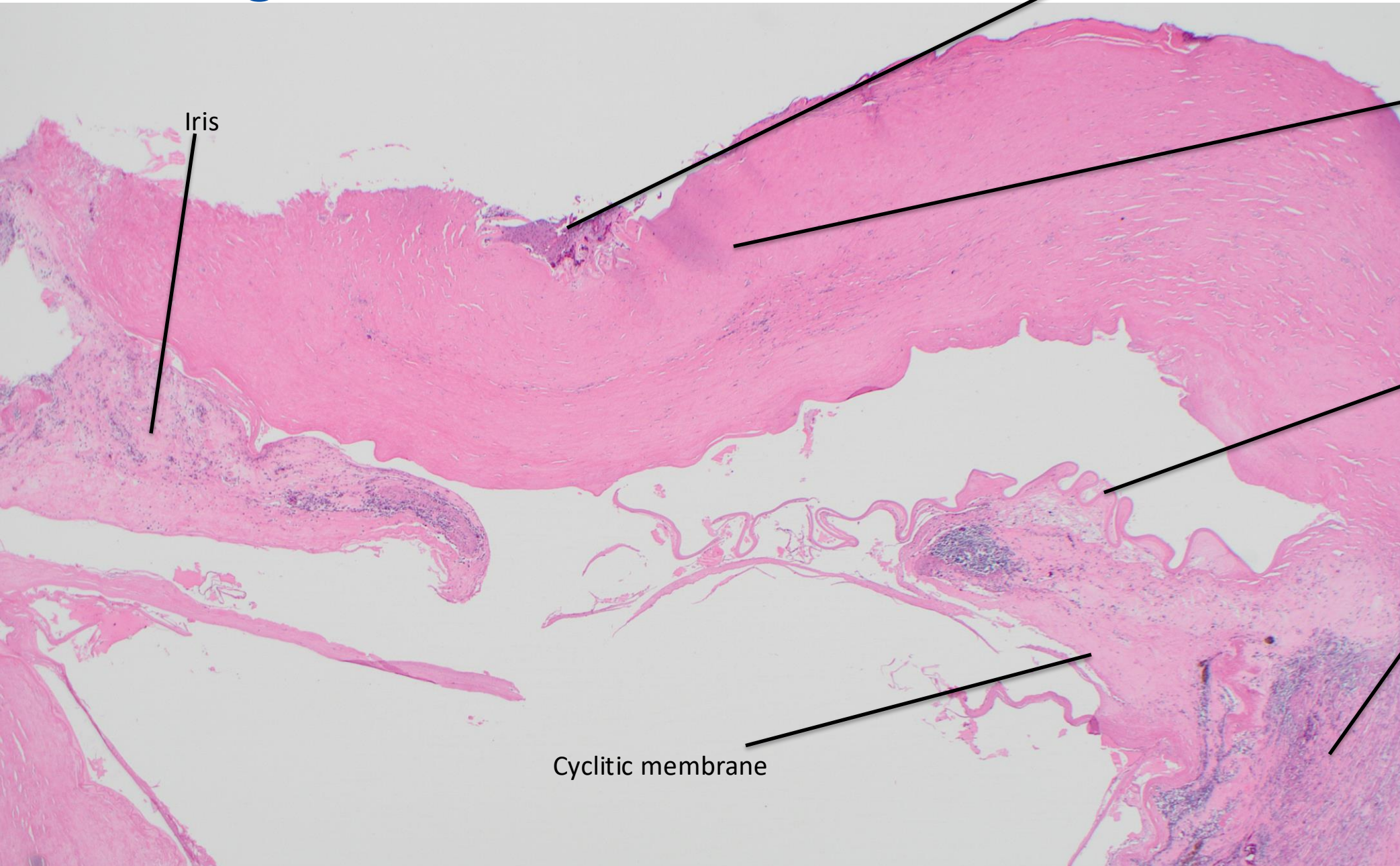
Lamina cribrosa

Optic nerve

Subarachnoid space

Central retinal artery and vein

Returning to Case 3:



Corneal epithelium

Edematous corneal stroma

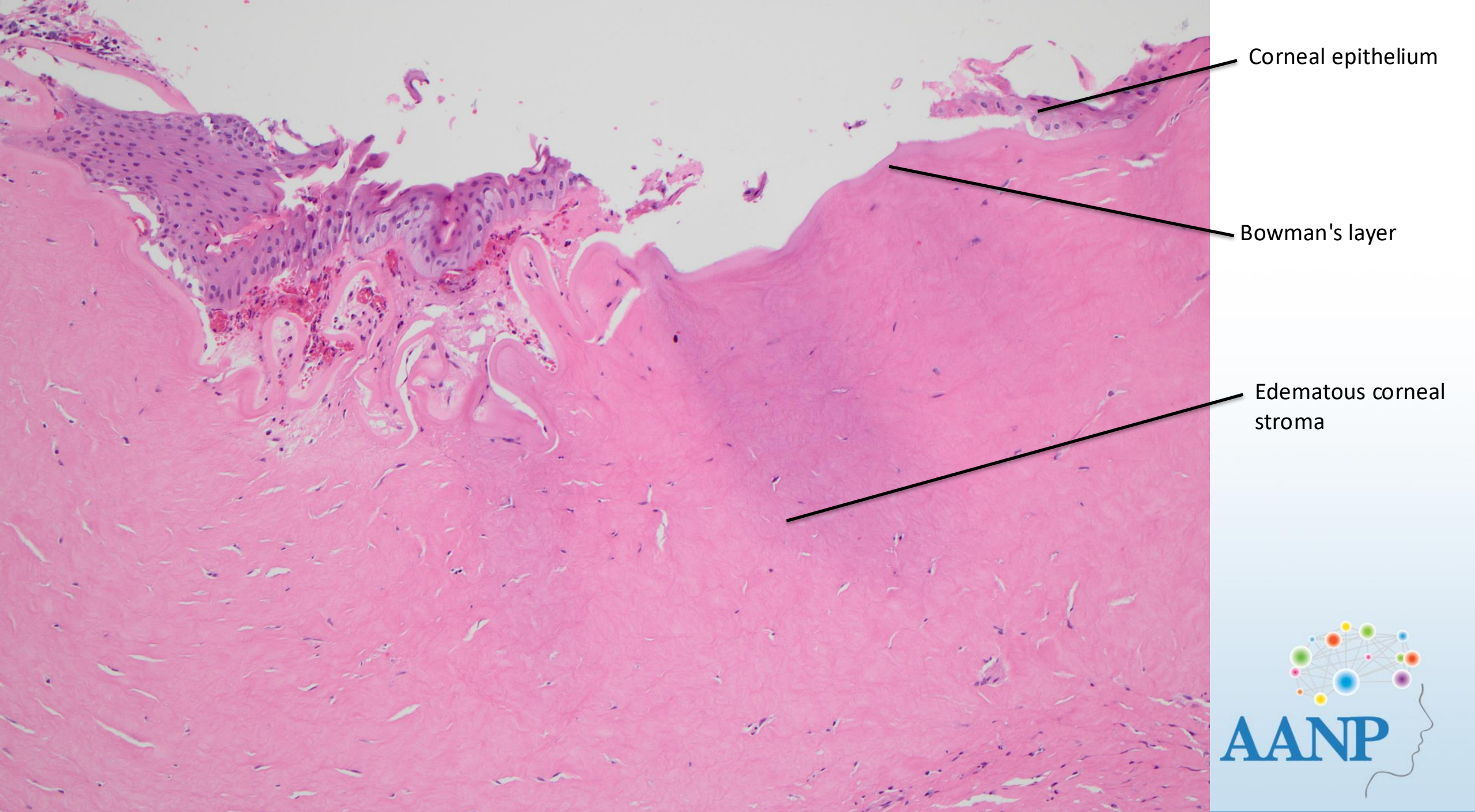
Descemet's membrane

Ciliary body remnants

Cyclitic membrane

Iris

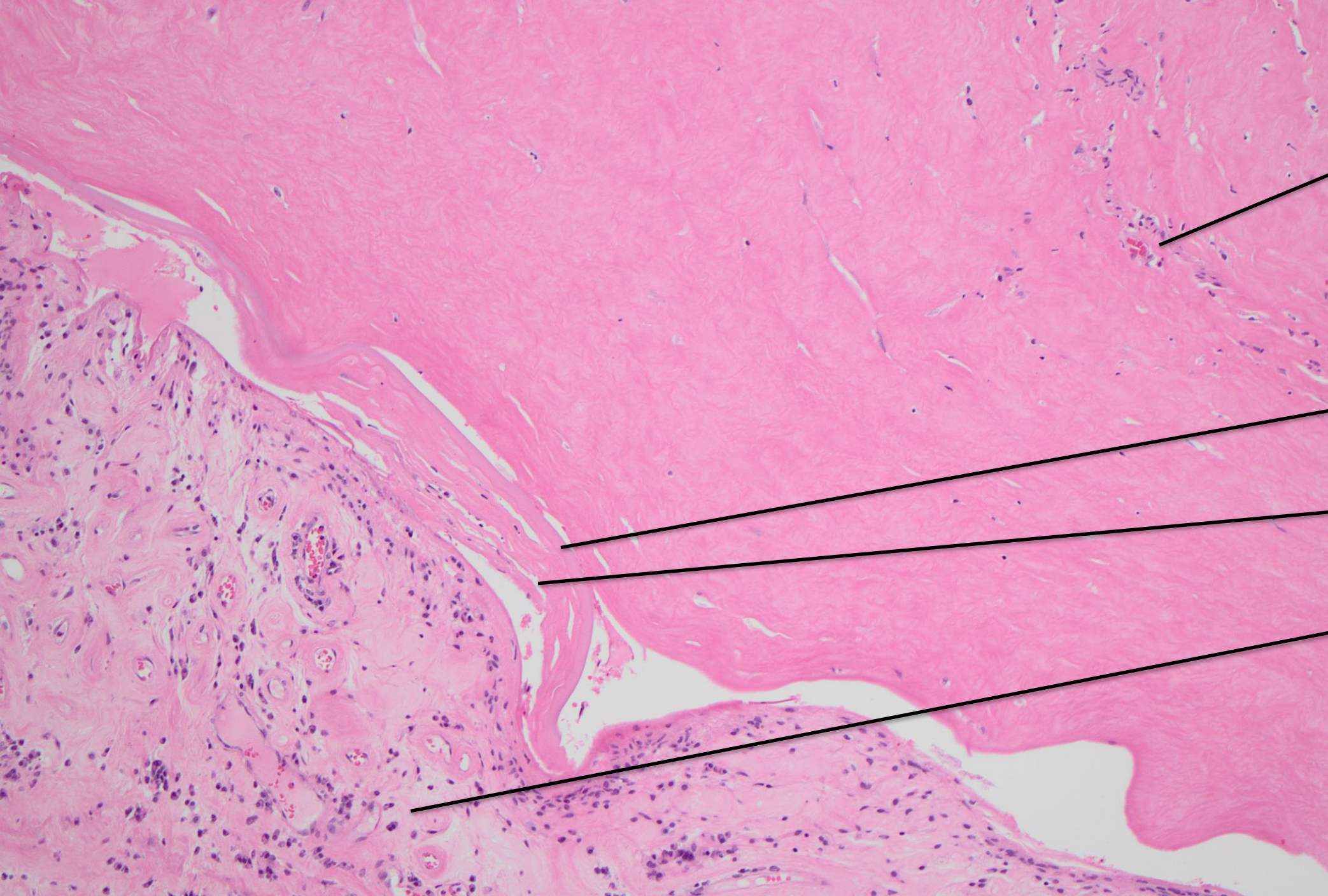




Corneal epithelium

Bowman's layer

Edematous corneal stroma



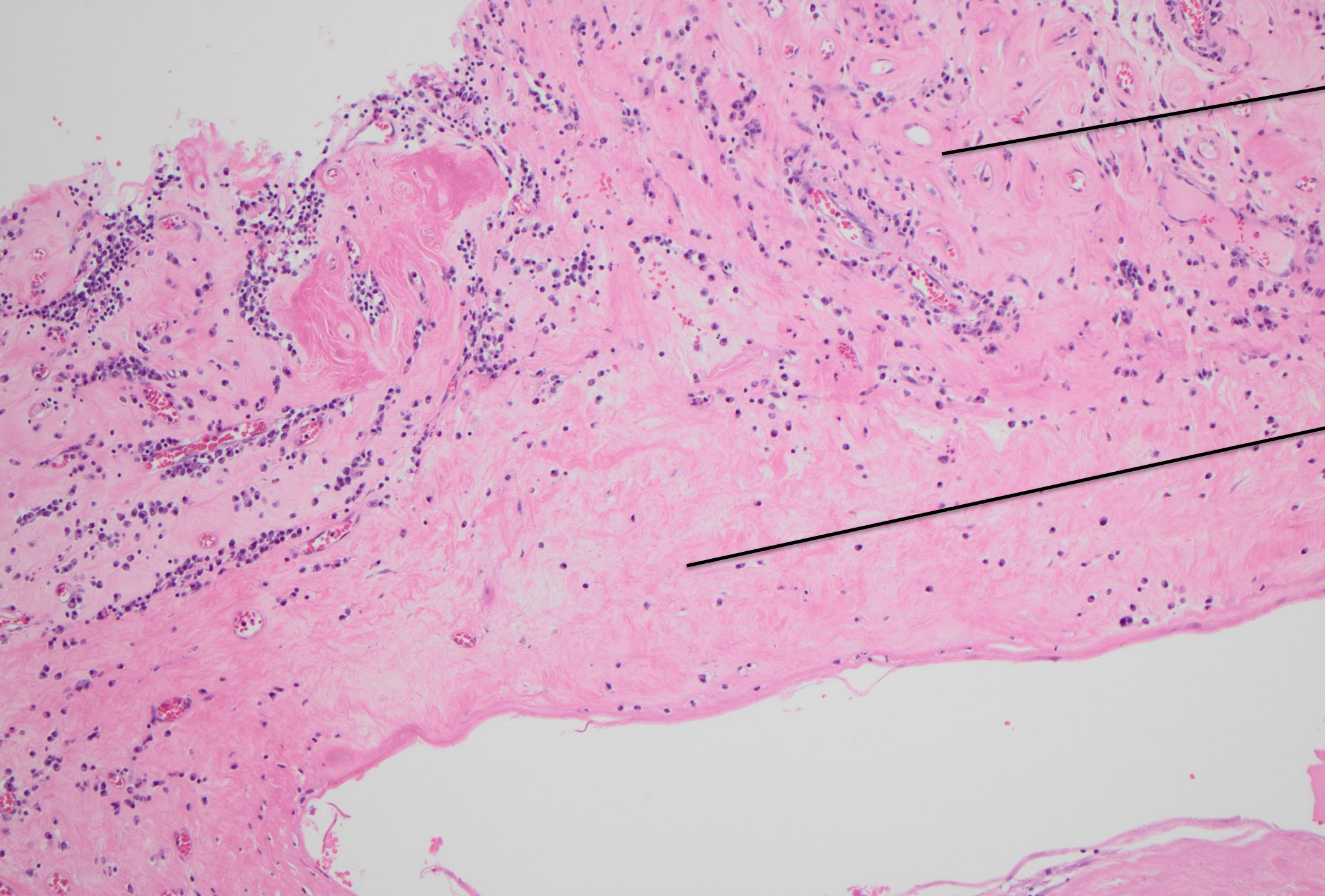
Stromal neovascularization

Descemet's membrane

Retrocorneal fibrous membrane

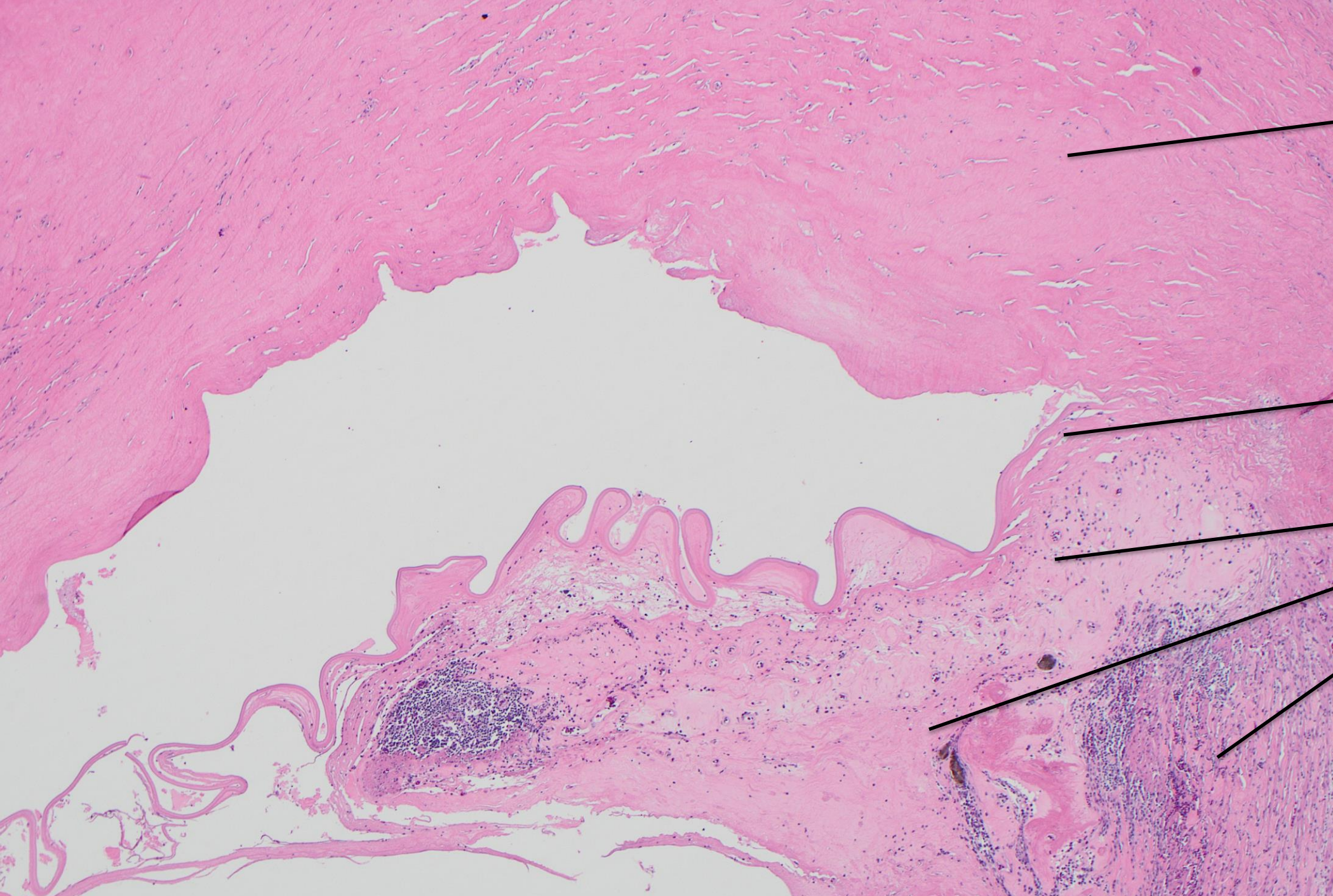
Iris





Iris

Fibrovascular
cyclitic membrane



Edematous corneal stroma

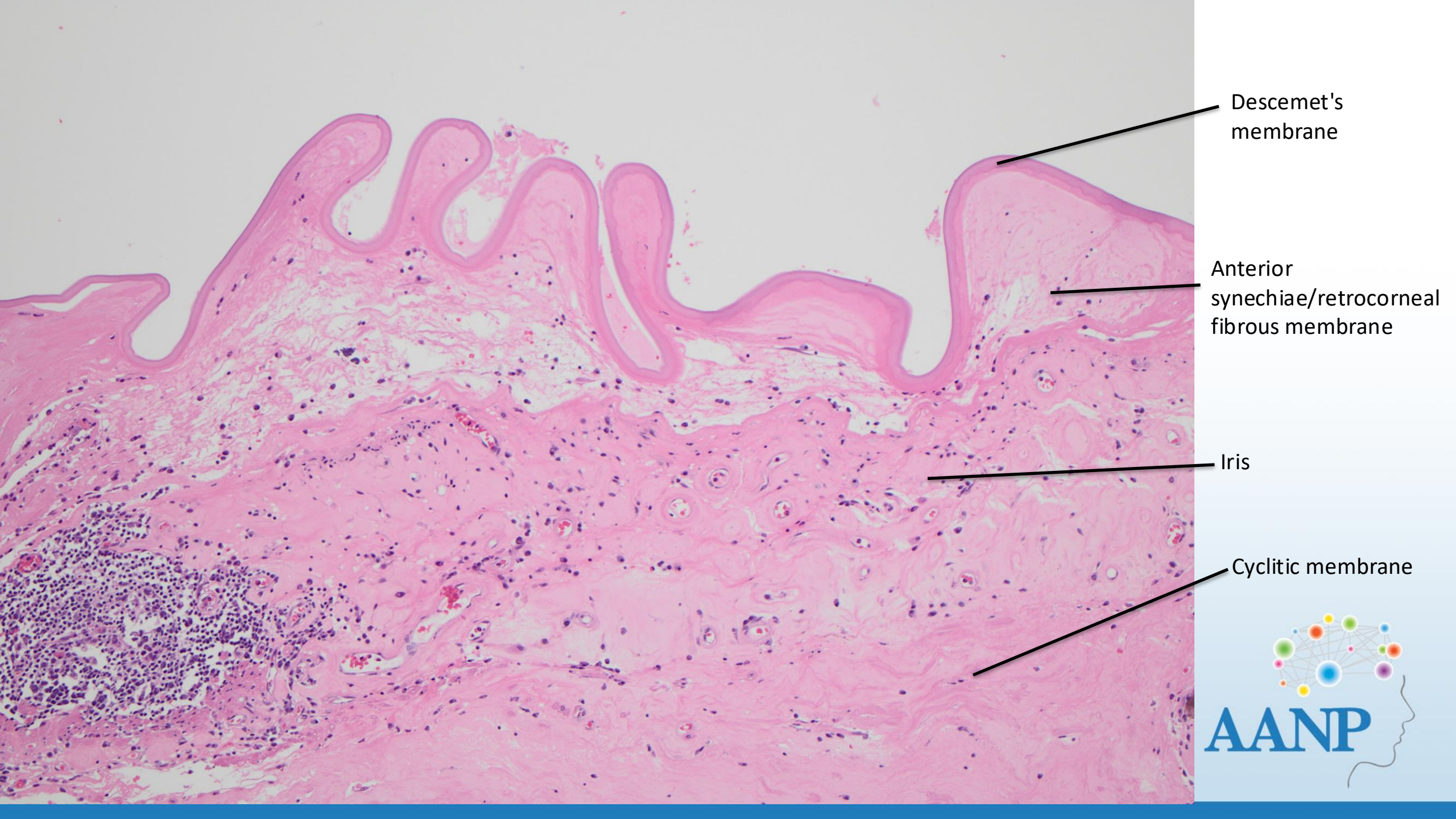
Retrocorneal fibrous membrane/anterior synechiae with angle closure

Iris

Cyclitic membrane

Ciliary body






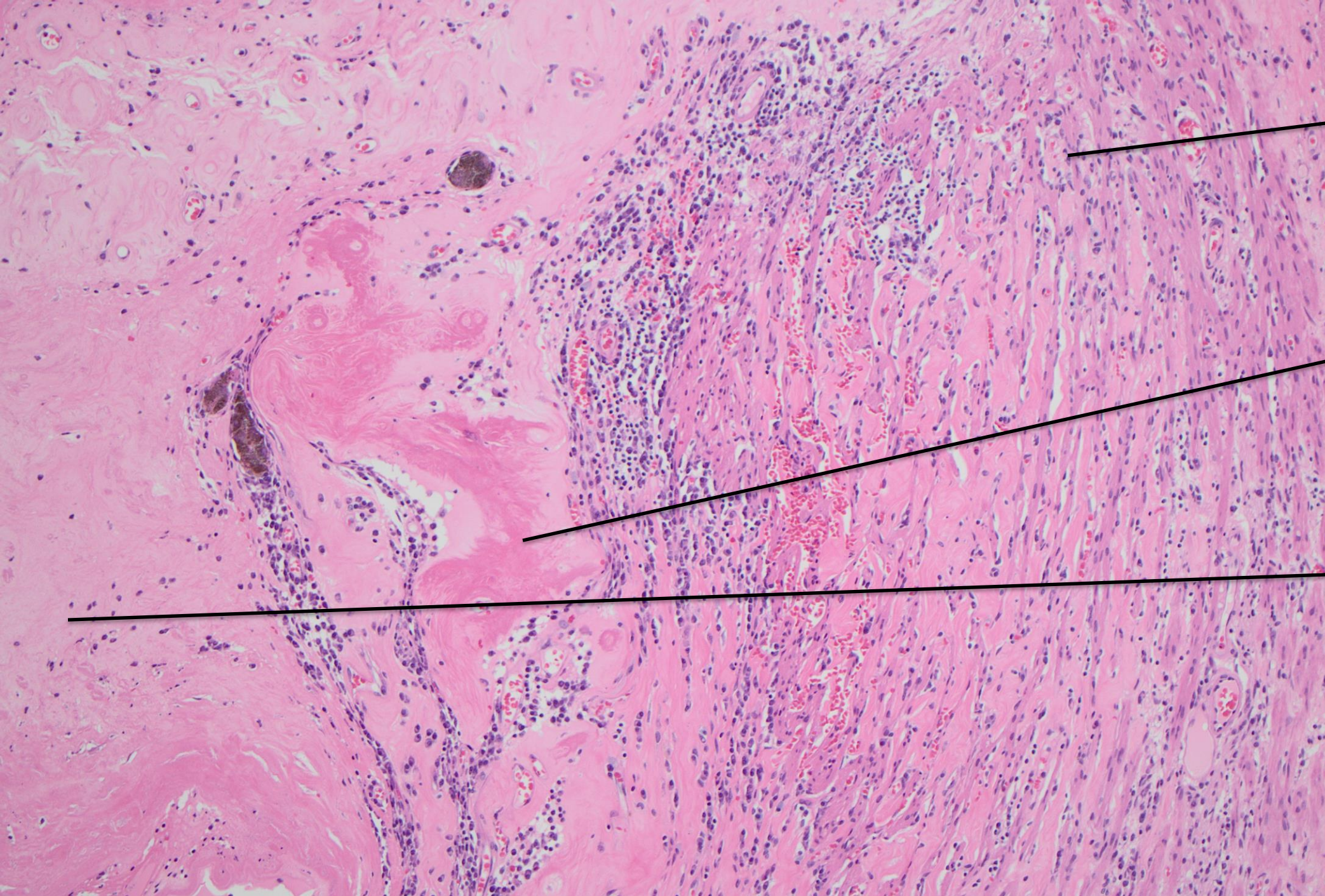
Descemet's
membrane

Anterior
synechia/retrocorneal
fibrous membrane

Iris

Cyclitic membrane

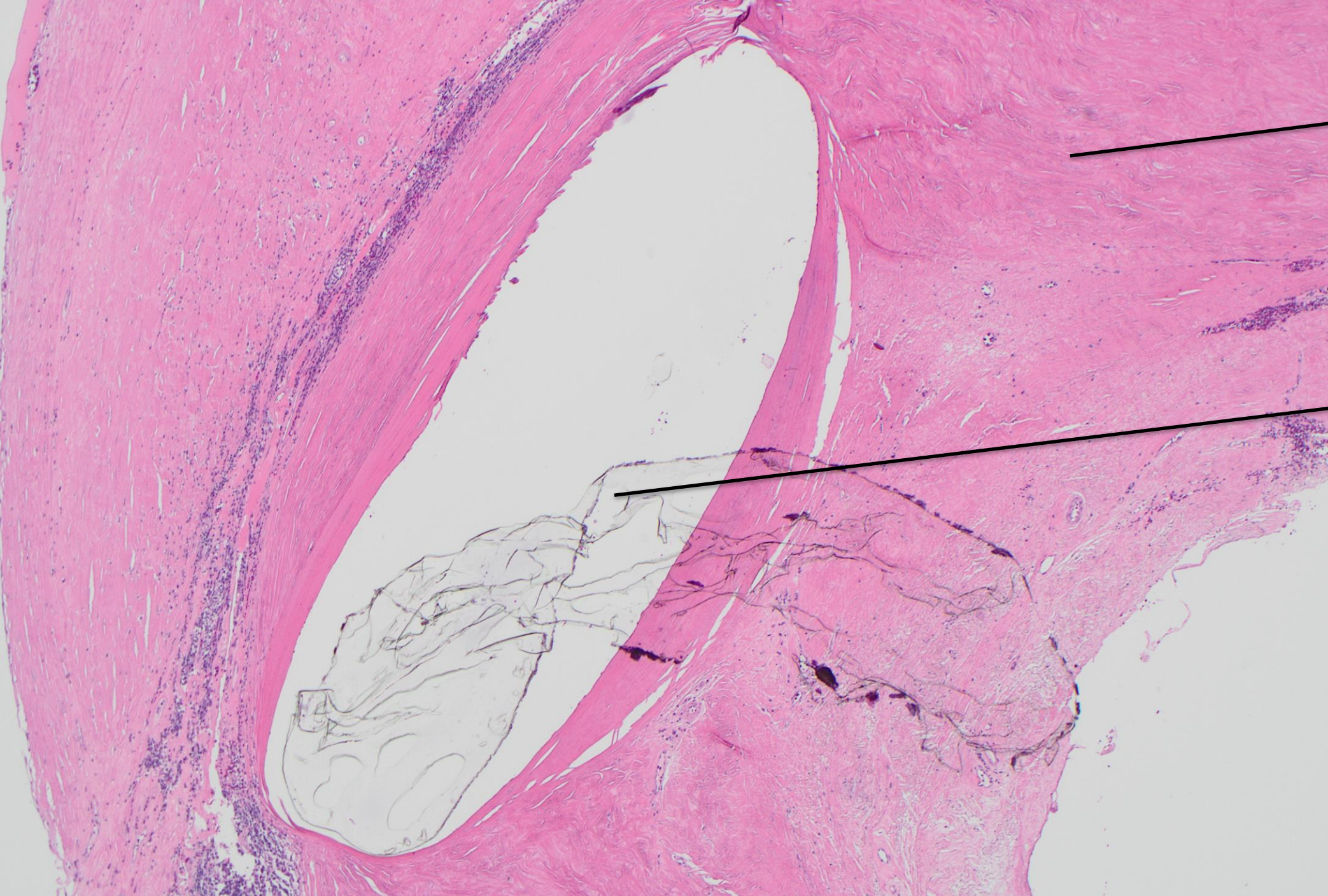




Atrophic ciliary muscle

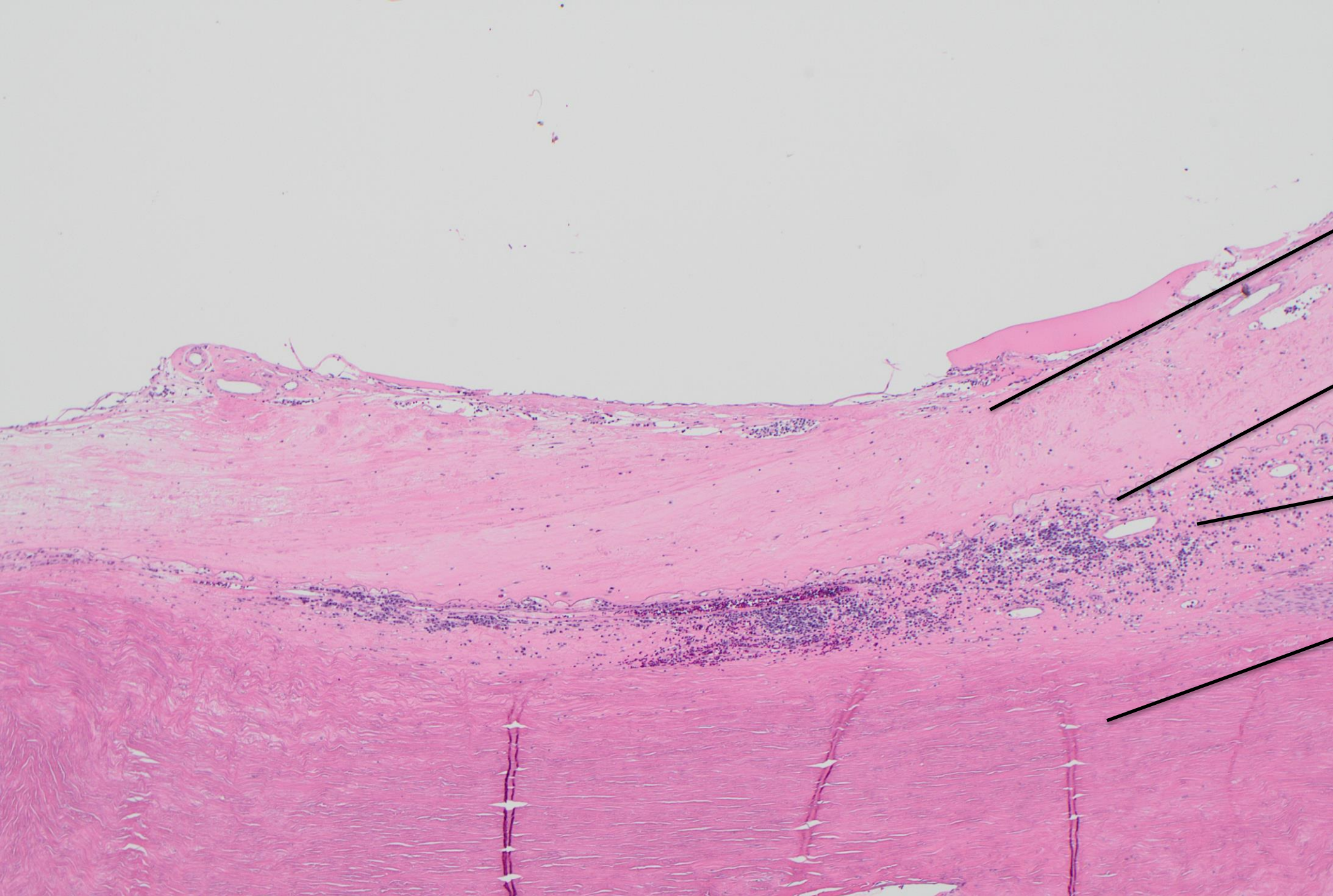
Ciliary body pars plicata remnants

Cyclitic membrane



Sclera

Foreign material
(silicone scleral
buckle band)



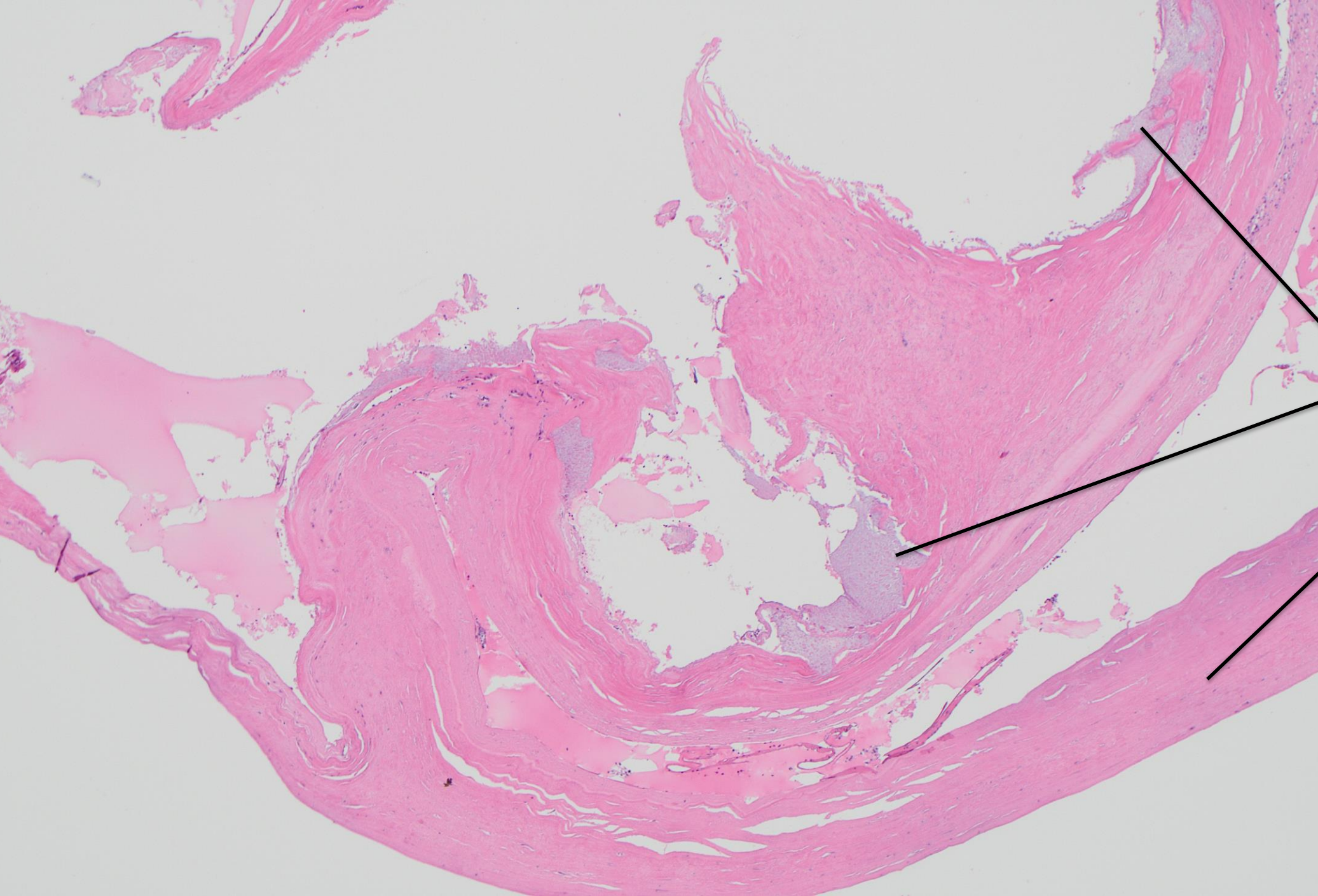
Remnants of retina
and fibrous tissue

Bruch's membrane

Remnant of choroid

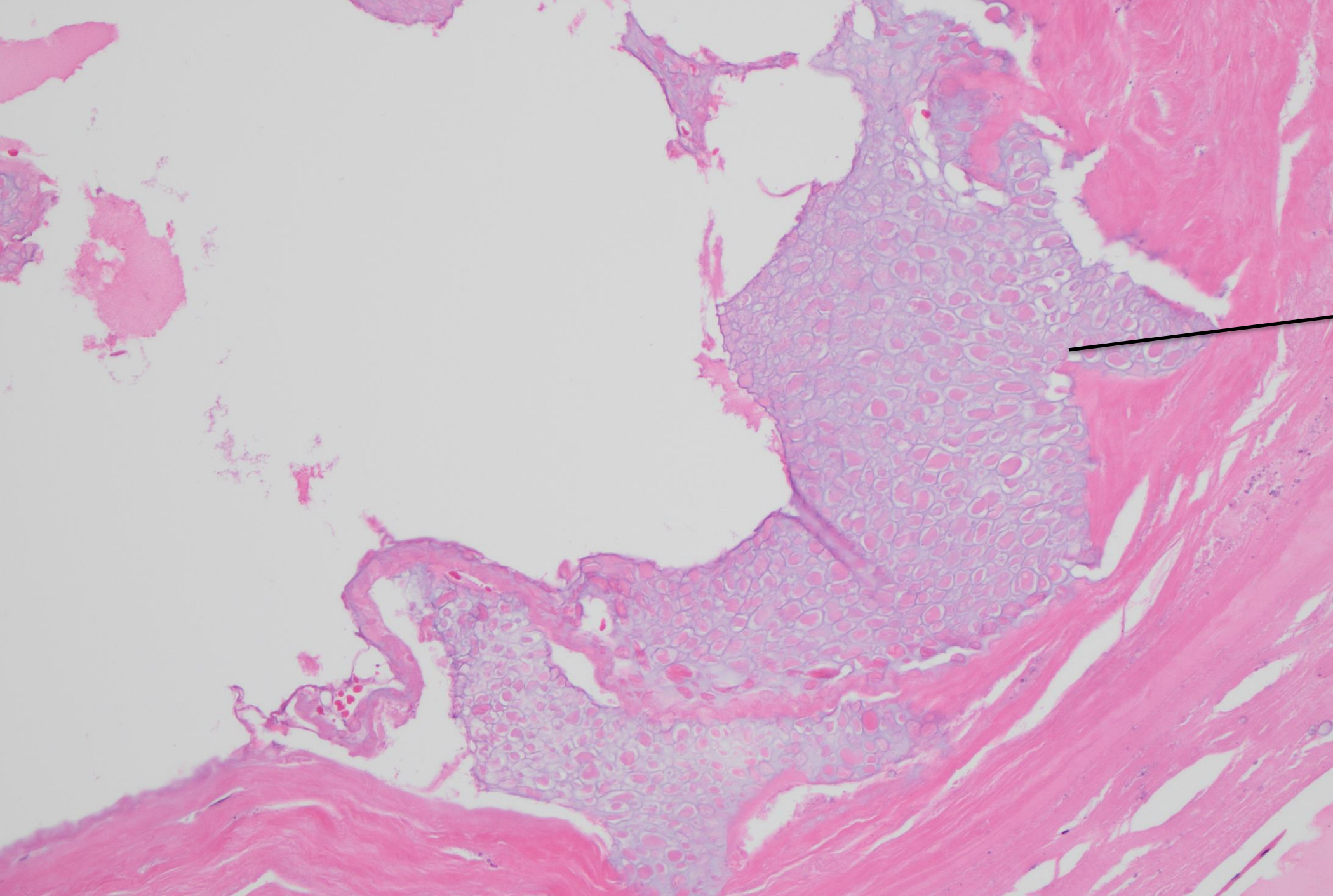
Sclera





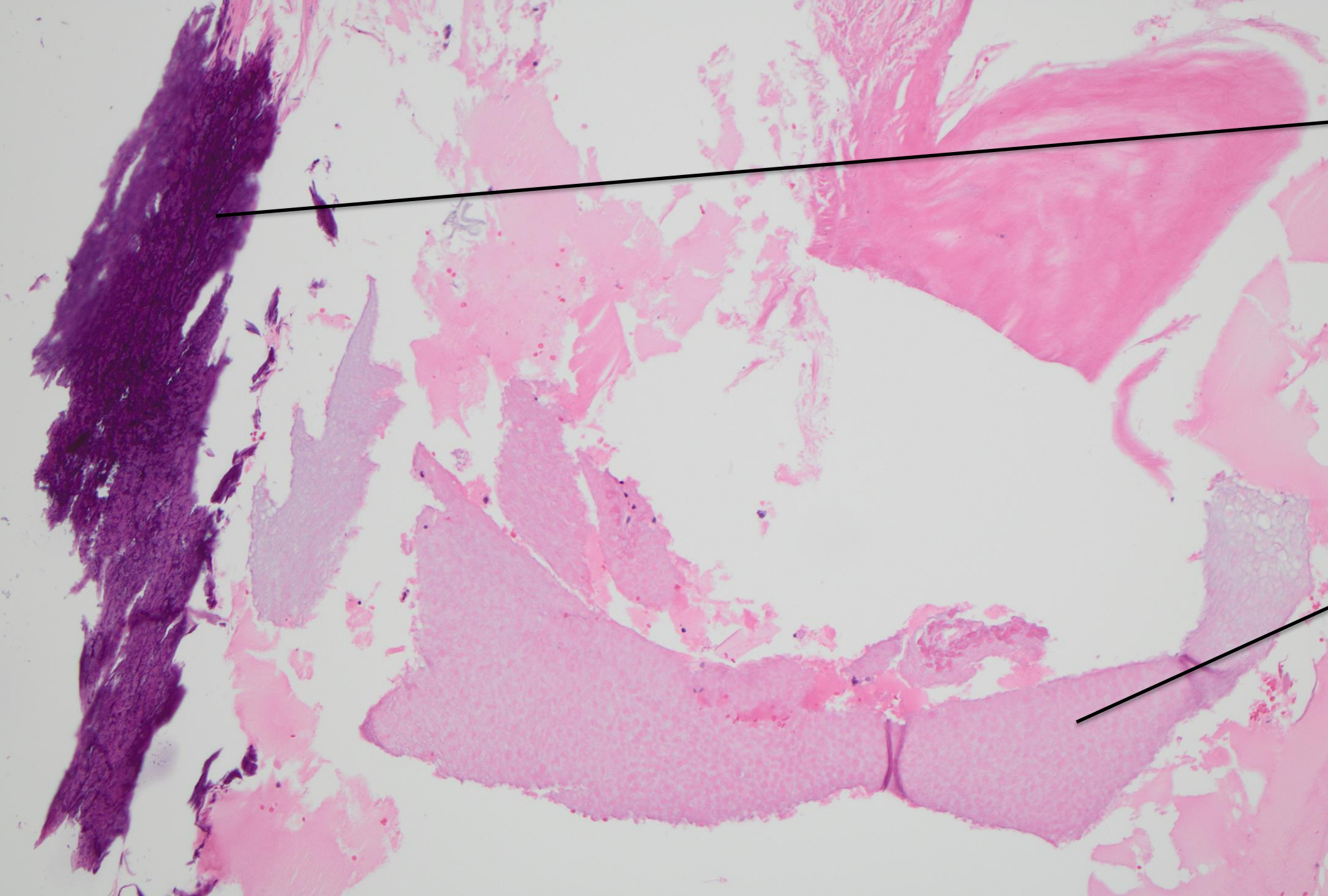
Foreign material

Sclera



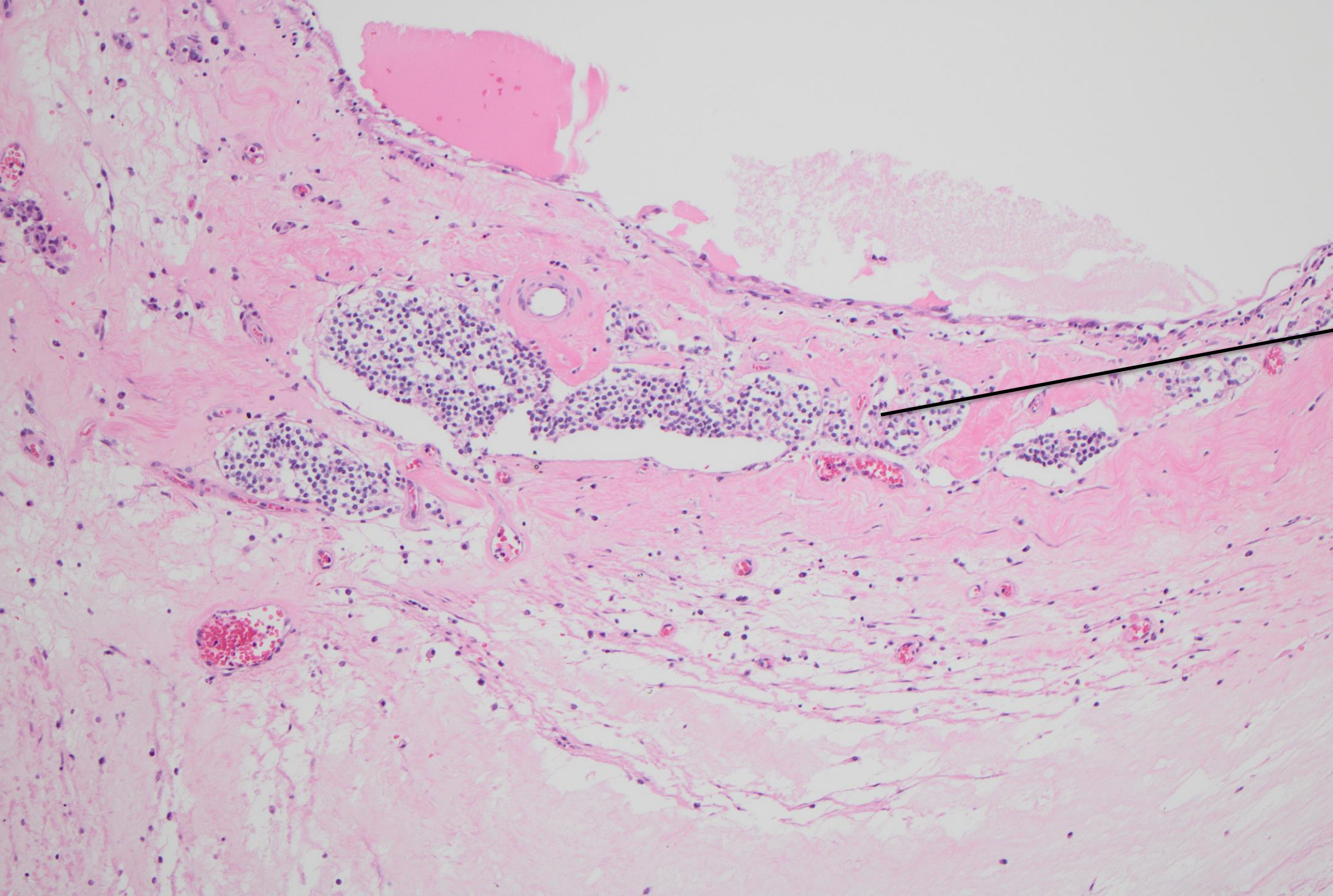
Foreign material






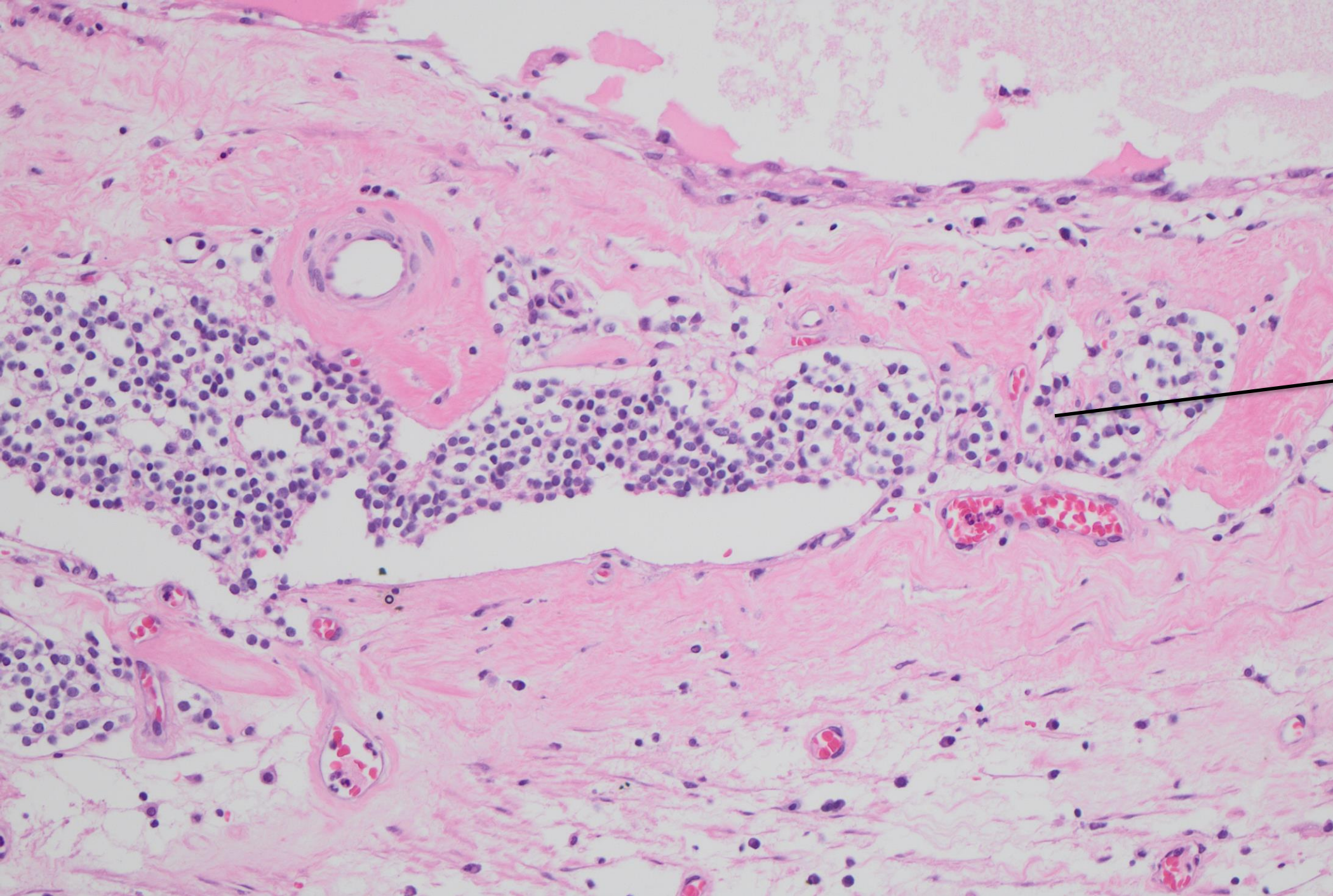
Calcium

Foreign material



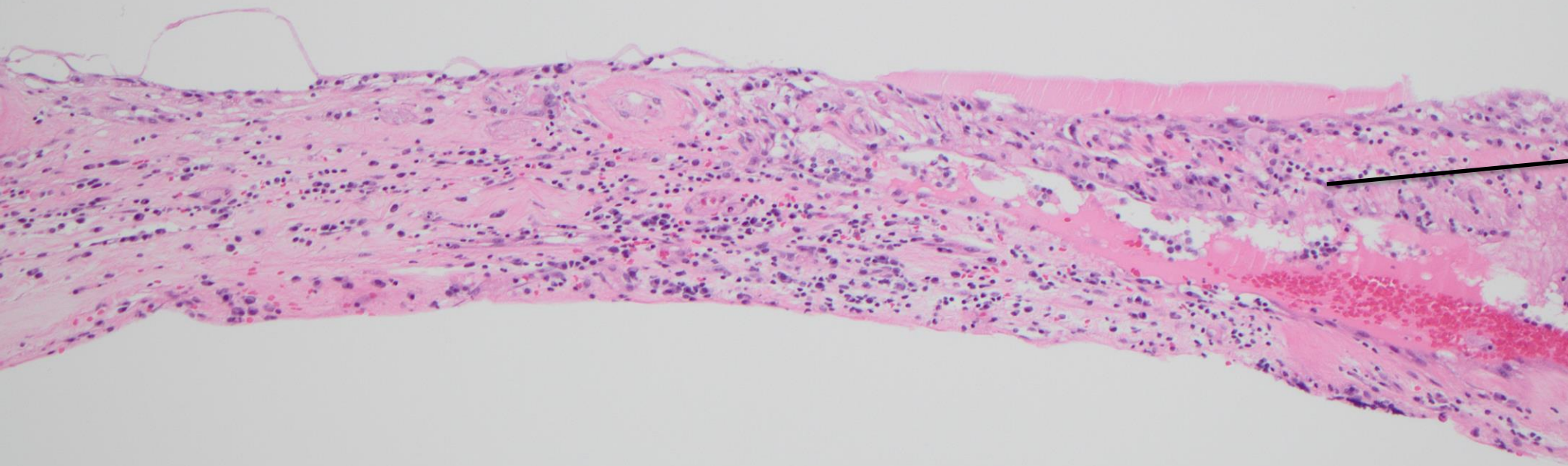
Remnants of retina






Remnants of retina

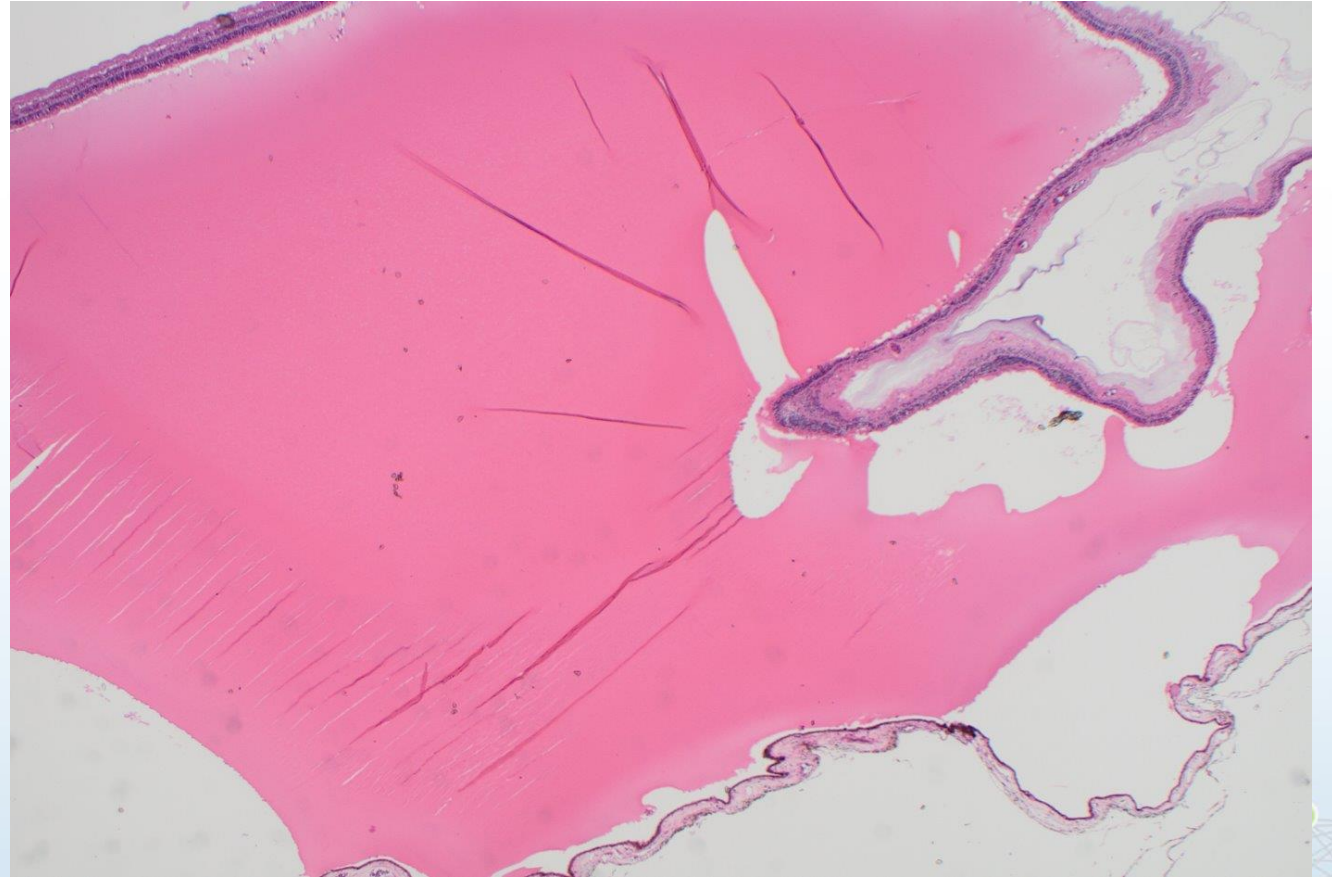
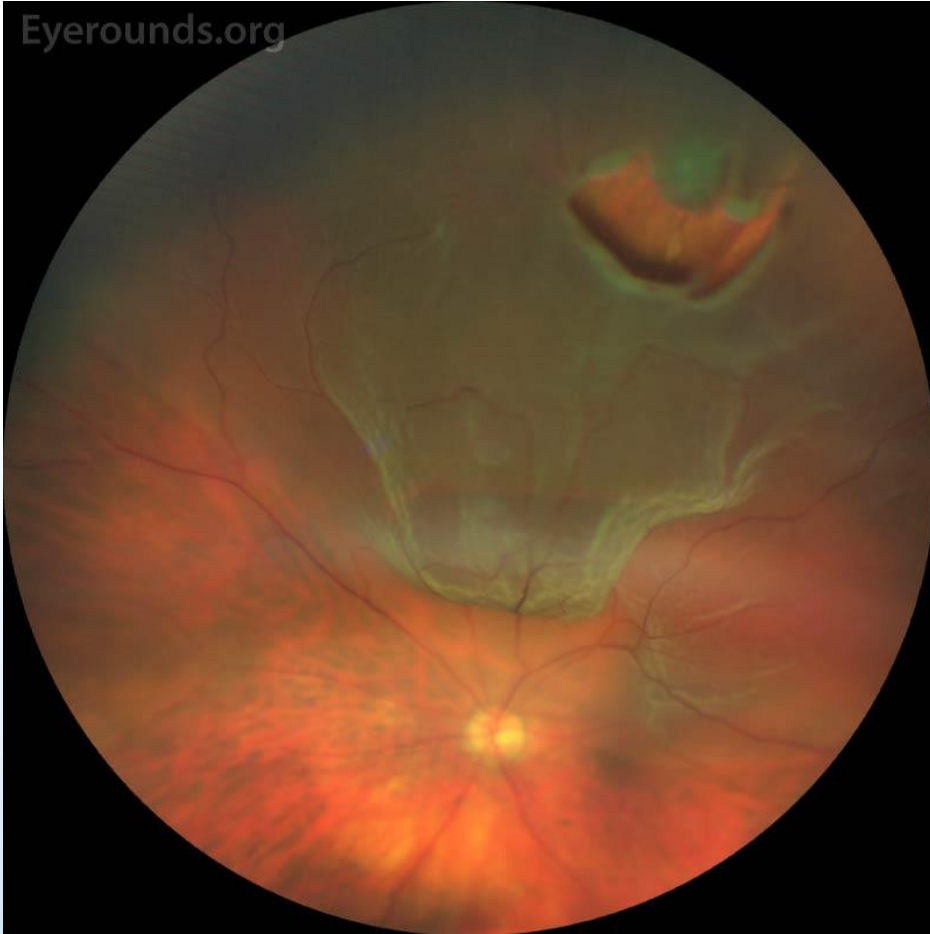



Remnants of retina



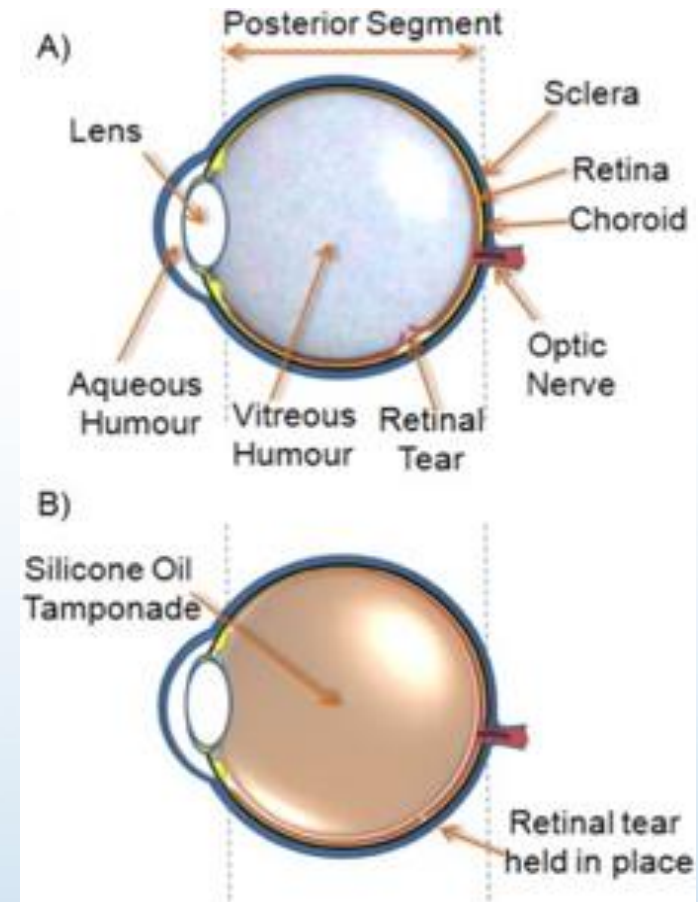
Retinal detachment repairs



<https://webeye.ophth.uiowa.edu/eyeforum/atlas/pages/Rhegmatogenous-ret-detach.htm#gsc.tab=0>

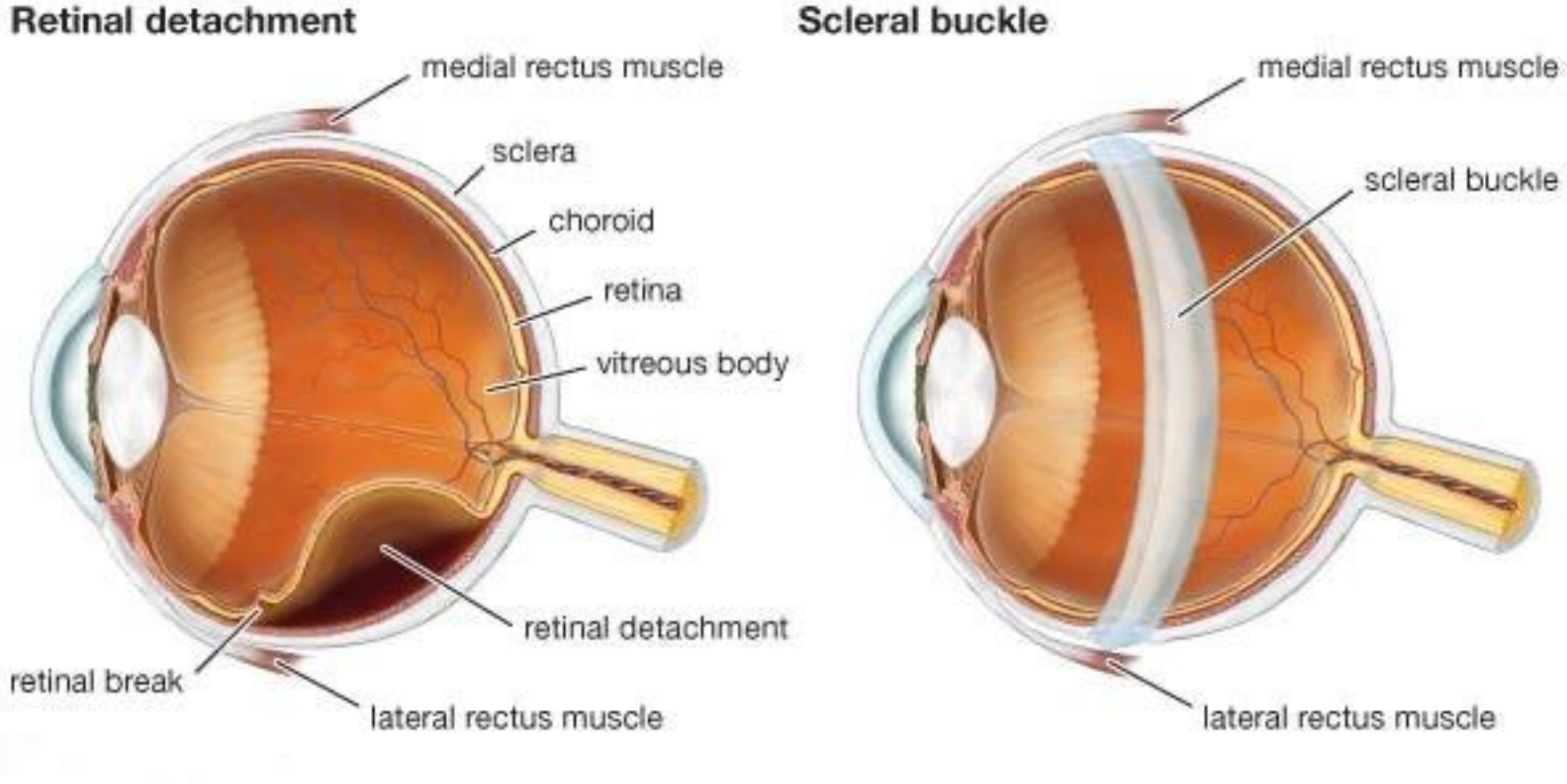
Retinal detachment repair options

- Scleral buckle
 - Silicone
 - Hydrogel
- Vitrectomy with laser and then fill eye with material
 - Air
 - Silicone oil




<https://ars.els-cdn.com/content/image/1-s2.0-S0168365916305946-gr1.jpg>

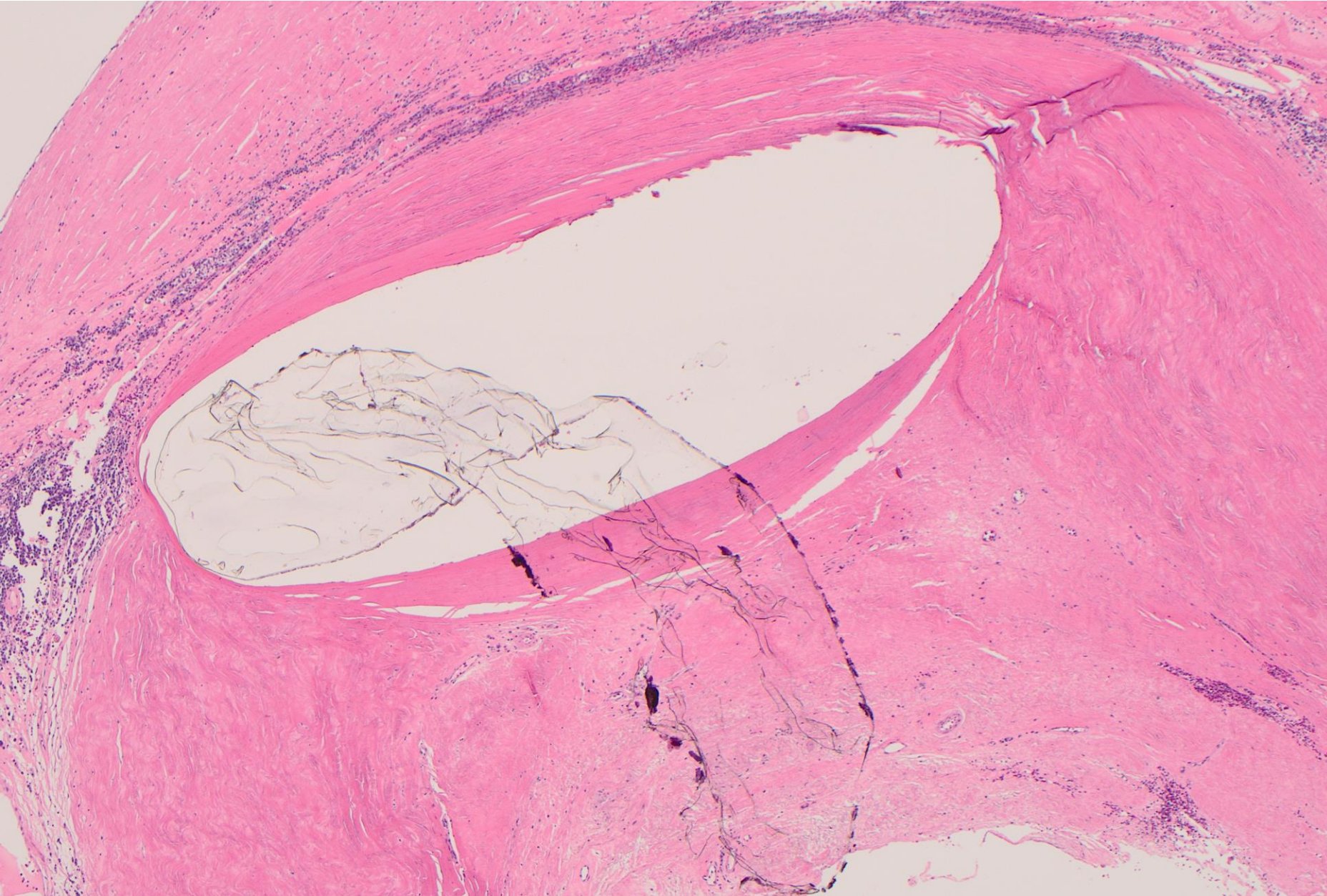
Retinal Detachment Repair – Scleral Buckle



<https://retinacentersd.com/wp-content/uploads/2024/08/9-2.png>



Silicone Scleral Buckle



Hydrogel Scleral Buckle

Implanted in 1990s

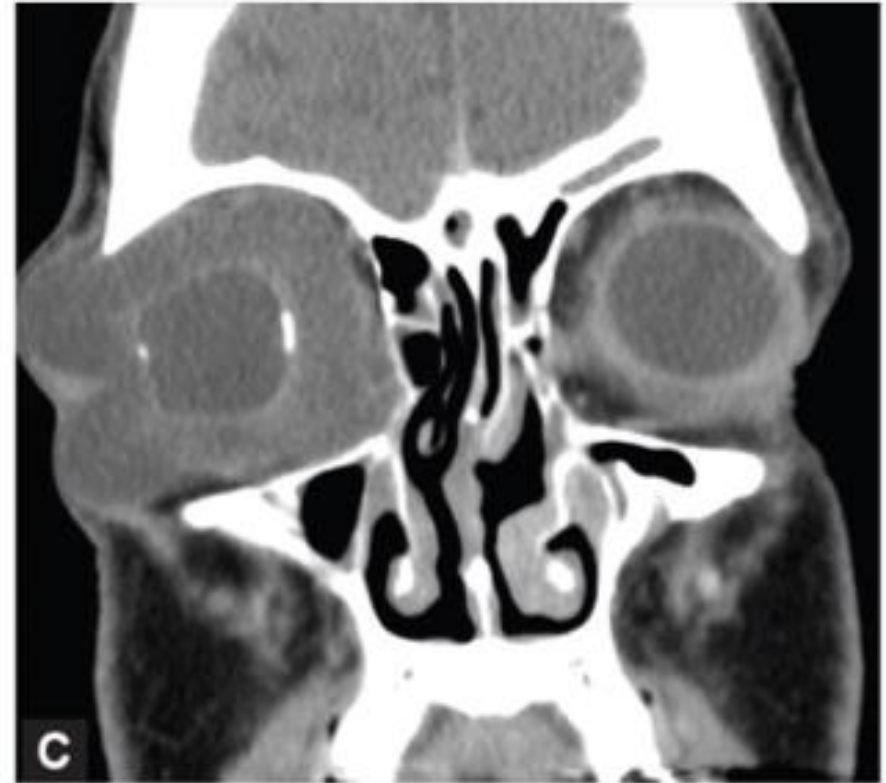
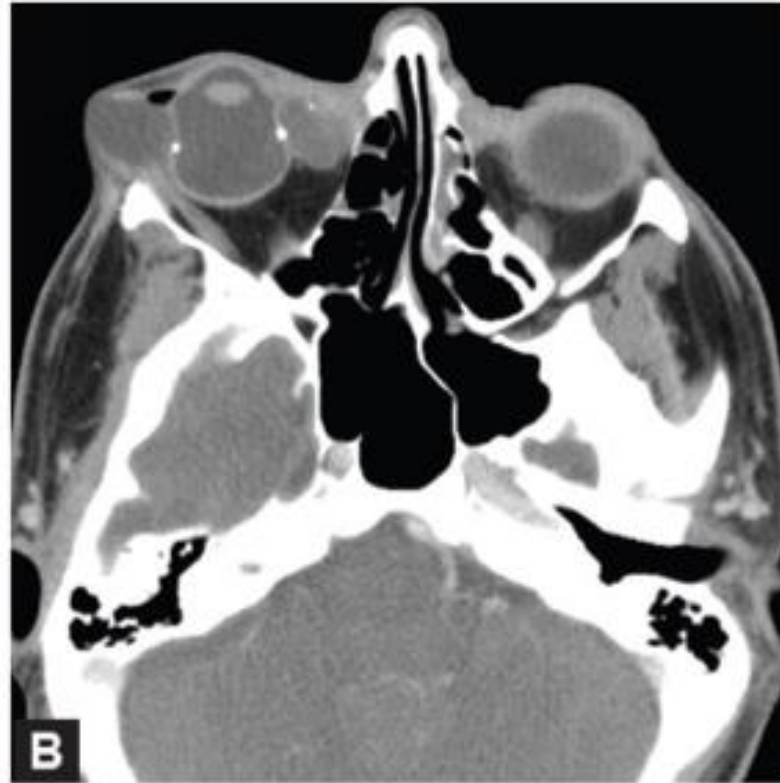
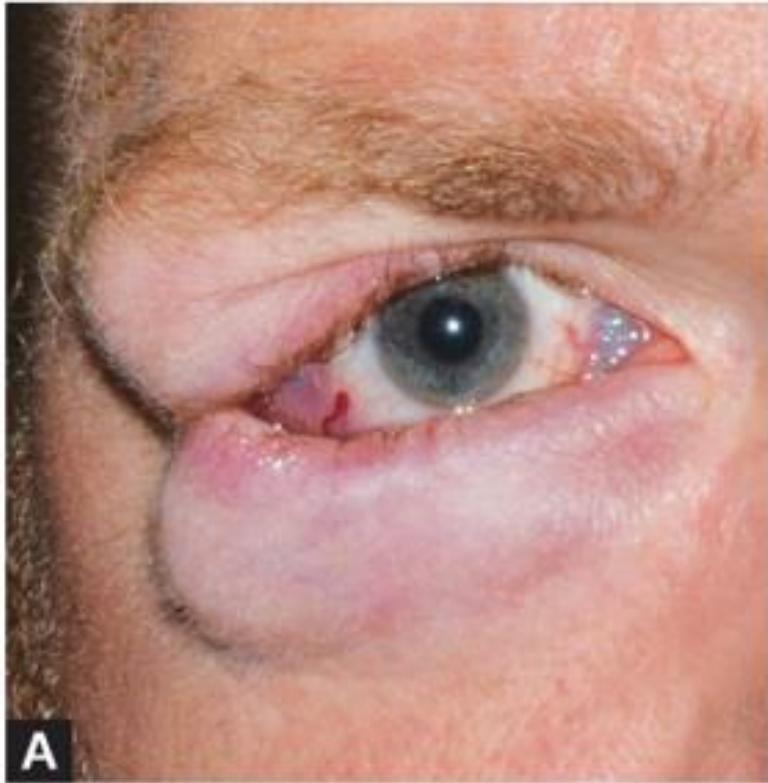Taken off market and no longer used due to complications

- implant expansion/hydrolysis years after implantation**
- implant erosion into eyeball**

Implants are still being removed

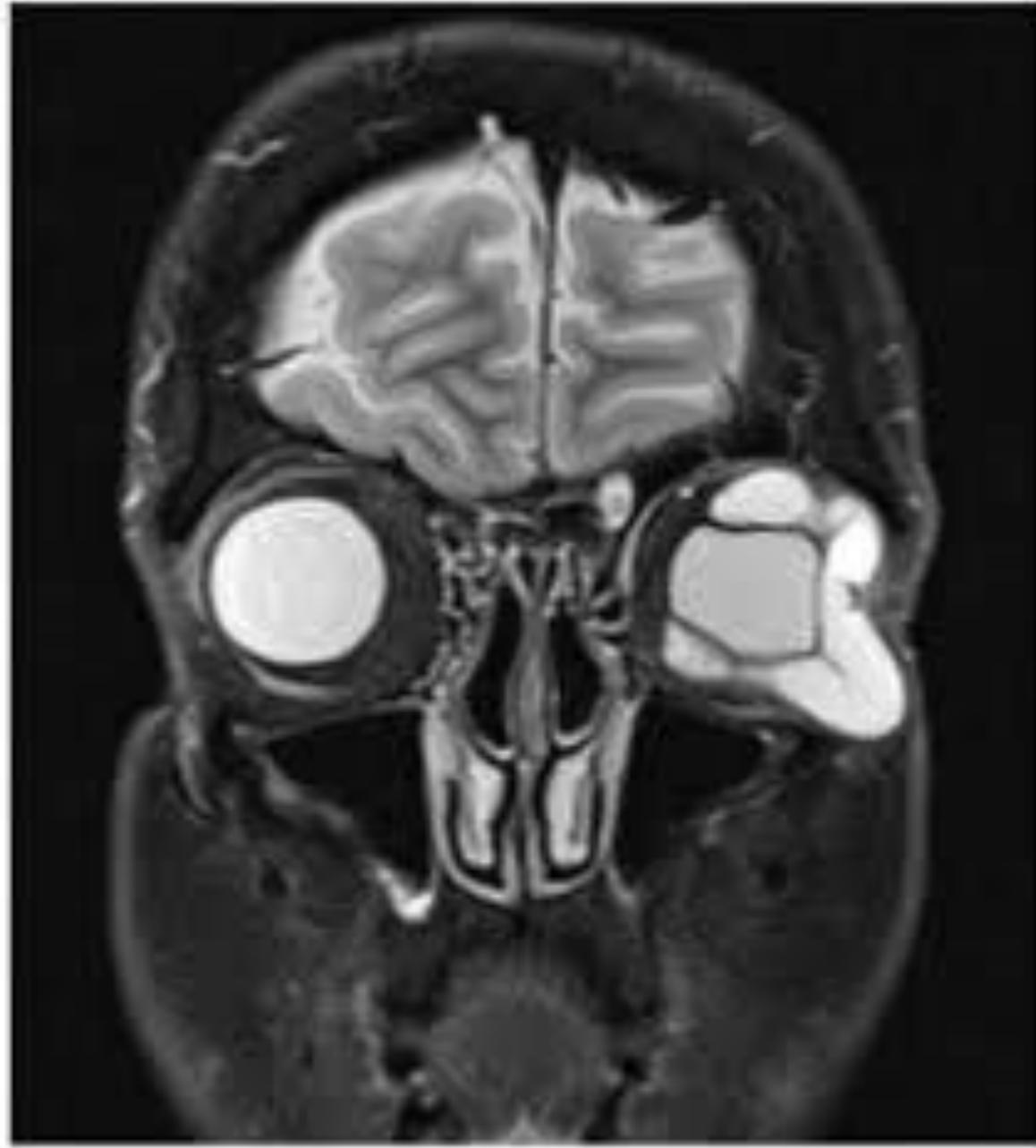

Hydrolyzed hydrogel scleral buckle



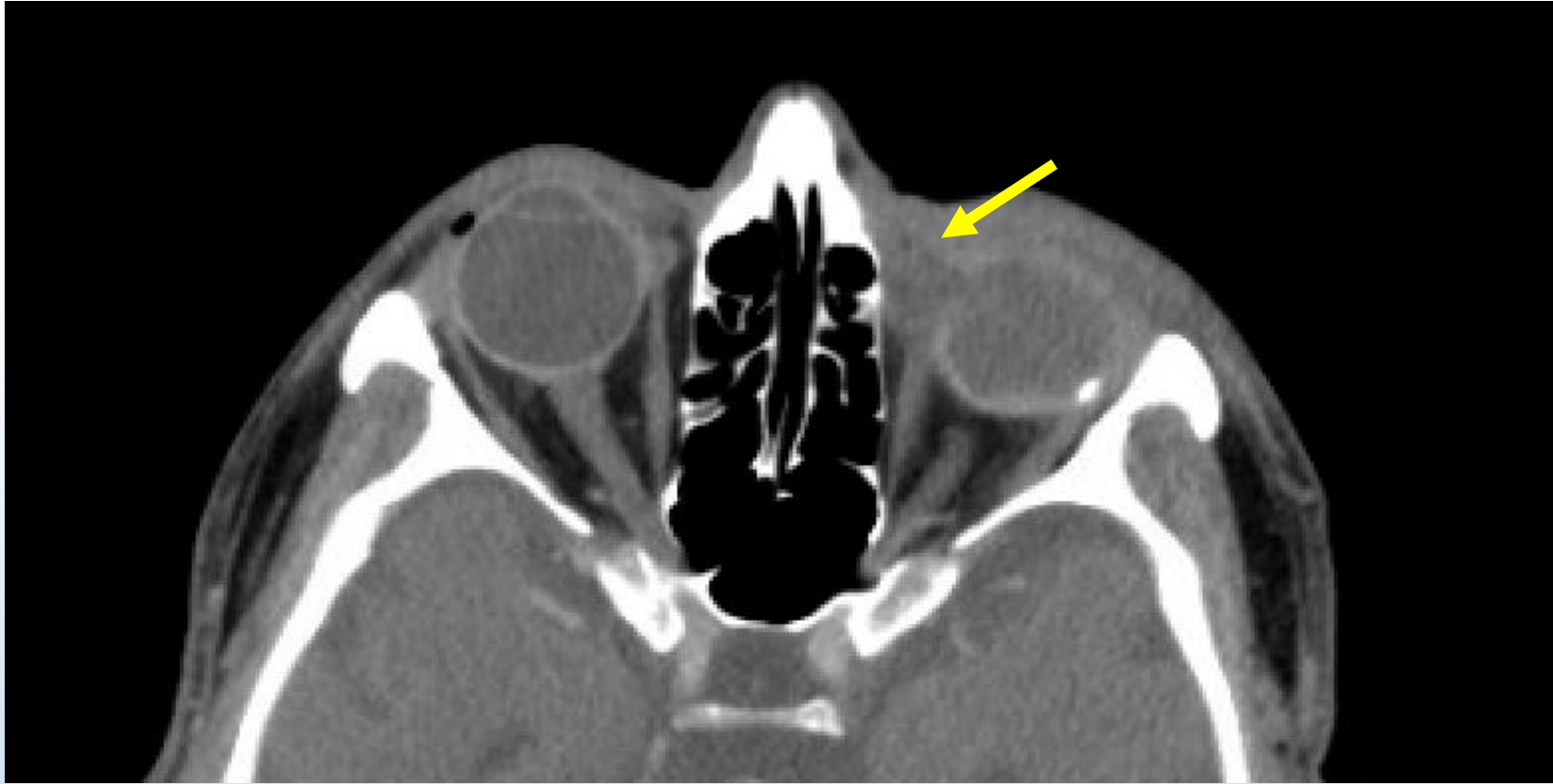
Peyman's Principles and Practice of Ophthalmology, 2019

Expanded Hydrogel Scleral Buckle

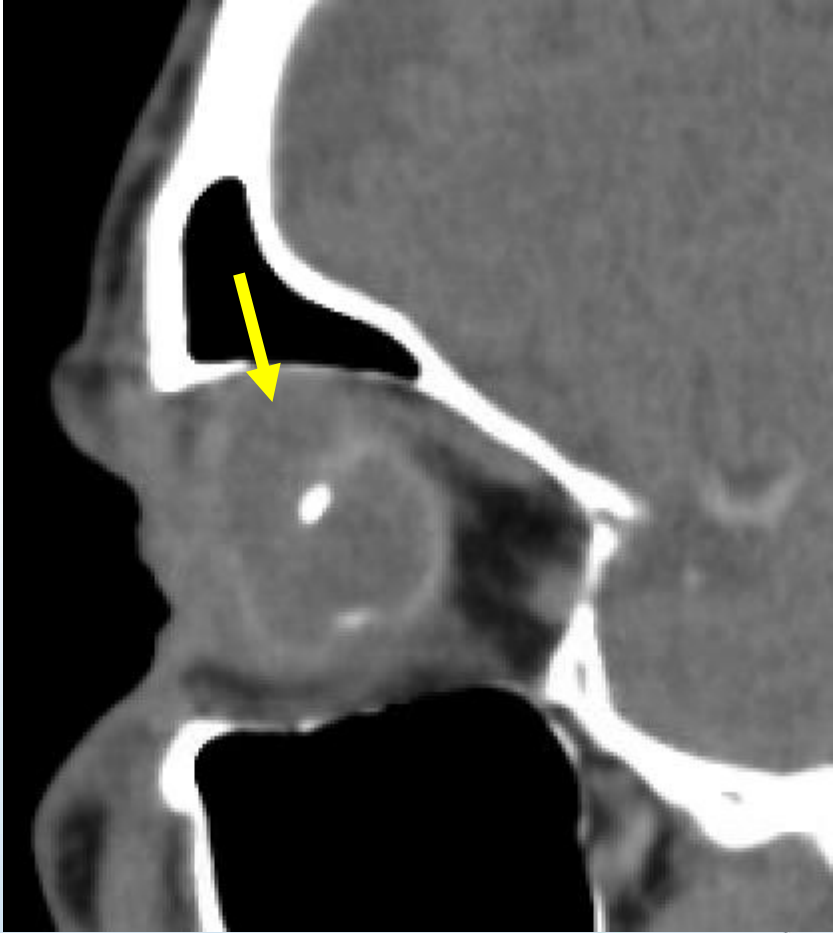
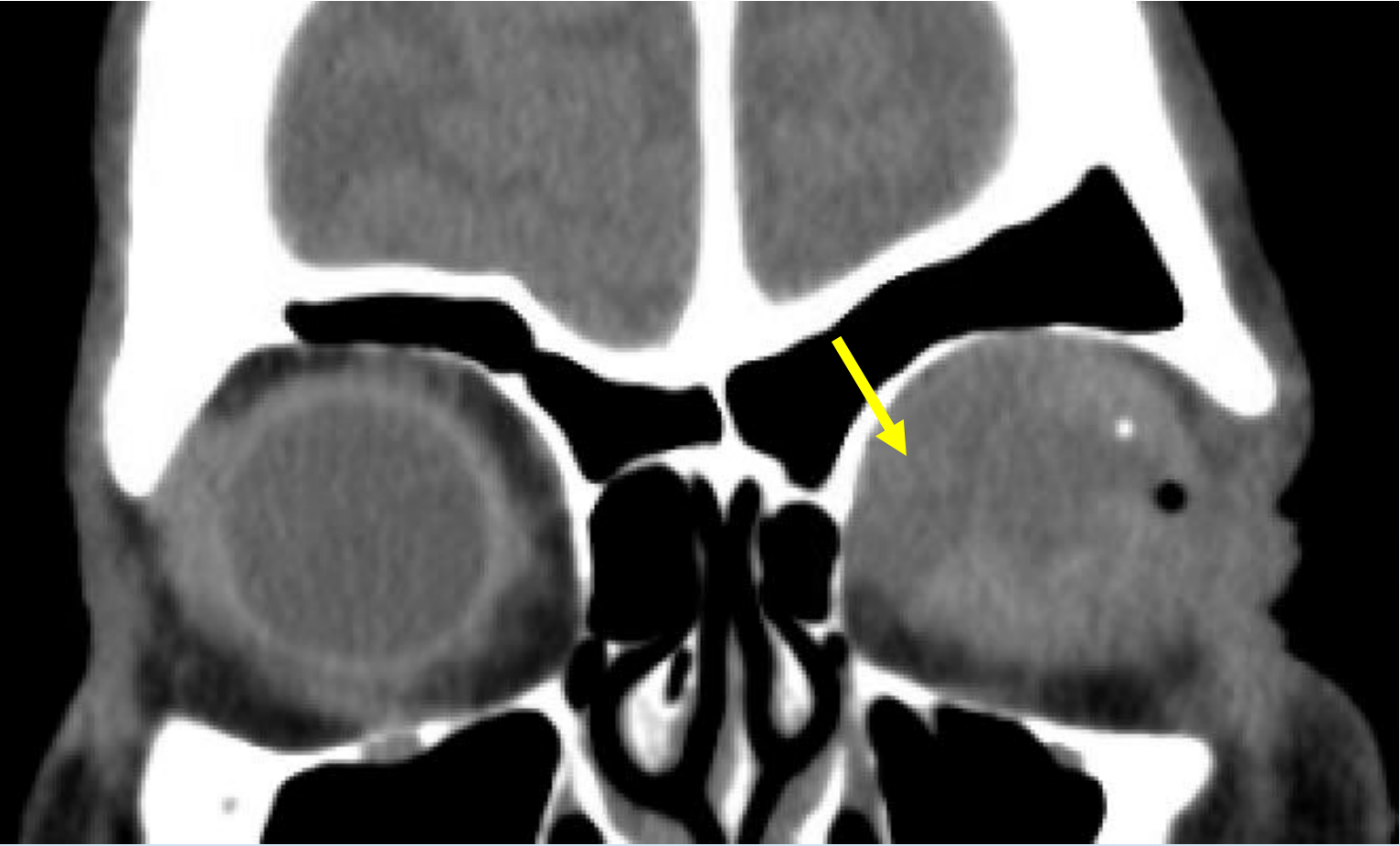


Exposed, expanded hydrogel scleral buckle.

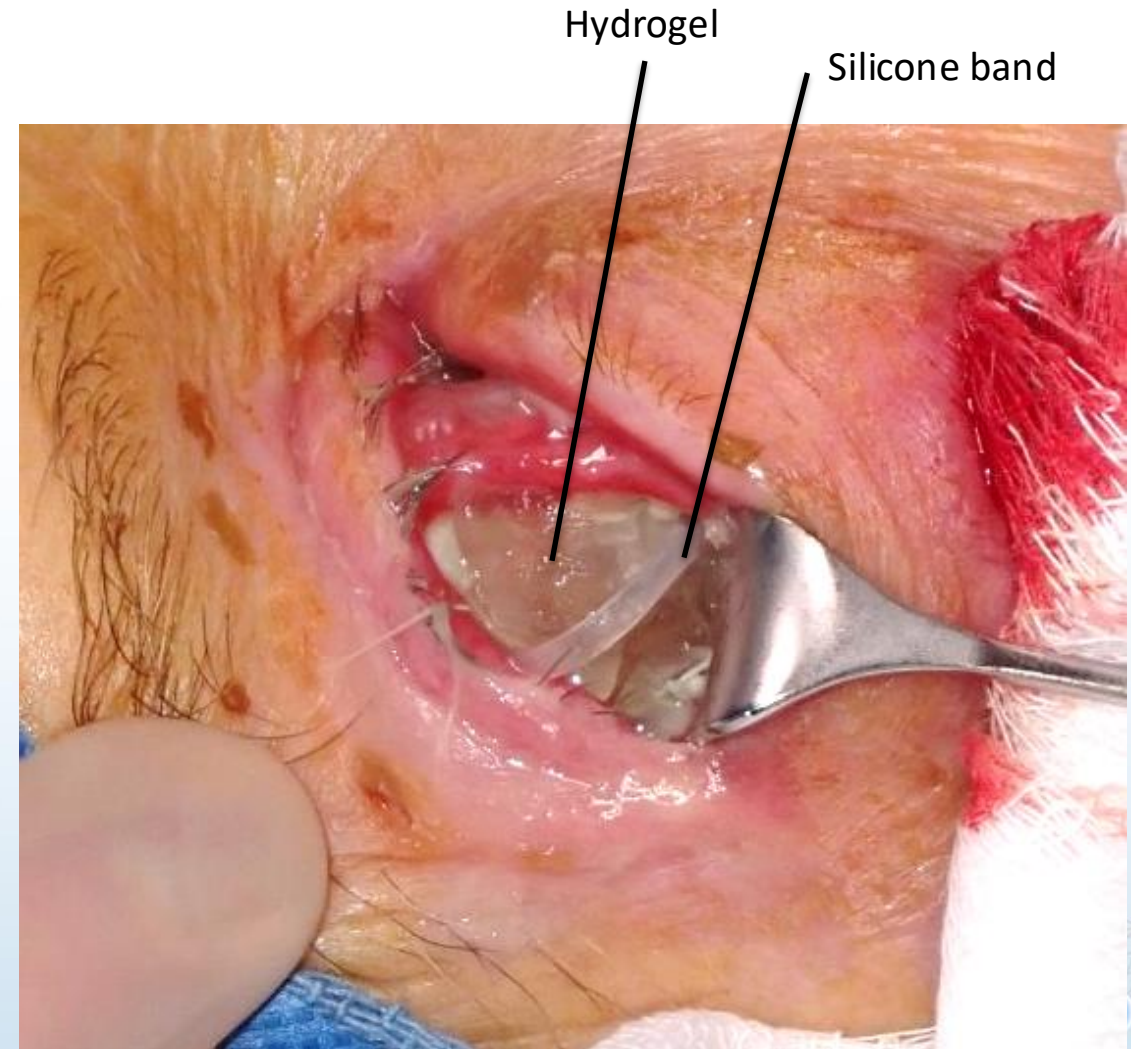
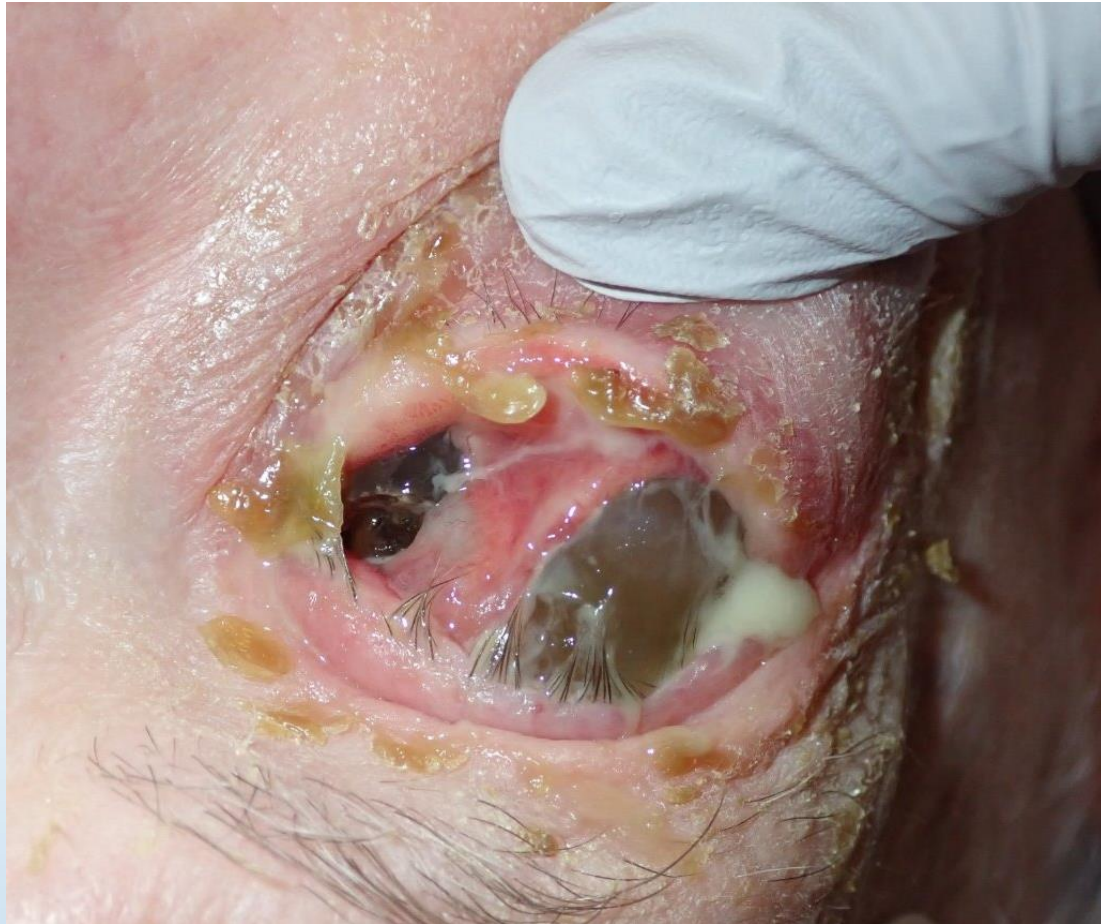Previous attempt at removal years ago resulted in intraoperative globe rupture.



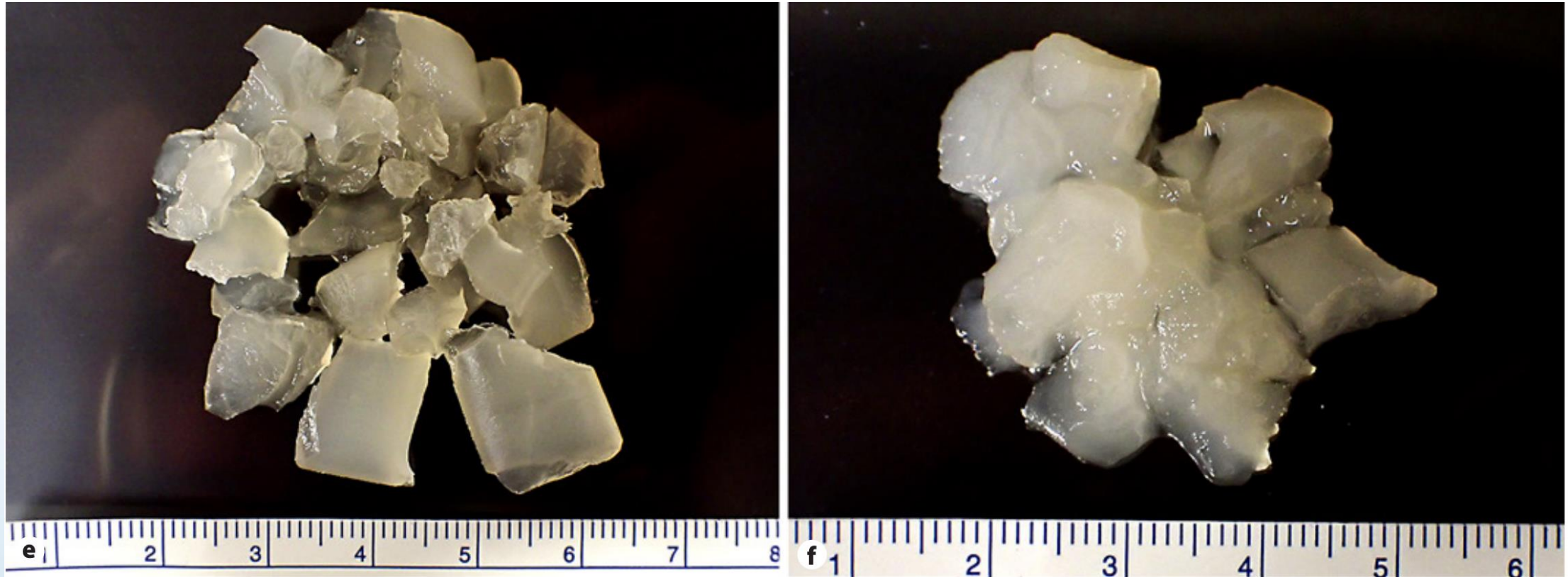
Hydrolyzed buckle resembling a mass



Intraoperative findings of expanded hydrogel scleral buckle

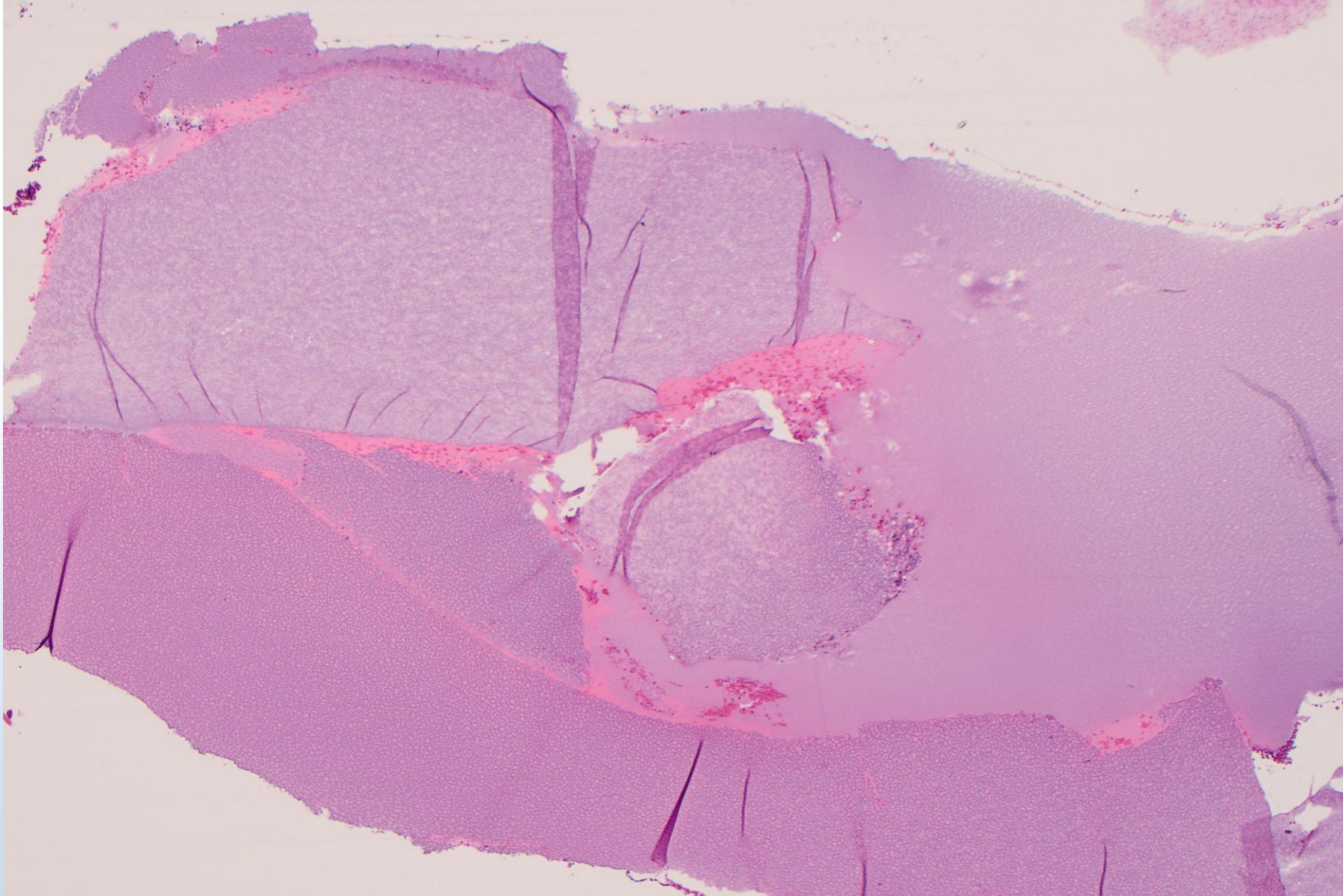


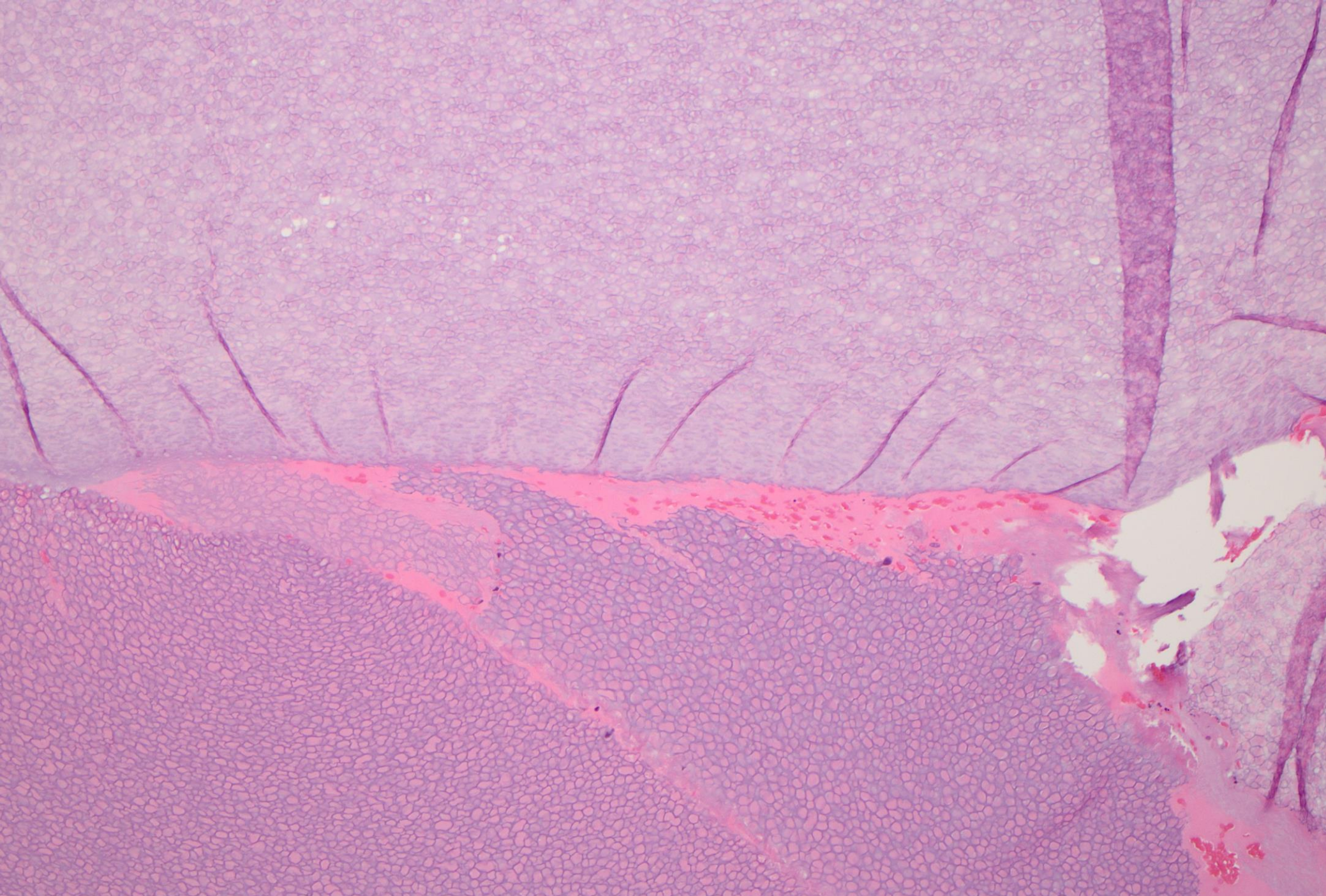
Gross appearance of expanded hydrogel scleral buckle

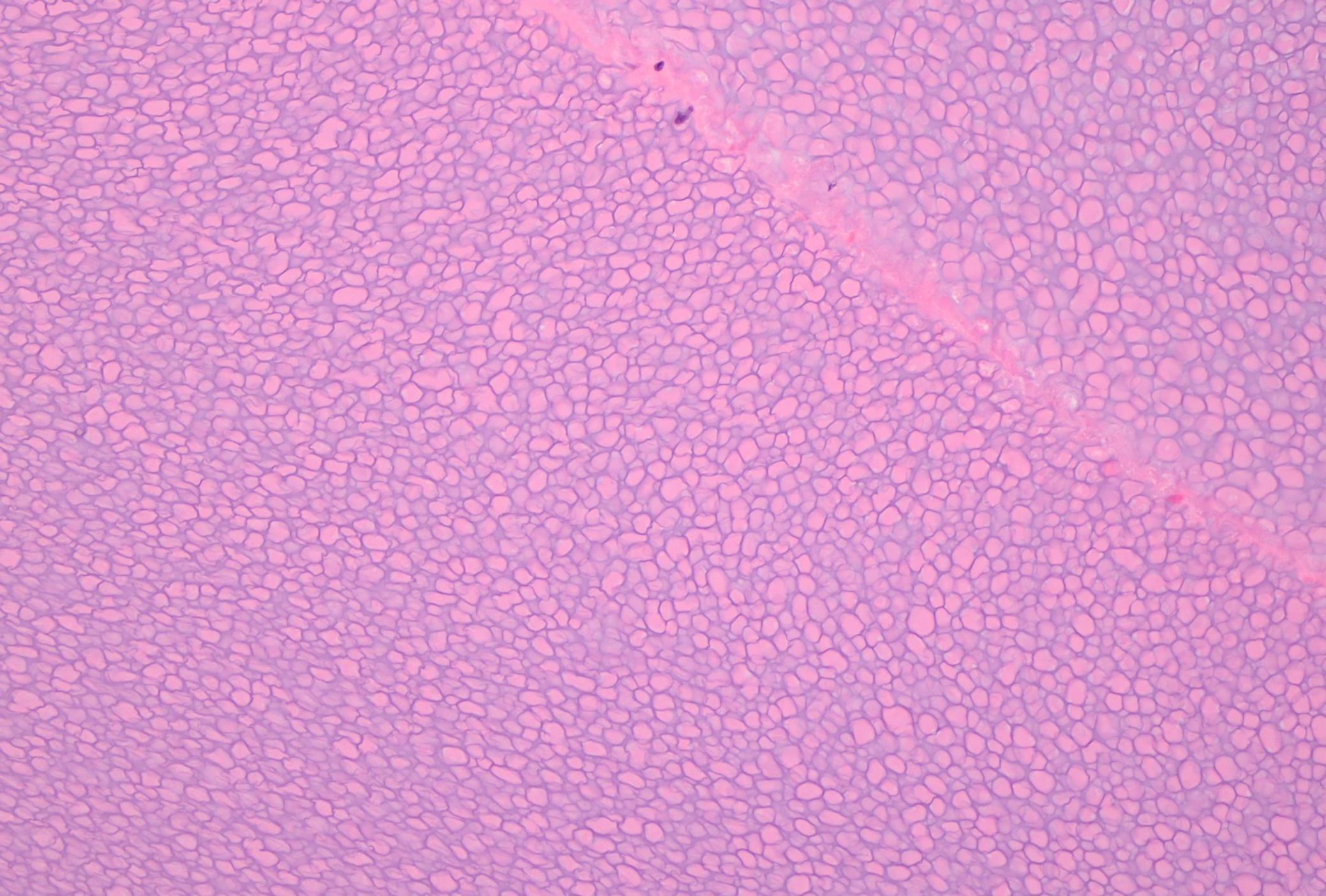


Wolkow N, Jakobiec FA. Histopathology of Hydrolyzed MIRAgel Scleral Buckles. Ocul Oncol Pathol. 2021 Sep;7(4):272-279. doi: 10.1159/000514299. Epub 2021 Apr 7. PMID: 34604200; PMCID: PMC8443933.

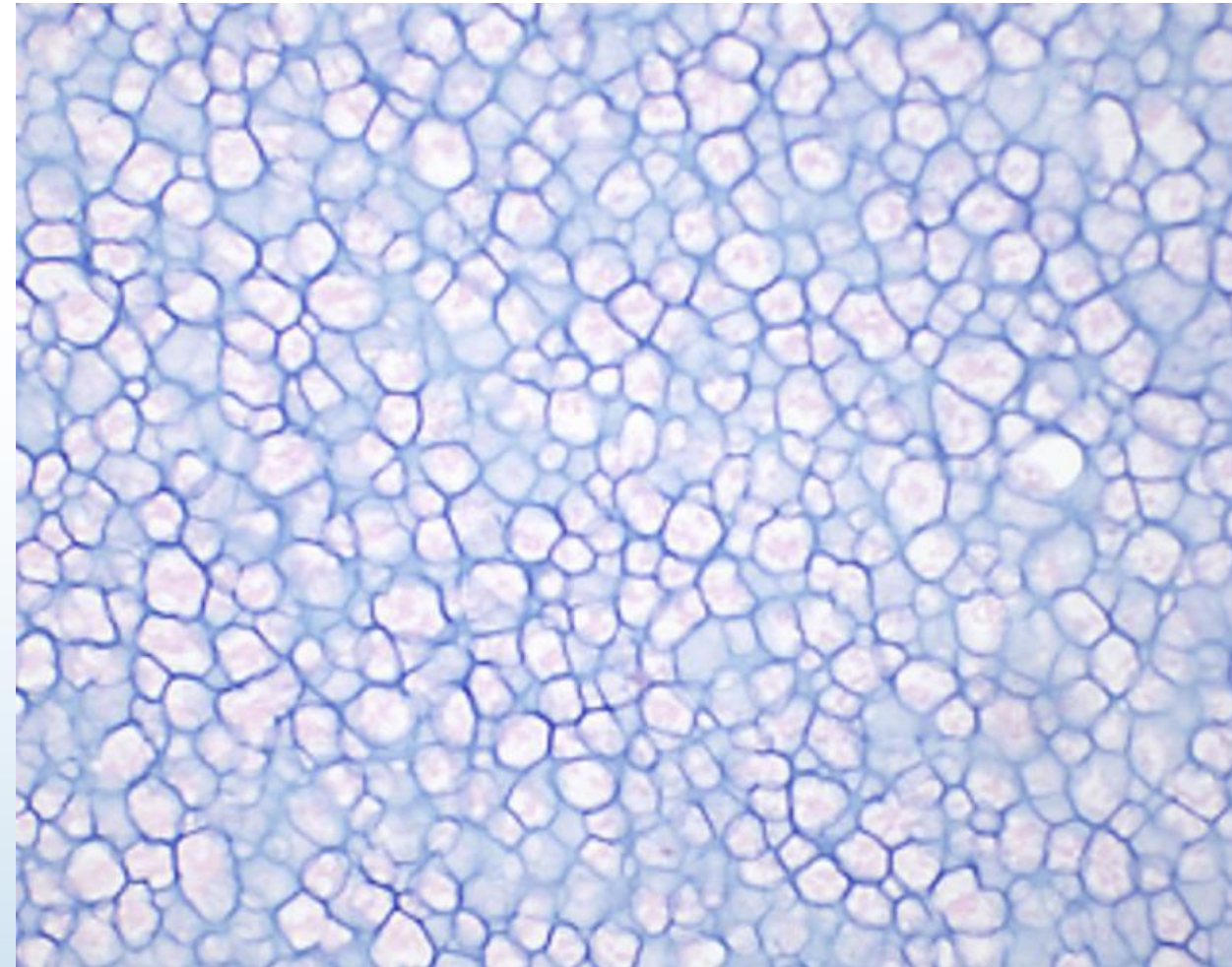
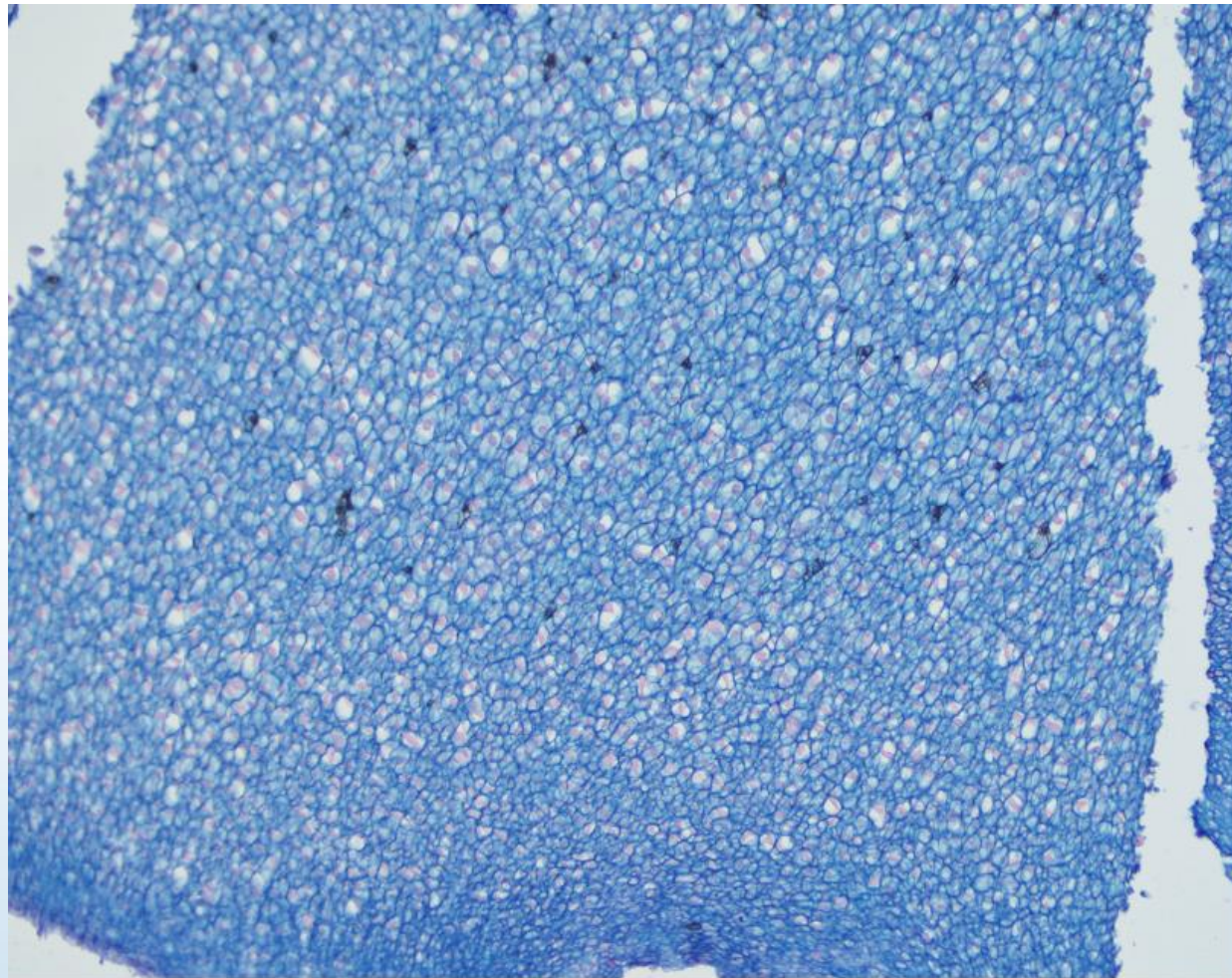
Histologic appearance of expanded hydrogel scleral buckle: sheets of honeycomb-like lattice



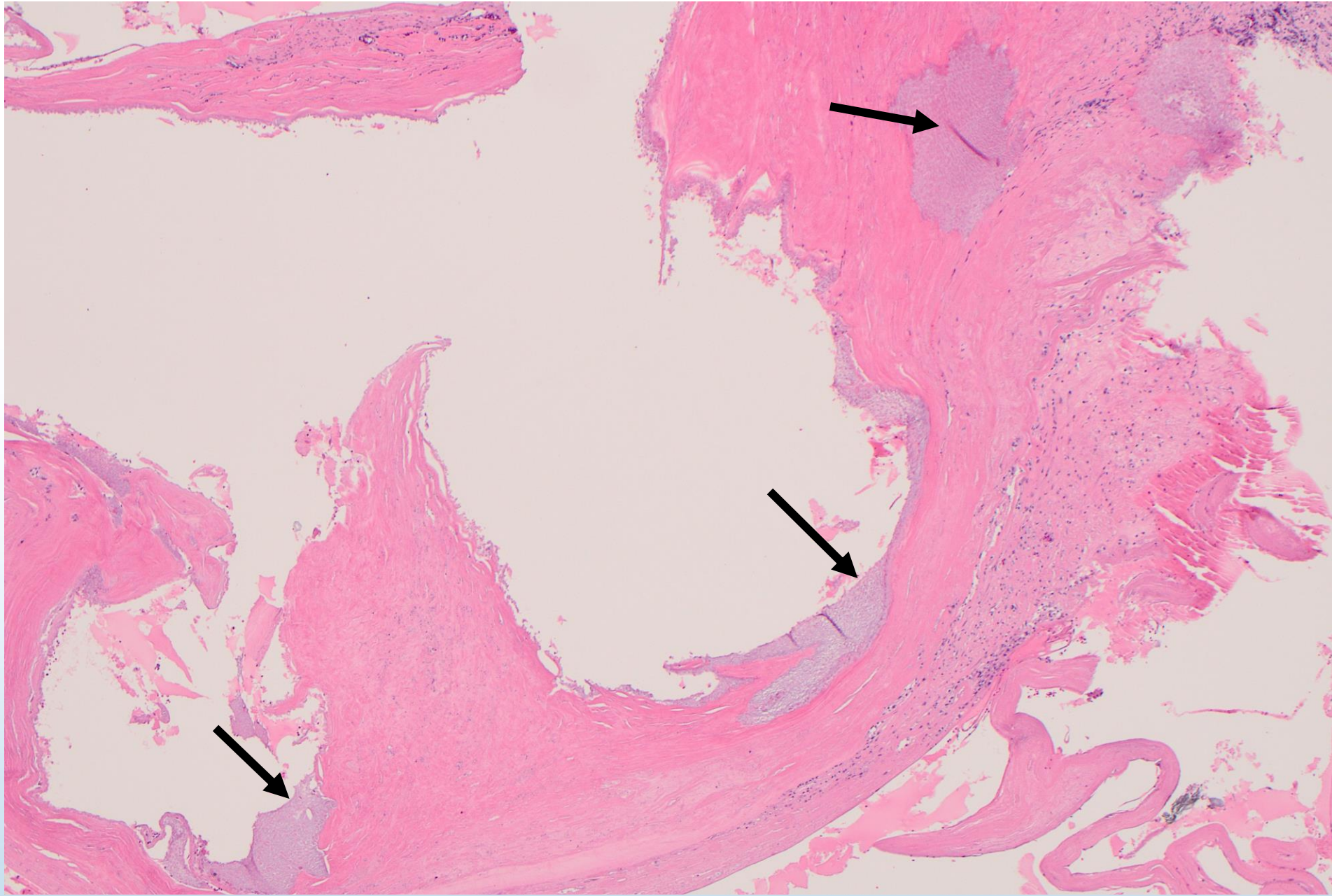


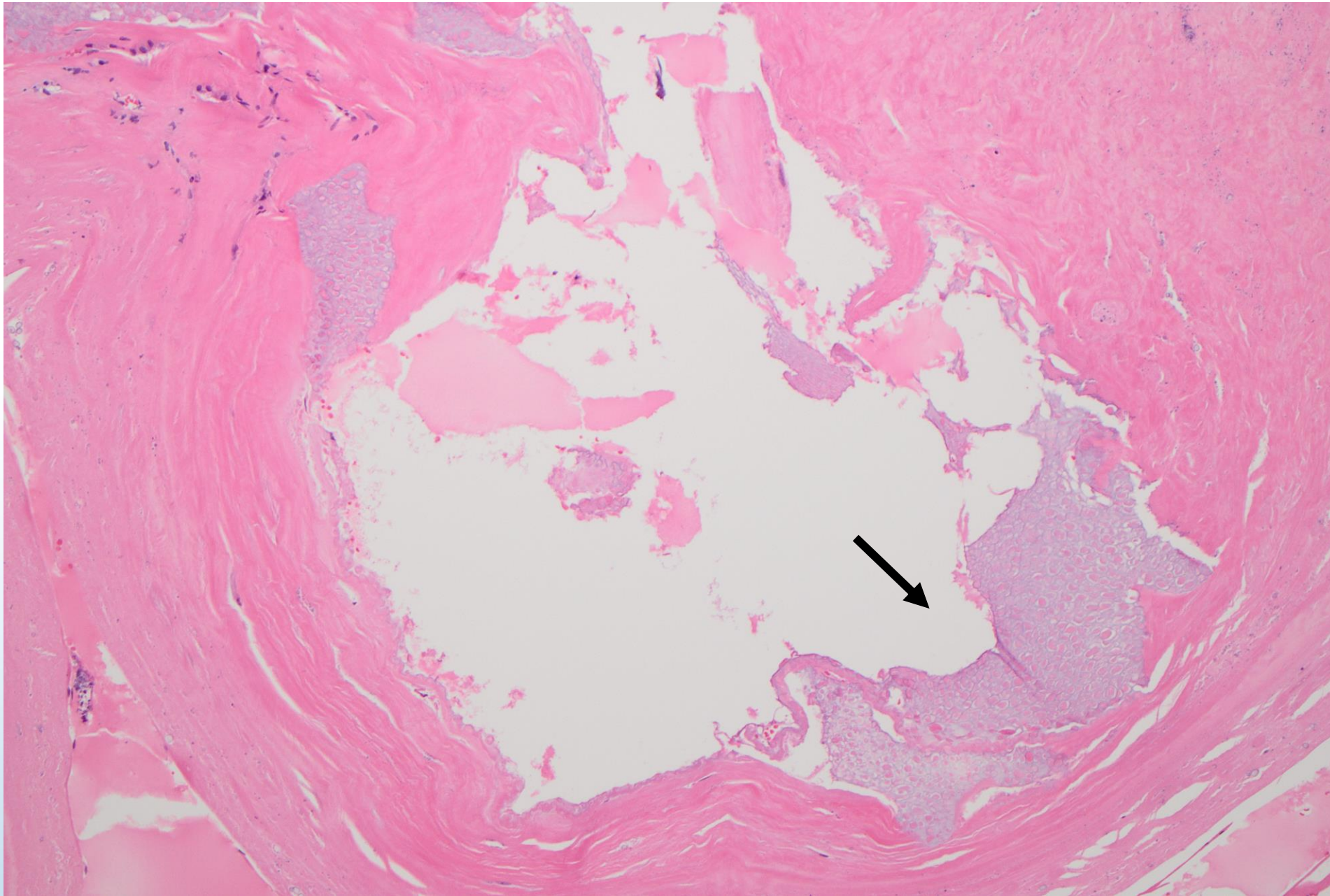


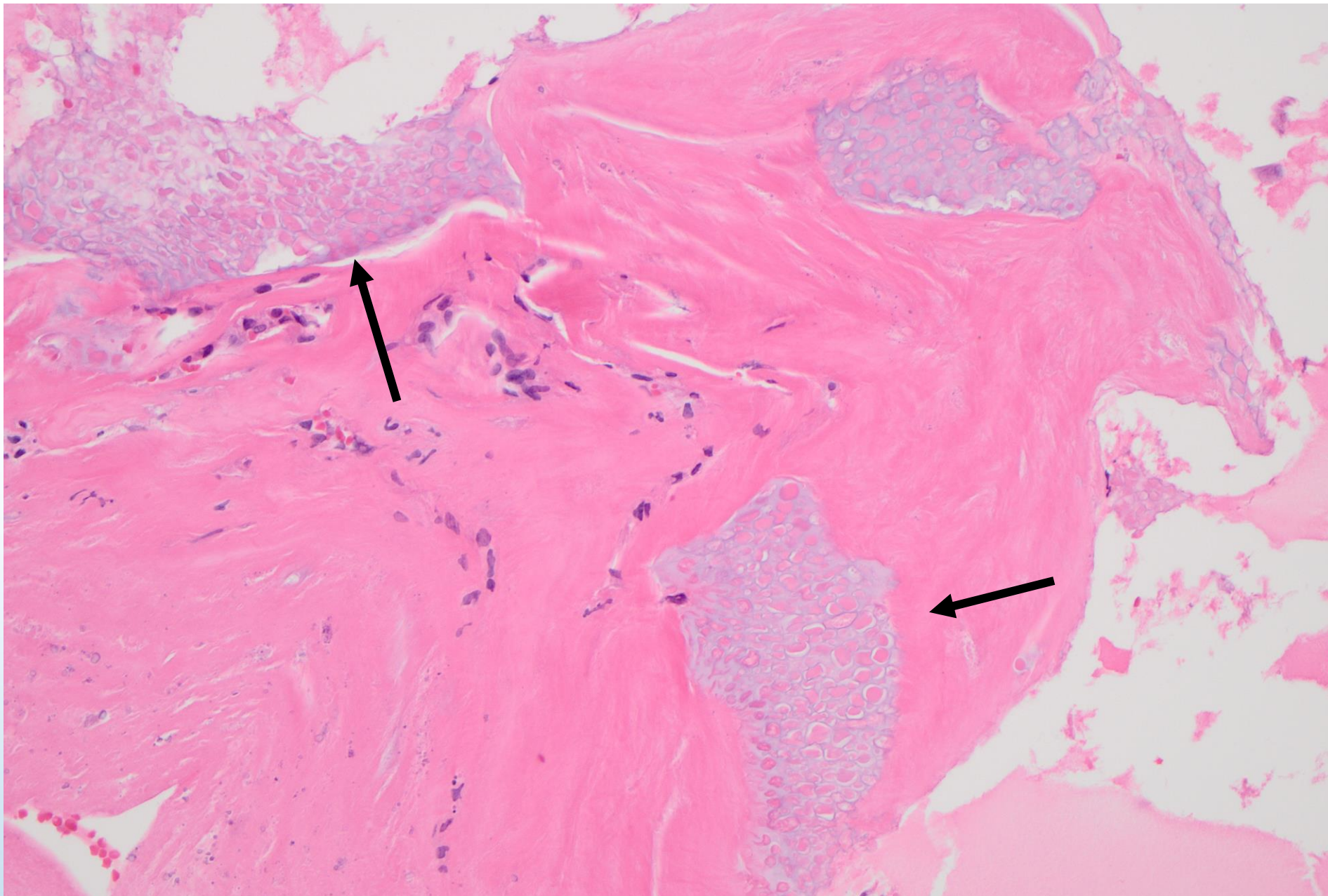
Alcian blue



Wolkow N, Jakobiec FA. Histopathology of Hydrolyzed MIRAgel Scleral Buckles. Ocul Oncol Pathol. 2021 Sep;7(4):272-279. doi: 10.1159/000514299. Epub 2021 Apr 7. PMID: 34604200; PMCID: PMC8443933.

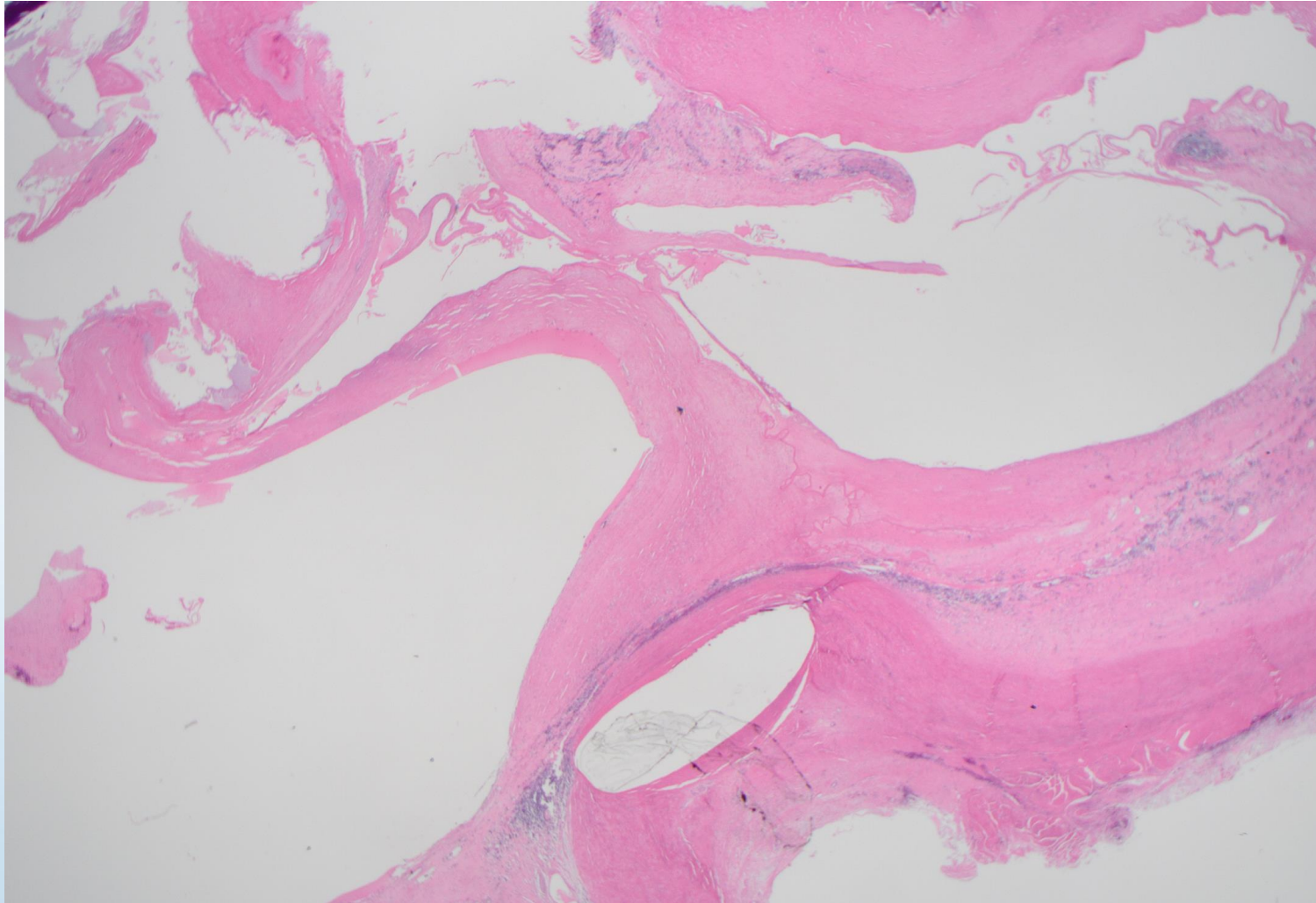






Case 3 Summary:

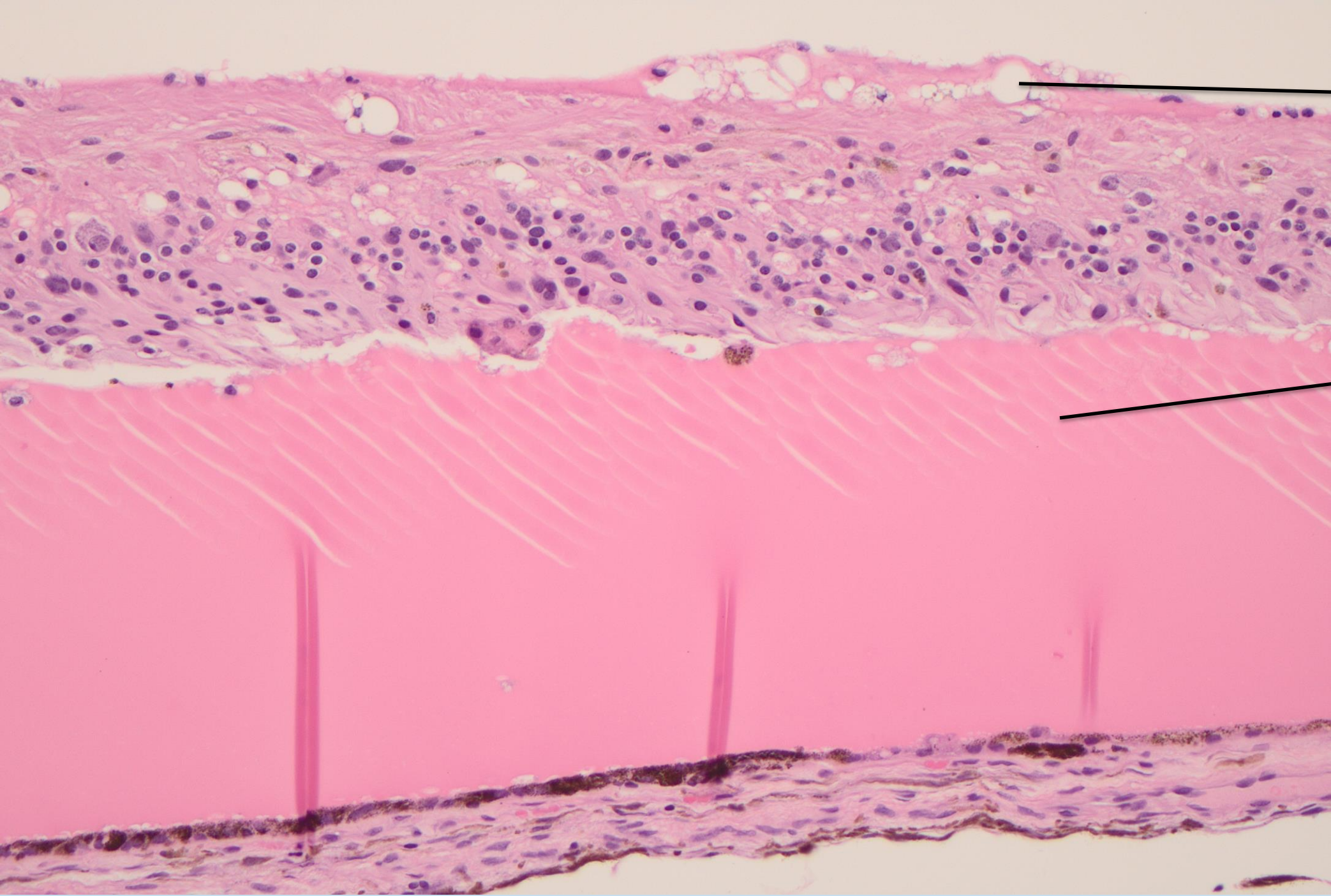
Pthisical eye with cyclitic membrane and evidence of prior retinal detachment repair with both silicone and hydrogel scleral buckles



Silicone Oil for Retinal Detachment


Spreads into many different tissues (including extraocular)



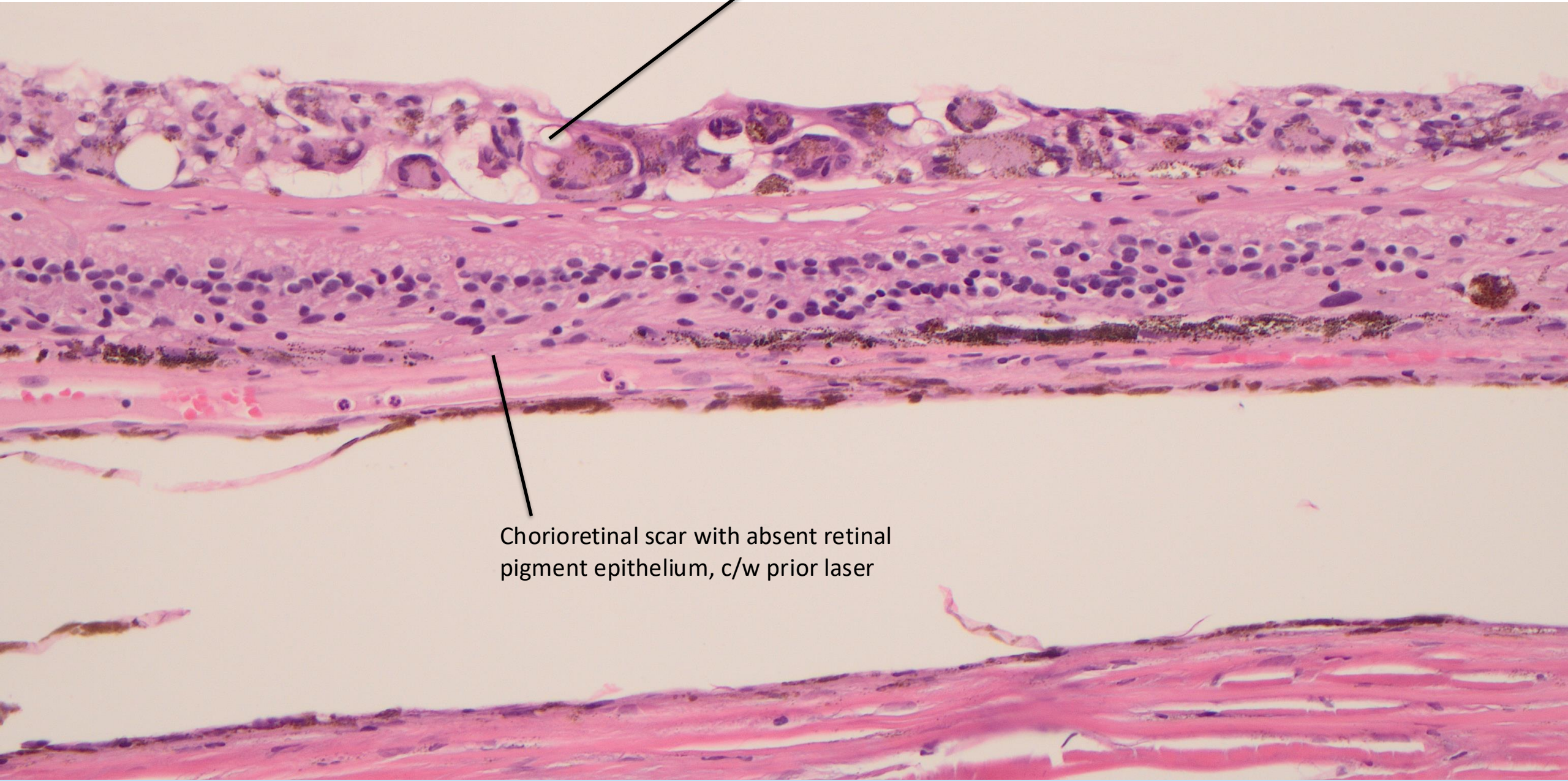


Silicone oil bubbles

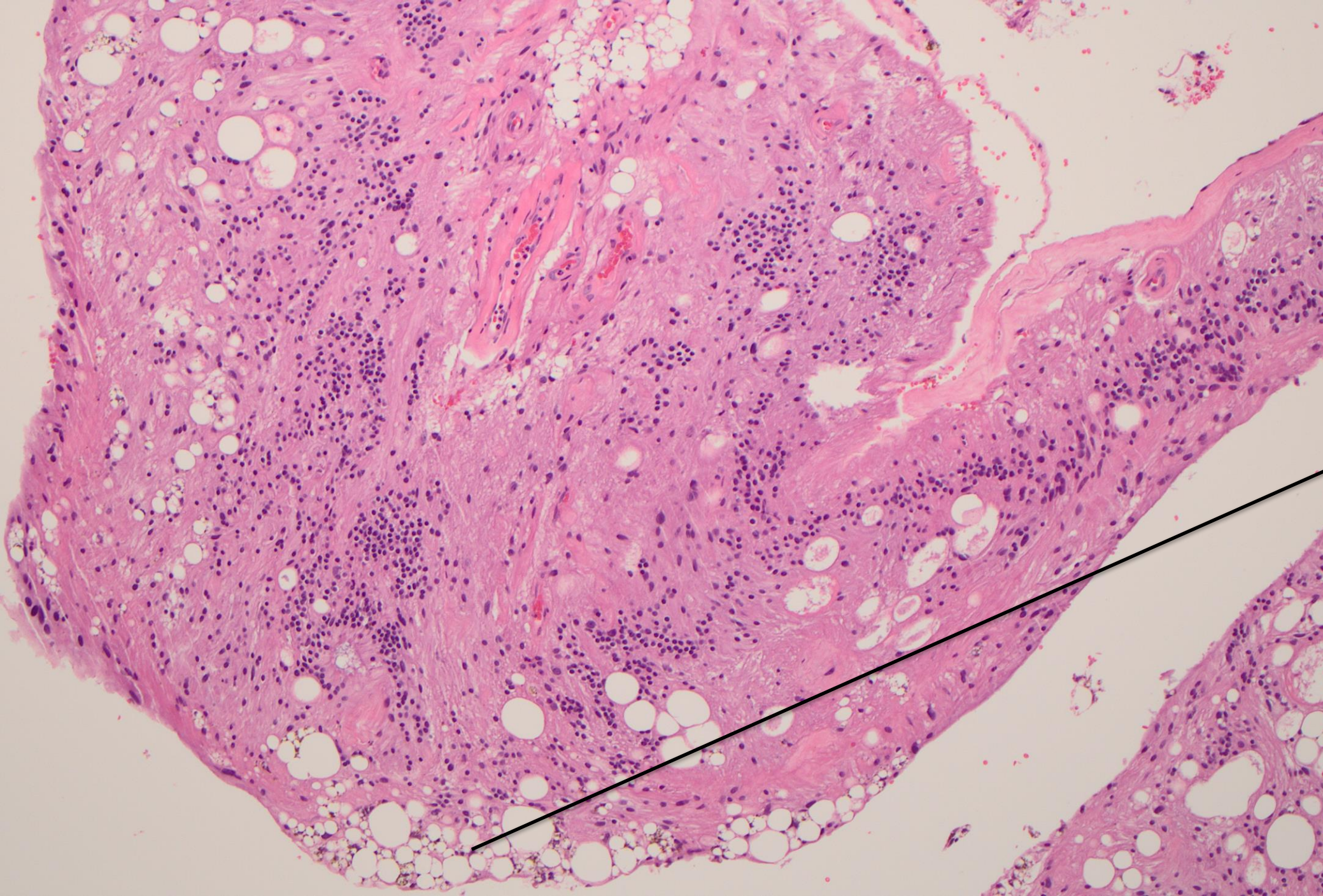
Chronic exudative
retinal detachment



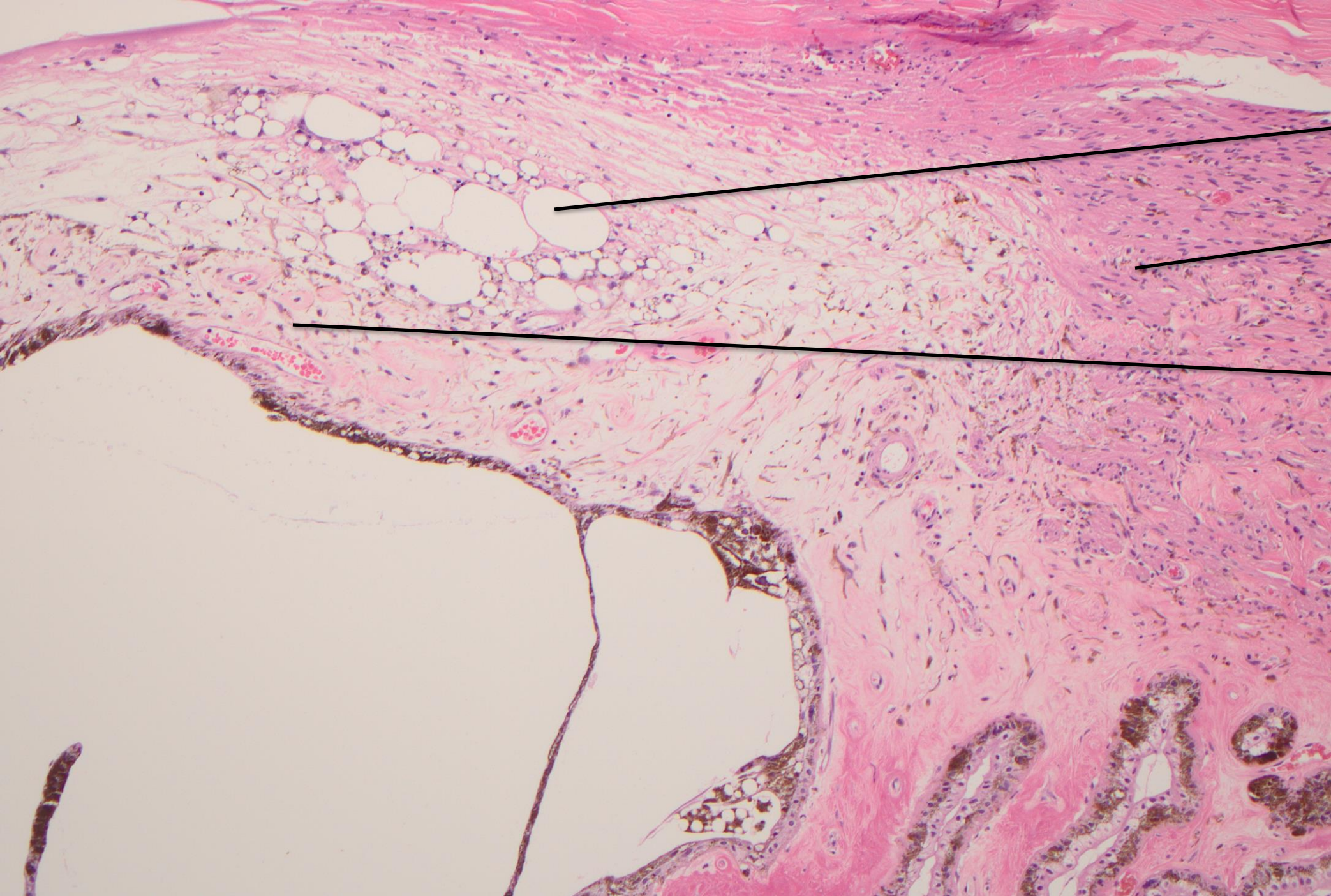
silicone oil bubbles with associated inflammation



Chorioretinal scar with absent retinal pigment epithelium, c/w prior laser



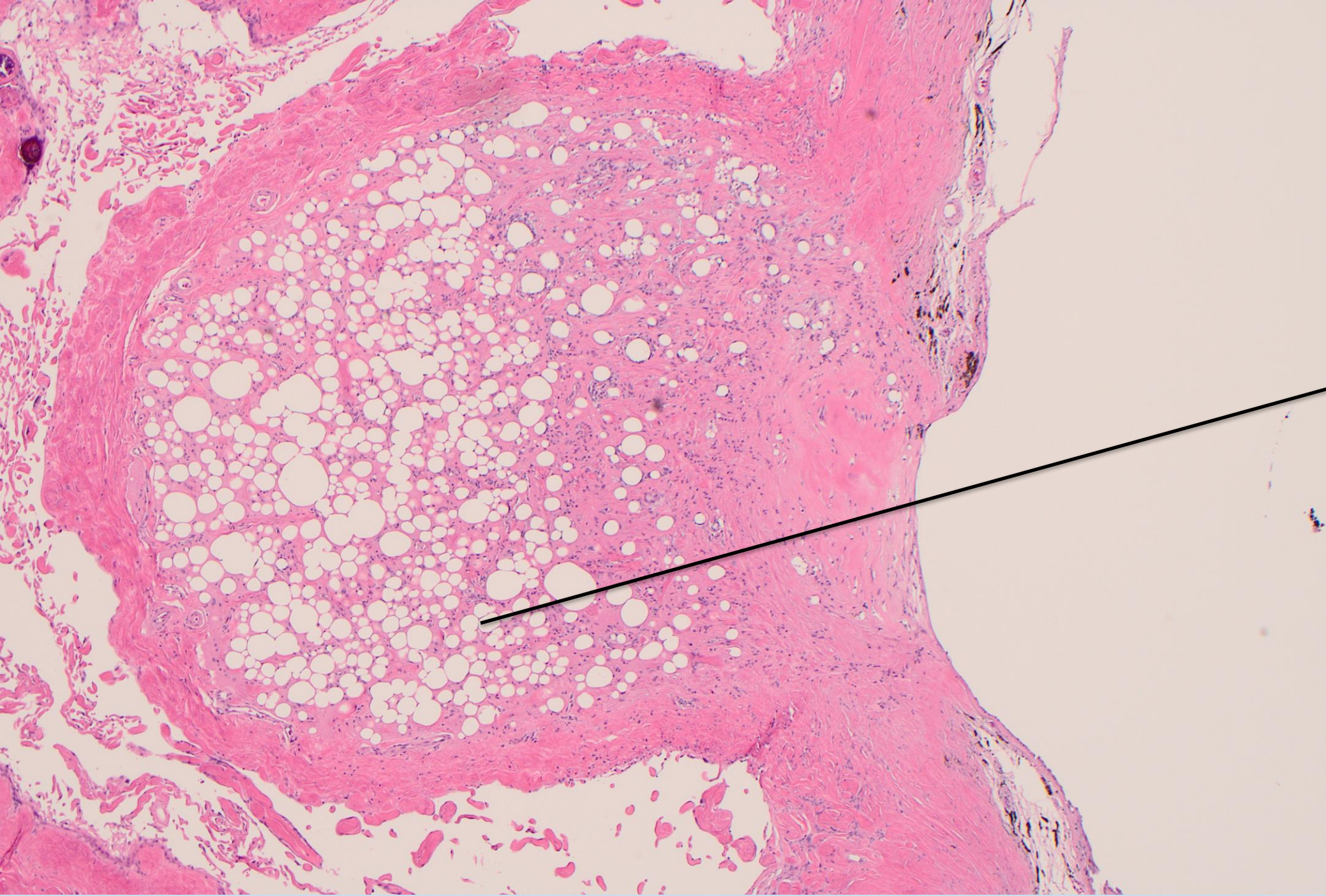
Silicone oil bubbles



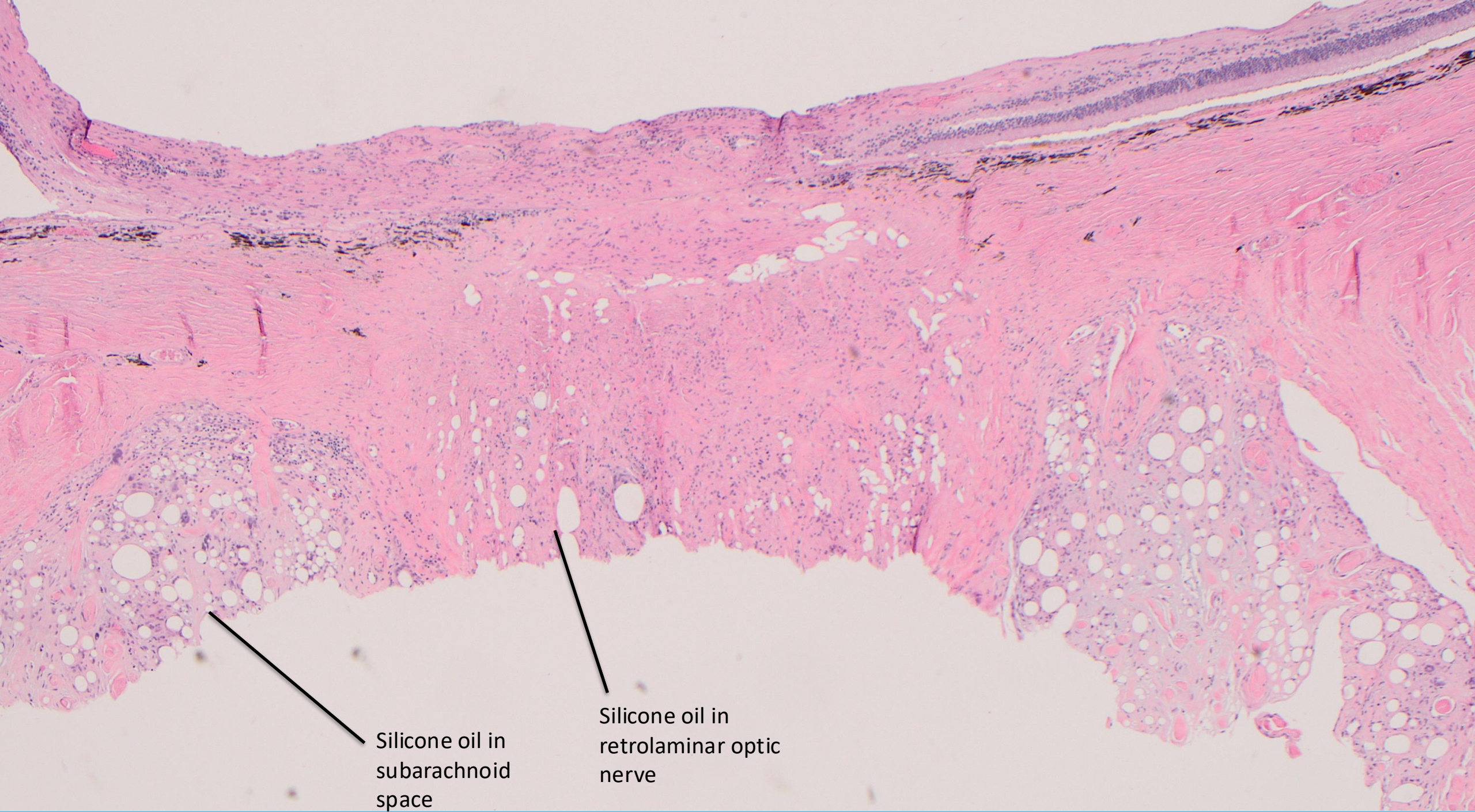Silicone oil

Ciliary body

Iris

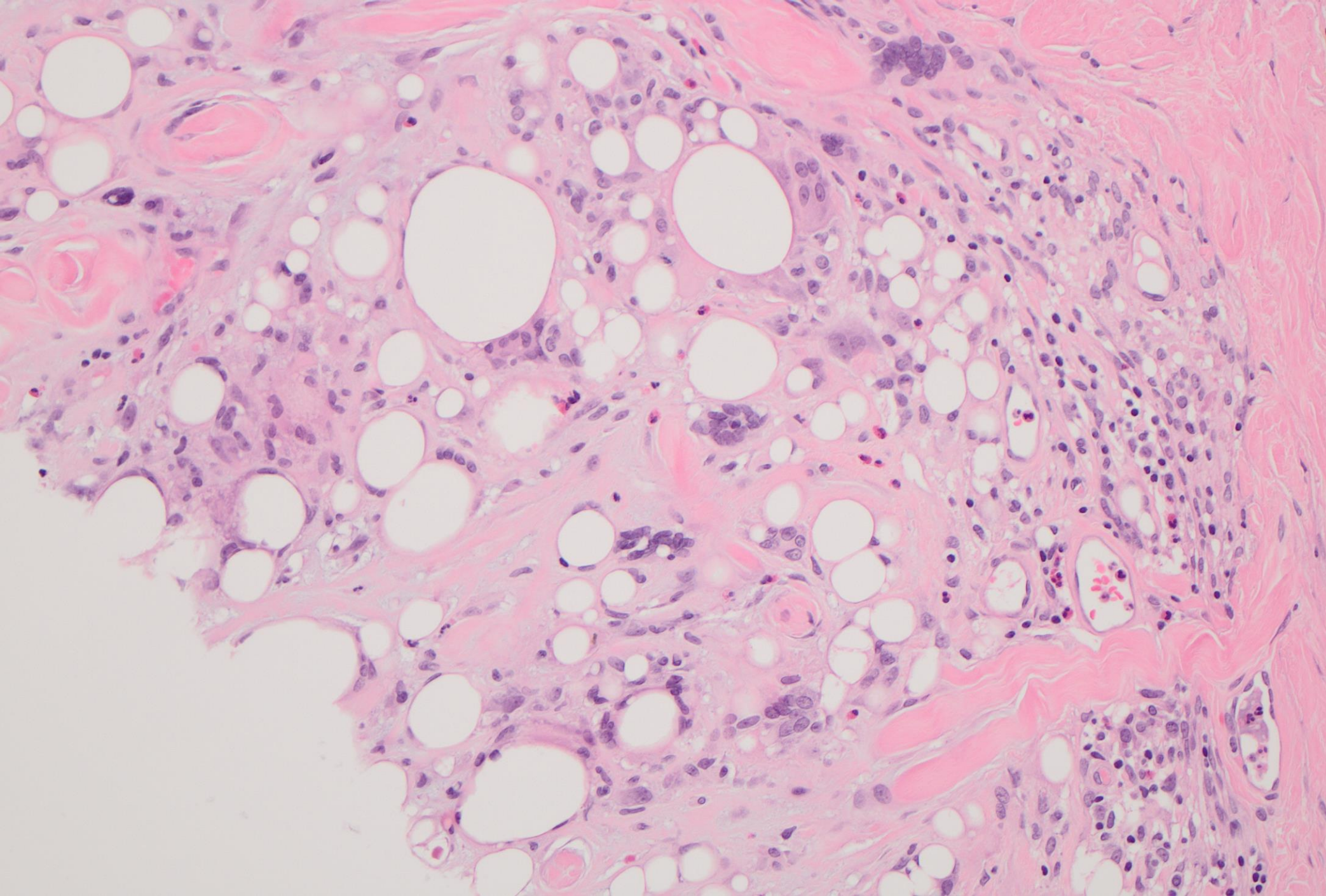


Silicone oil in the optic nerve

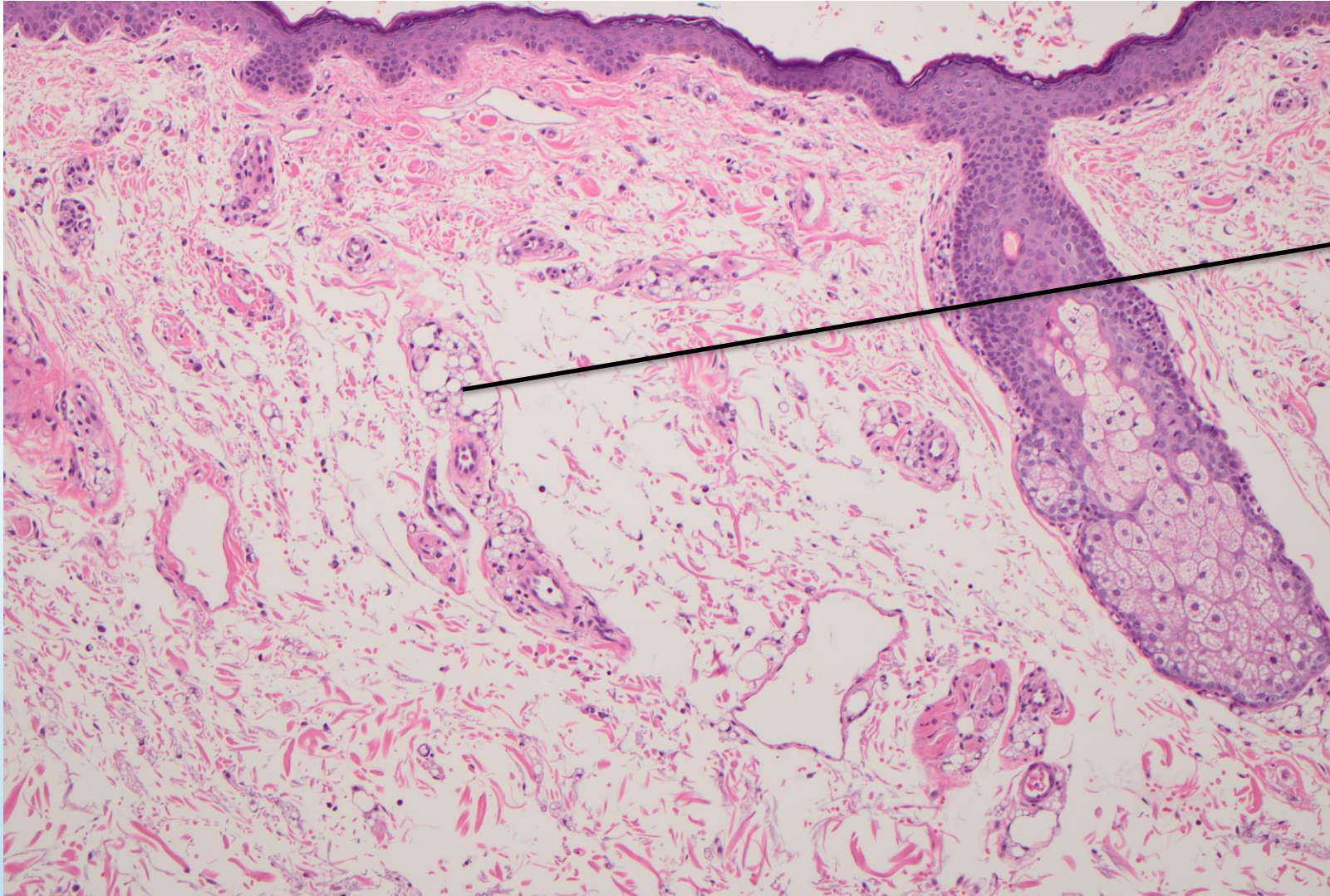


Silicone oil in
subarachnoid
space

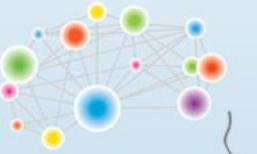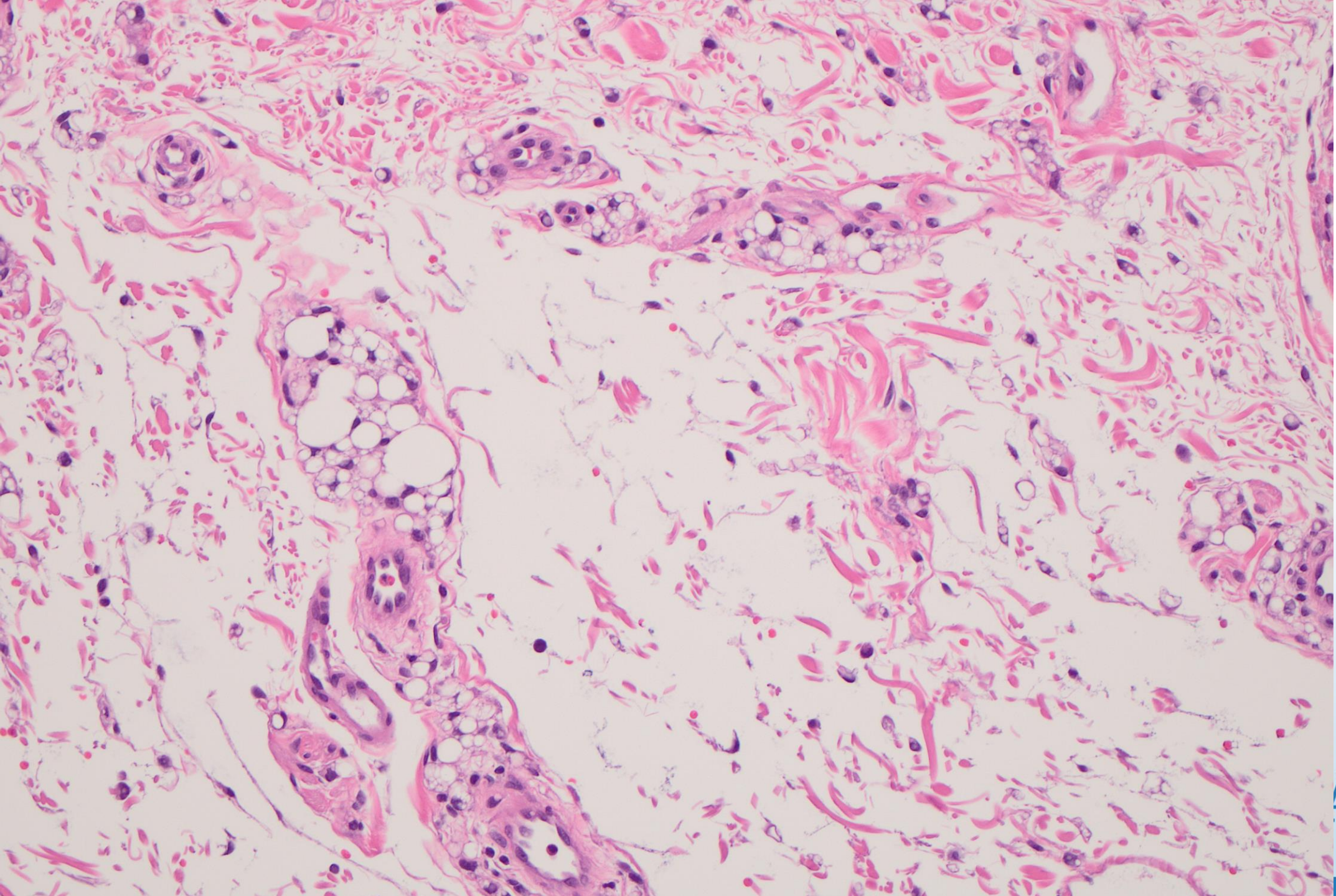
Silicone oil in
retrolaminar optic
nerve



Silicone oil in eyelid skin from blepharoplasty on same side as prior retinal detachment repair




Silicone oil



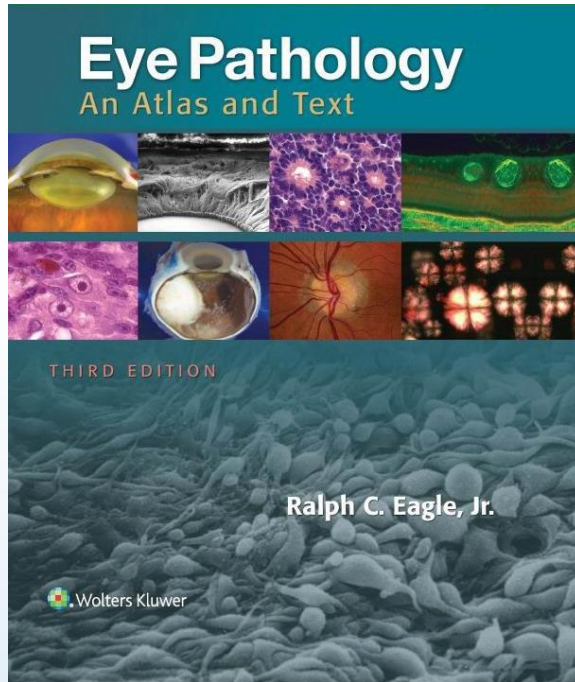
AANP

Summary

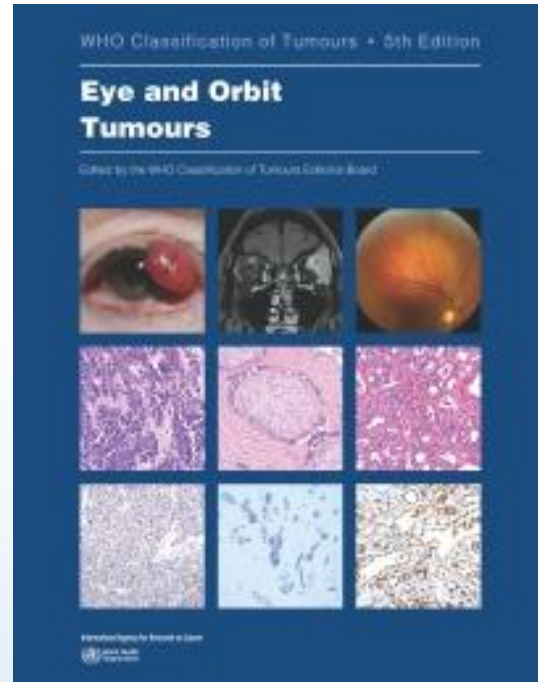
- **Cases reviewed:**
 - **Cornea with Avellino (Granular Type 2) dystrophy and deep anterior lamellar keratoplasty (DALK)**
 - **Intratarsal keratinous cyst**
 - **Phthisical eye with cyclitic membrane and evidence of prior retinal detachment repair with silicone scleral buckle and hydrogel buckle**
- **Reviewed relevant anatomy/histology**



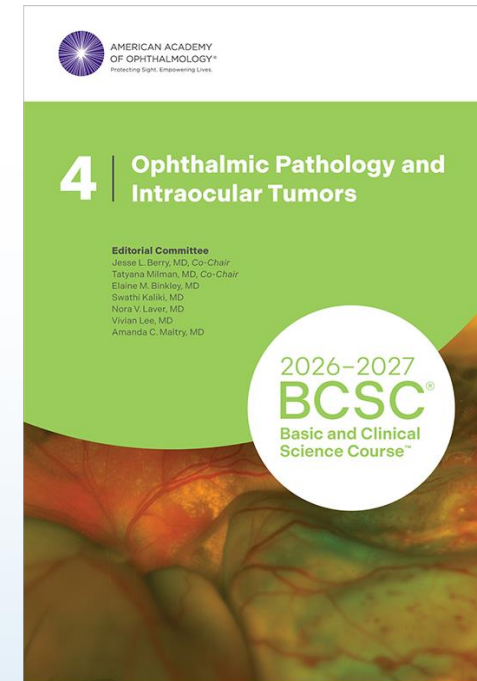
References




Eagle RC, Jr. *Eye Pathology: An Atlas and Text, 3e*. Lippincott Williams & Wilkins, a Wolters Kluwer business; 2017.



Eye and Orbit Tumours. WHO Classification of Tumours, 5th Edition, Volume 13. WHO Classification of Tumours Editorial Board. 2026



Berry, J and Milman, T. Ophthalmic Pathology and Intraocular Tumors. Basic and Clinical Science Course. American Academy of Ophthalmology. 2026.



A network diagram with various colored nodes and connecting lines on a blue background. The nodes are represented by circles of different sizes and colors, including green, blue, purple, and grey. They are interconnected by a web of thin, light-colored lines, creating a complex network structure. The background is a solid, medium blue color.

Thank you