

Infectious Diseases of the Central Nervous System

Isaac H. Solomon, MD, PhD

Associate Pathologist, Brigham and Women's Hospital

Assistant Professor of Pathology, Harvard Medical School



AMERICAN ASSOCIATION
OF NEUROPATHOLOGISTS

Disclosures

- I have no relevant financial relationships to disclose



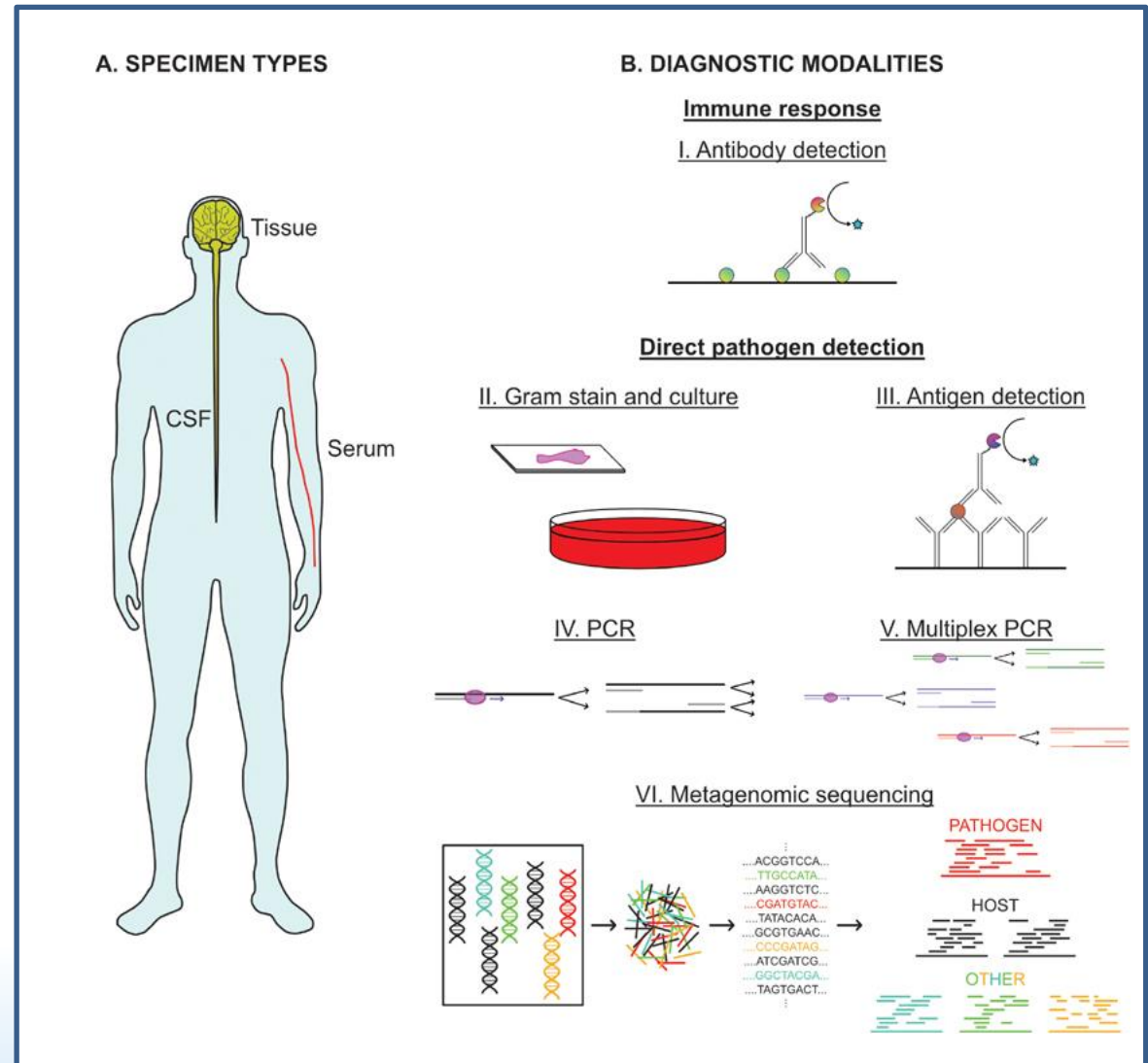
Learning Objectives

- Identify appropriate molecular testing assays for pathogen(s) of interest
- Interpret molecular testing results in context of histological and clinical findings
- Discuss benefits and limitations of unbiased sequencing assays



Diagnosis of CNS Infections

- Clinical history
- Radiology
- Blood
- CSF
- Brain tissue

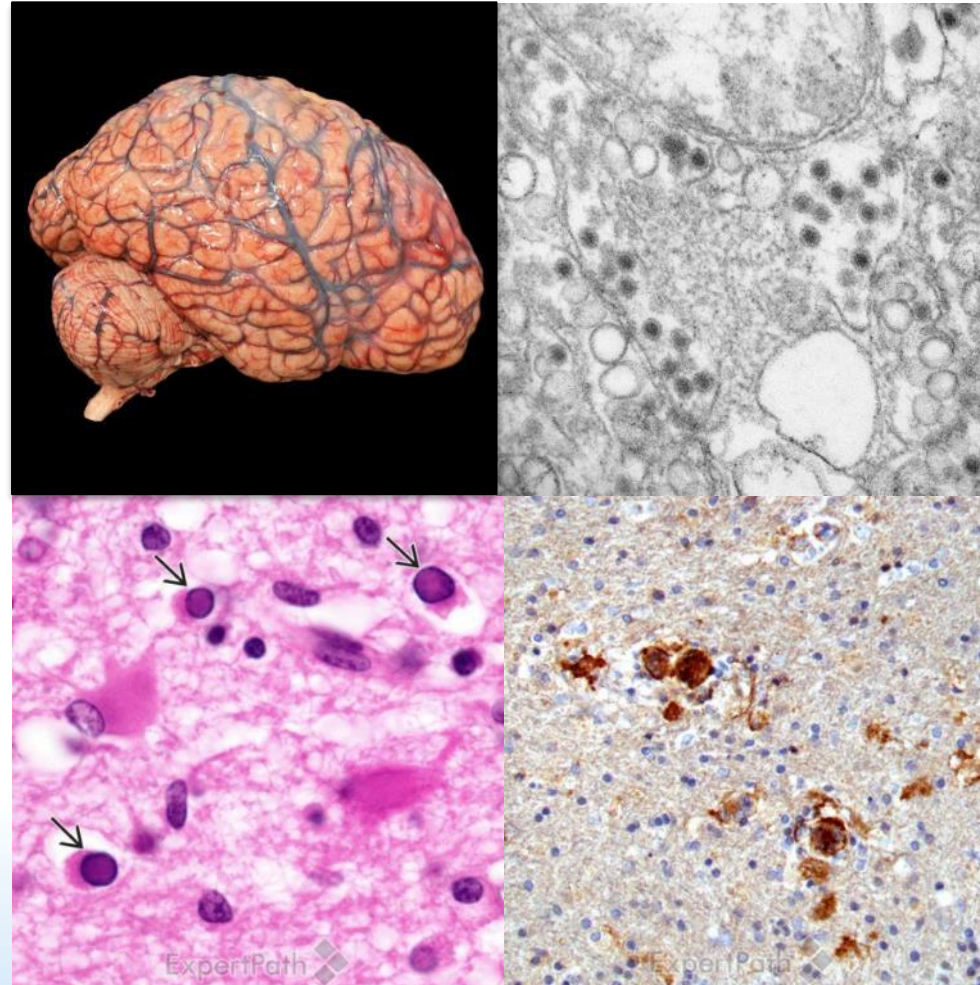


Kanjilal *et al.* (2019) *Semin Neurol.* 39(3):297-311.



Neuropathological Evaluation

- Gross examination
- Intraoperative frozen section and smear
- Routine H&E
- Special stains
- Immunohistochemistry
- *In situ* hybridization
- Electron microscopy
- Molecular testing



Molecular Testing for Infectious Diseases

- Generation of rapid, clinically actionable information
- Expensive to perform compared to conventional microbiology and anatomic pathology laboratory testing
- Selection of appropriate samples and molecular assays is critical to patient care and resource utilization

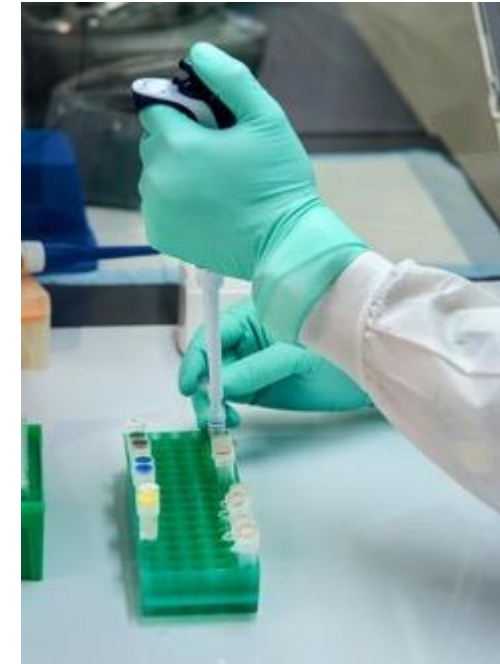
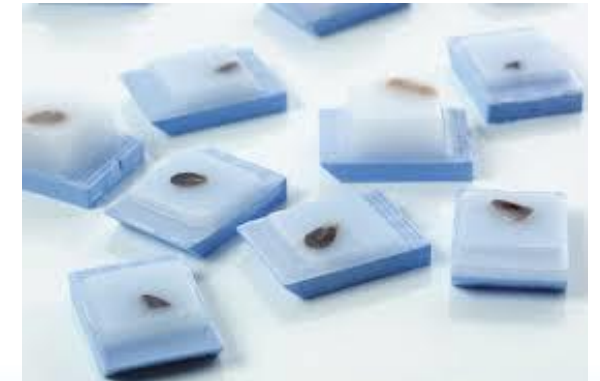
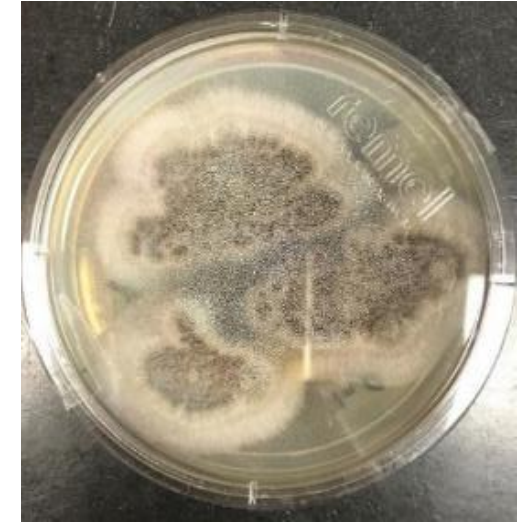Image Courtesy of CDC PHIL



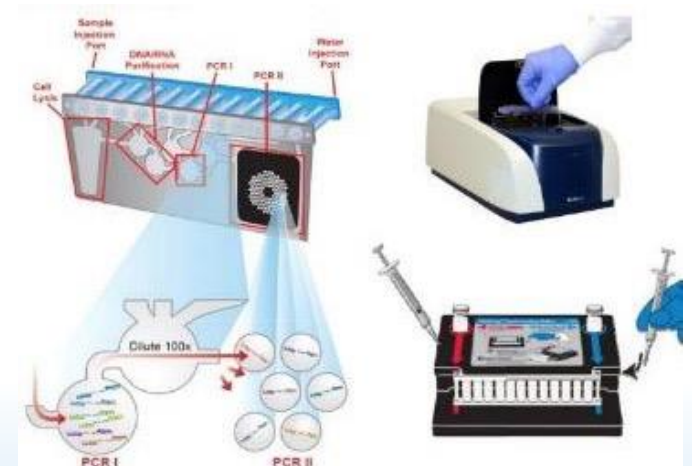
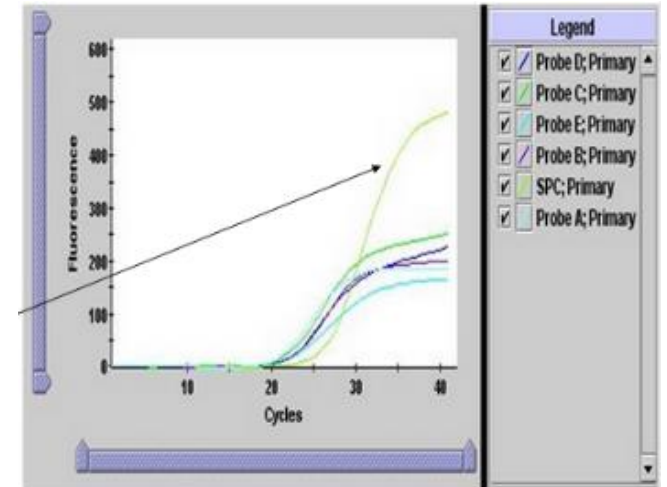
Selection of Specimen Types

- Culture isolate
 - High rate of positive testing
 - May take days to weeks for growth
- Fresh/frozen tissue/fluid
 - Can be performed immediately; no fixation interference
 - Prone to contamination
- Formalin-fixed paraffin-embedded (FFPE) tissue
 - Can be screened for organisms/inflammation
 - Decreased sensitivity due to nucleic acid cross-linking



Selection of Molecular Assay

- Single pathogen (e.g. *Toxoplasma gondii*)
 - High sensitivity; automatable with rapid turnaround
 - Requires high degree of suspicion to select correct test
- Targeted panel (e.g. Meningitis/Encephalitis)
 - Conserves specimen volume by testing for most common pathogens associated with specific symptoms
 - Lower sensitivity/specificity; will miss unusual organisms

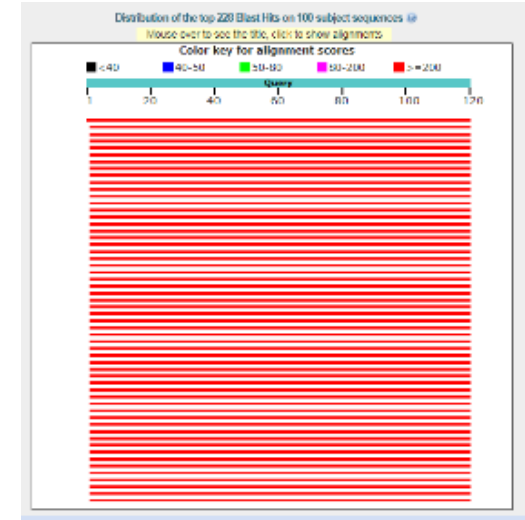


Rand et al. (2011) *J Clin Micro.* 49(7) 2449-2453



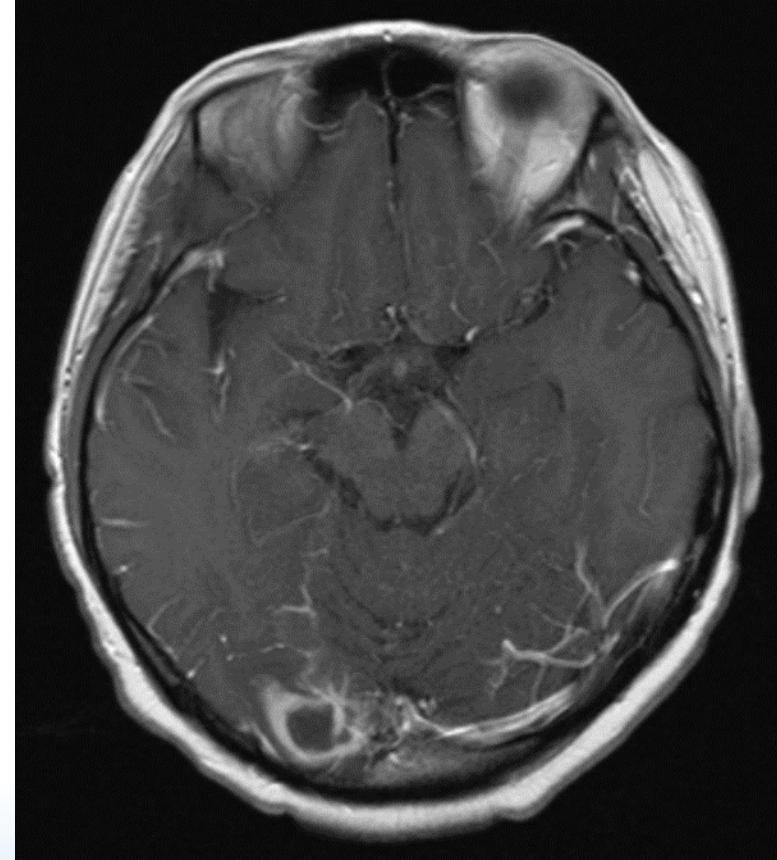
Selection of Molecular Assay

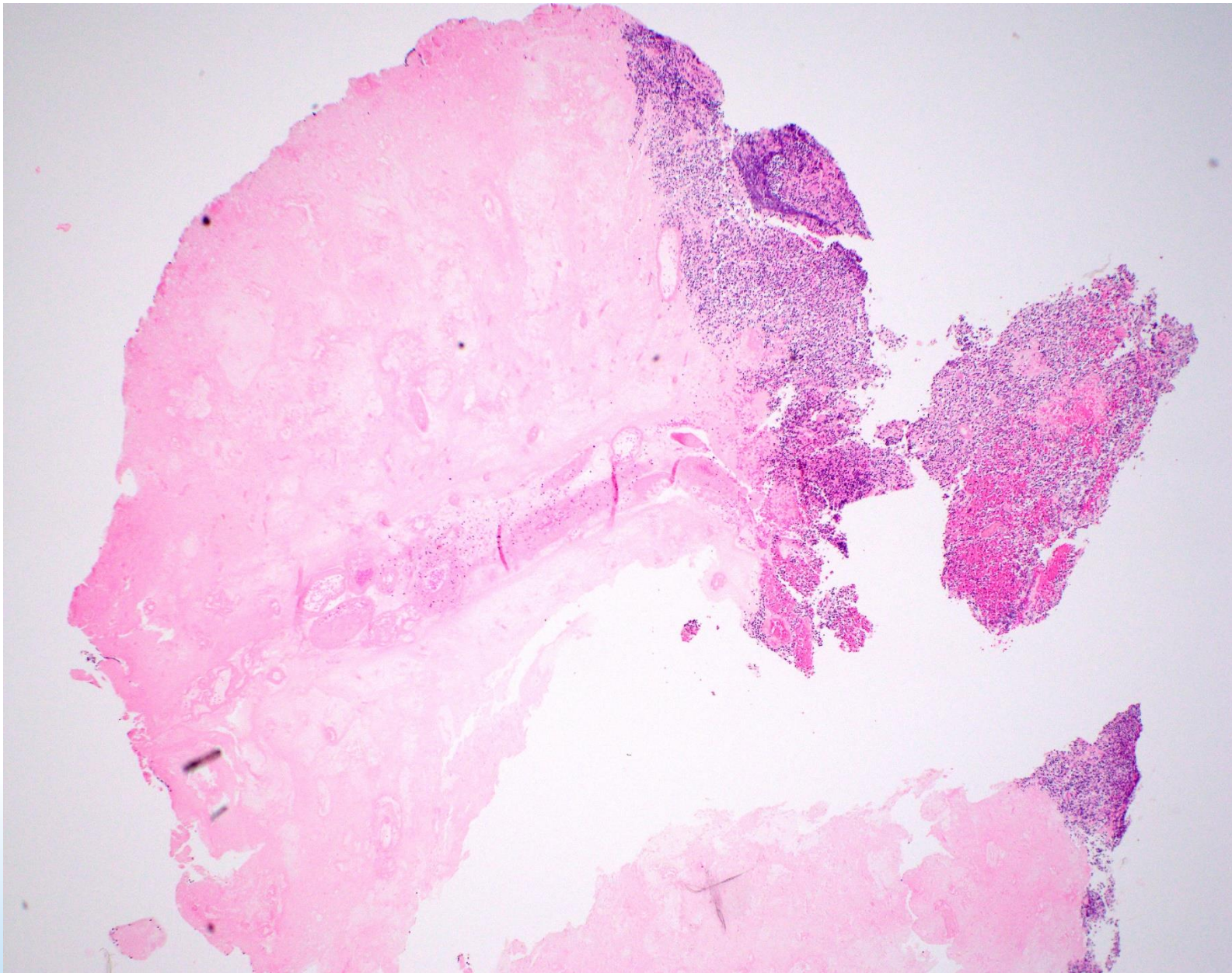
- Broad spectrum (e.g. Bacterial 16S rRNA gene sequencing)
 - Provides genus and often species identification for bacteria or fungus
 - Requires interpretation and limited by sequencing databases
- Unbiased (e.g. metagenomic next-generation sequencing)
 - Detects any non-human nucleic acids including novel pathogens
 - High sensitivity results in false positives; more expensive

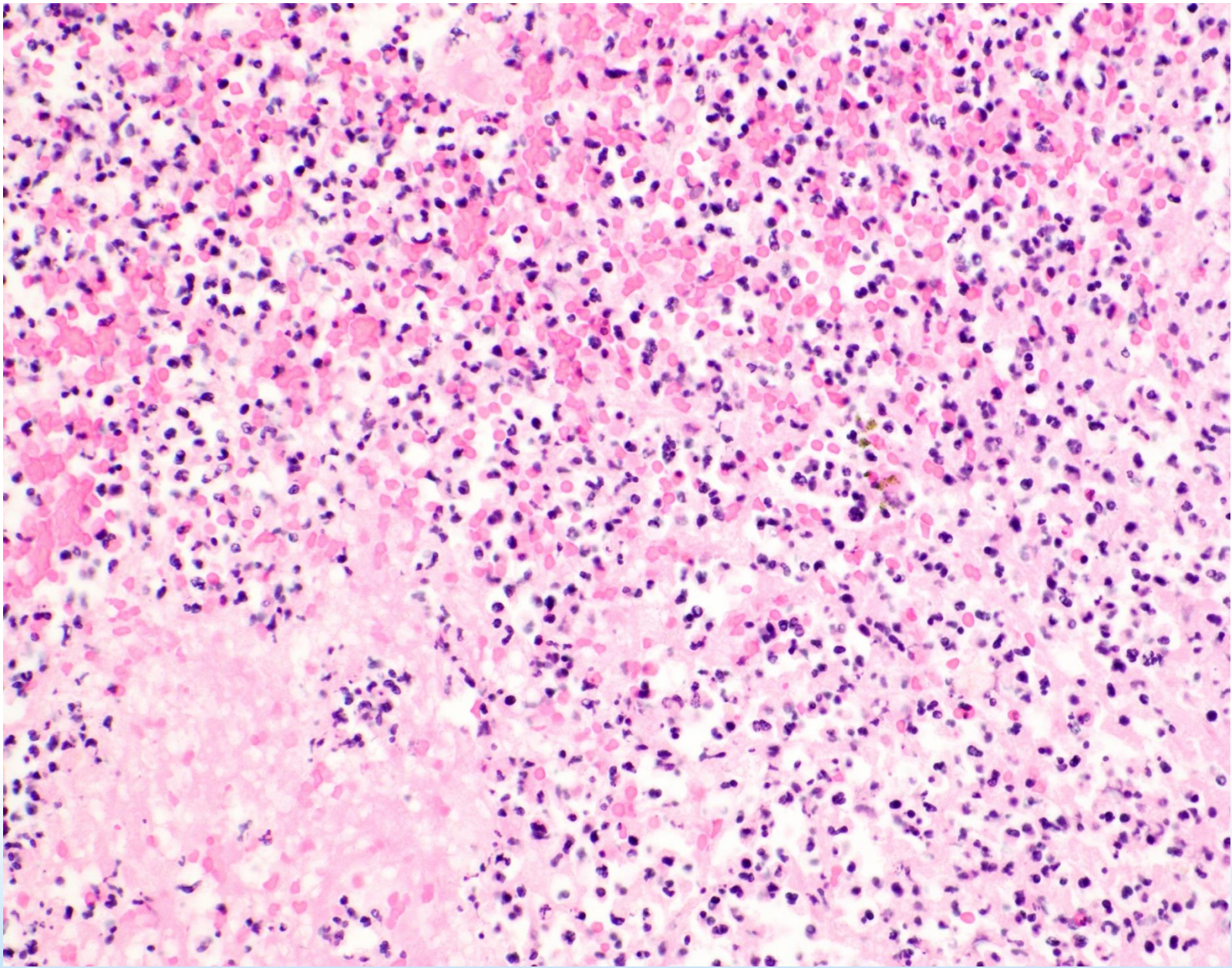


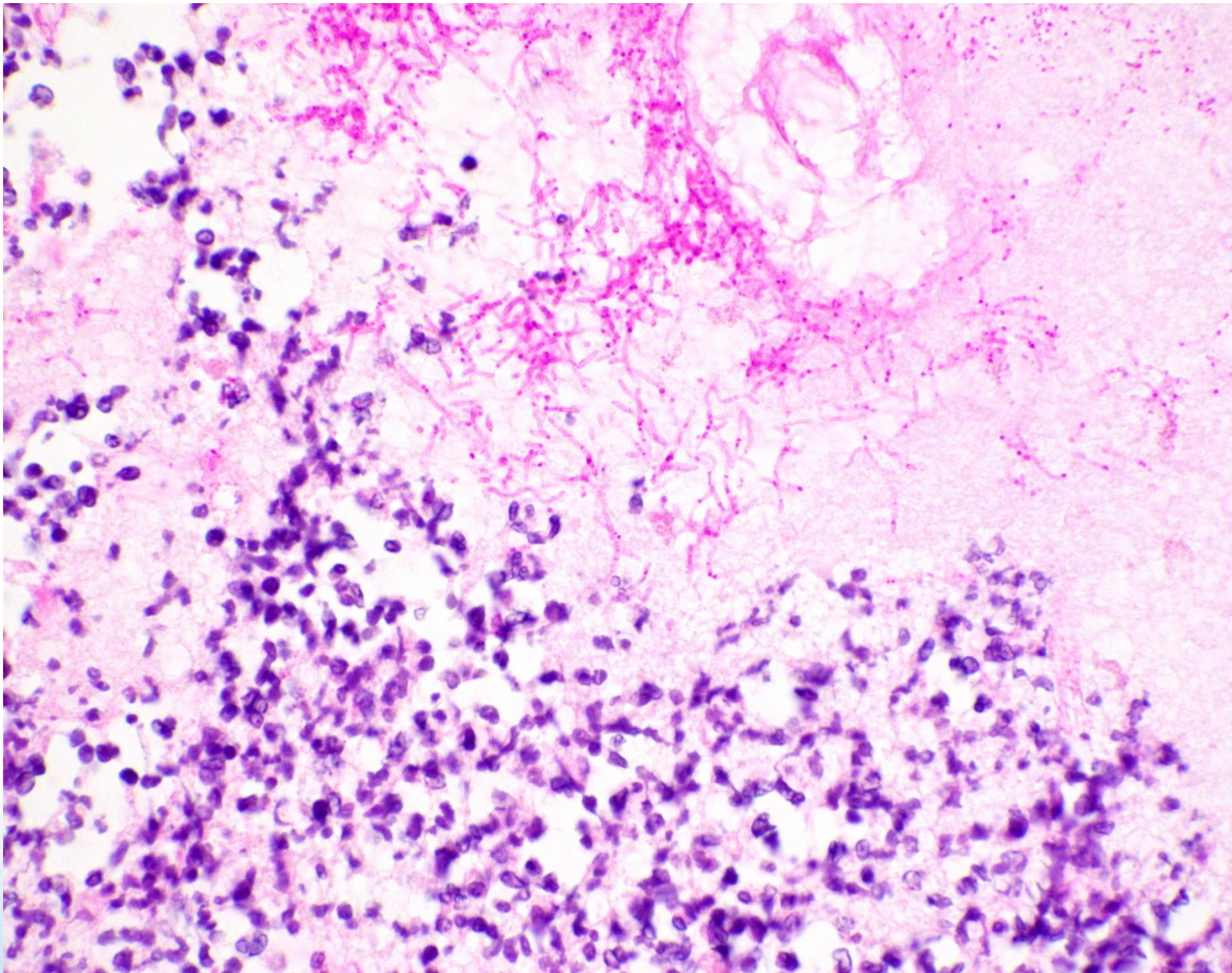
Case 1

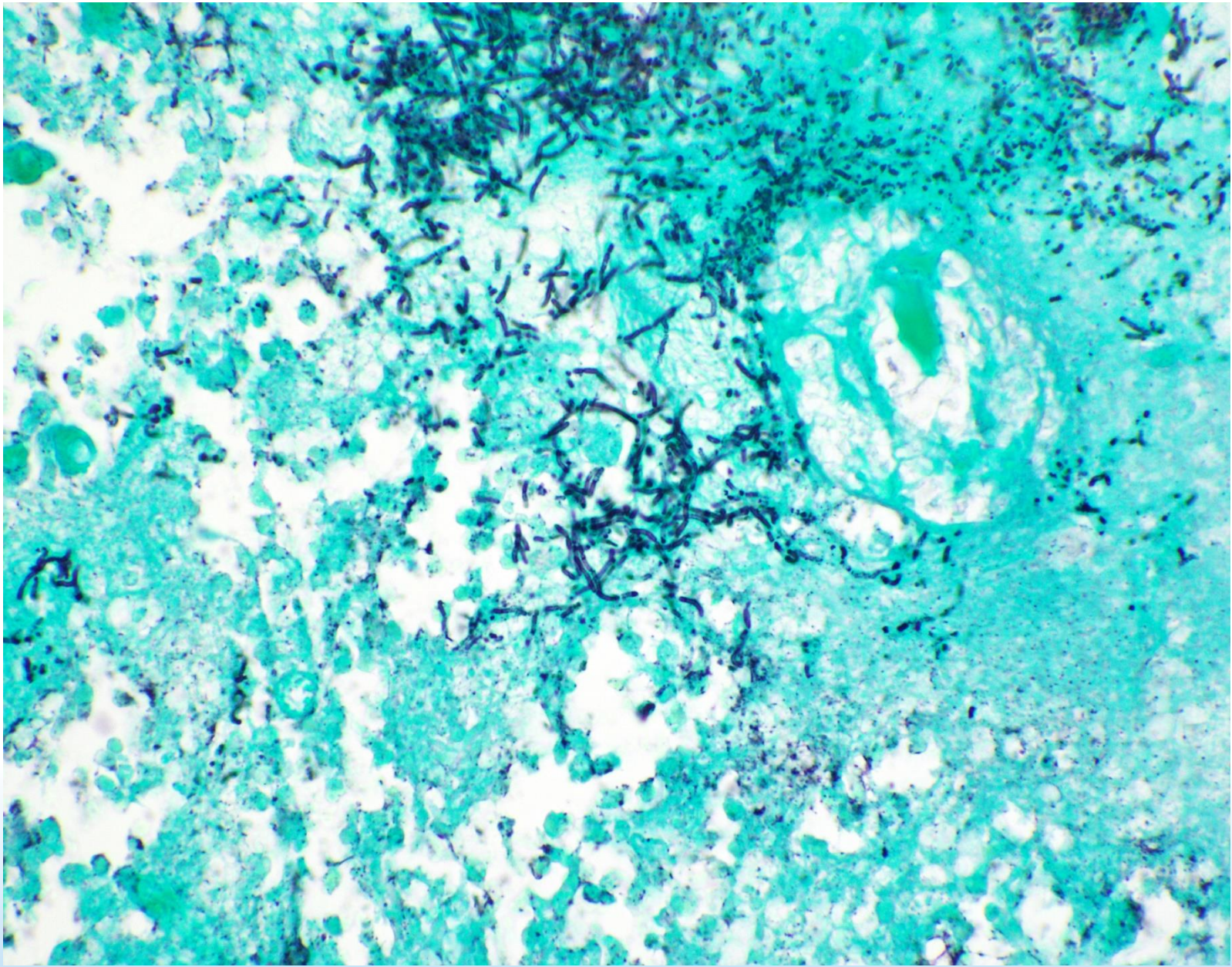
- 32-year-old woman with acute myelogenous leukemia; neutropenia
- Presented with fever, headache, photophobia, blurred vision, right lower extremity pain
- MRI: 2.8 x 1.9 cm ring enhancing lesion with moderate vasogenic edema

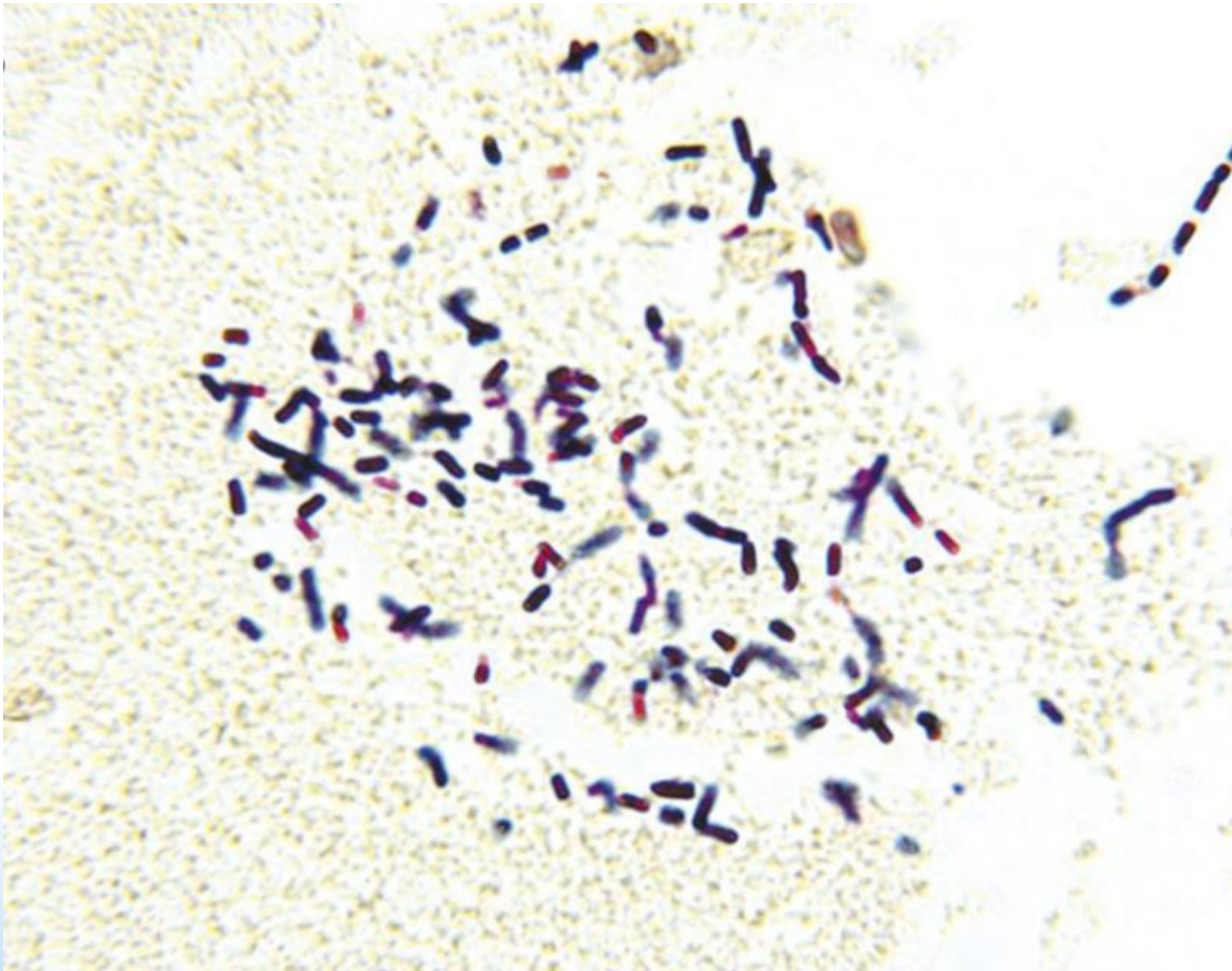












Vodopivec *et al.* (2015) *J Neuropathol Exp Neurol* .74(10):1000-11.



PATHOLOGIC DIAGNOSIS:

A. SPECIMEN DESIGNATED "PARIETAL OCCIPITAL LESION" :

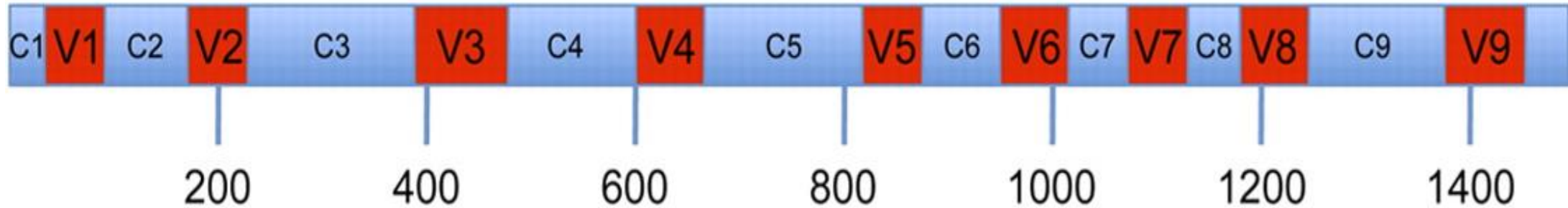
Necroinflammatory debris (abscess contents) with Gram-positive bacilli.

NOTE: Organisms highlighted by GMS and PAS-D stains.
Nocardia (mAFB) stain negative.

Culture:	Negative
16S rRNA (FFPE):	<i>Bacillus cereus</i> species
<i>Bacillus</i> spp. IHC (FFPE):	Positive



16S rRNA gene sequencing



- 16S rRNA gene (1500 bp) contains multiple conserved and hypervariable regions
 - V1: nucleotides 69-99 sufficient to identify *Staphylococcus* spp. and *Streptococcus* spp.
 - V2: nucleotides 137-242 sufficient to identify many other species (110+)
- Targeting full length gene vs V1/V2 determined by specimen (culture isolate, fresh/frozen tissue, FFPE tissue) and sequencing method (Sanger vs NGS)



Histological Screening

Group No.	Histological Findings			
	Gram	GMS	AI	WS
1 (n=43)	+	+	+	nd
2 (n=15)	X	+	+	nd
3 (n=10)	X	X	+	?
4 (n=10)	X	X	X	?

Table 1
16S Ribosomal RNA Sequencing Results by Histologic Findings

Group No.	Histologic Findings			Total Positive Cases	16S Positive, No. (%)		Antibiotic Treatment Effect	
	Gram	GMS	AI		Decalcification		Yes	No
					Yes	No		
1	+	+	+	28/43 (65)	4/11 (36)	24/32 (75)	5/13 (38)	23/30 (77)
2	-	+	+	5/15 (33) ^a	0/2 (0)	5/13 (38)	2/12 (17)	3/3 (100)
3	-	-	+	0/10 (0)	0/2 (0)	0/8 (0)	—	—
4	-	-	-	0/10 (0)	0/3 (0)	0/7 (0)	—	—

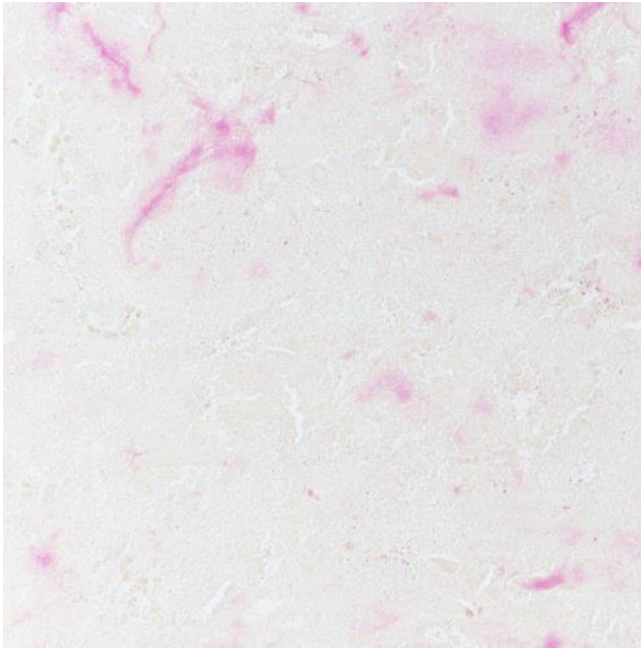
AI, acute inflammation; GMS, Grocott methenamine silver; +, positive; -, negative.

^aIncludes three cases of Gram-negative bacilli (*Cardiobacterium hominis*, *Haemophilus parainfluenzae*, and *Streptobacillus moniliformis*).

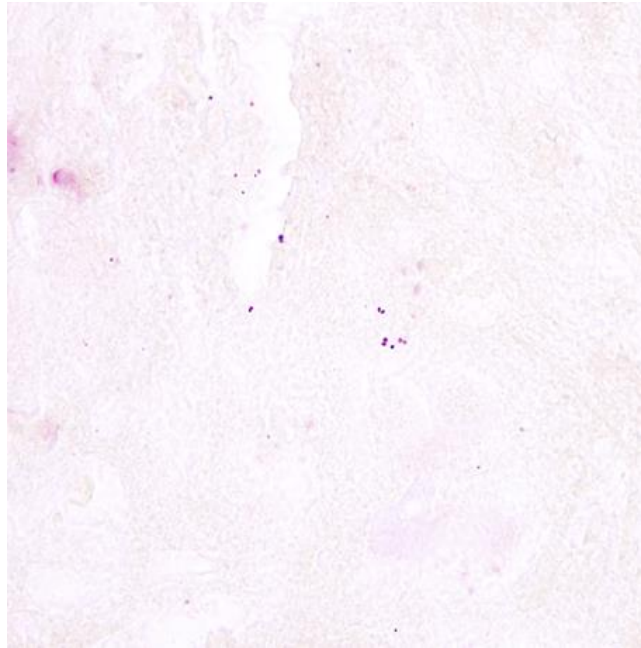Solomon et al. (2019) *Am J Clin Pathol.* 152(4):431-437.



Minimum Number of Organisms

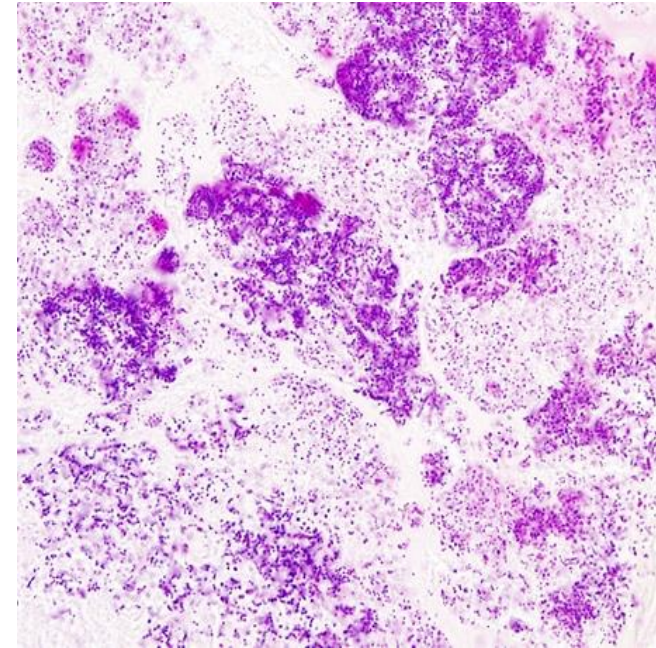


NO (0) ORGANISMS
0/10 (0%) positive



RARE (1+) ORGANISMS
2/3 (66%) positive
1 negative case decalcified

Failed at 1:2 dilution




ABUNDANT (2+) ORGANISMS
31/55 (56%) positive overall

Detected to 1:16 dilution



Environmental Contamination



33/78 (42%) samples showed evidence of environmental contamination (including 9/10 negative controls!)

Common Contaminants

Meiothermus silvanus

Geobacillus jurassicus

Acinetobacter radioresistens

Sphingomonas hankookensis



Summary – 16S rRNA sequencing

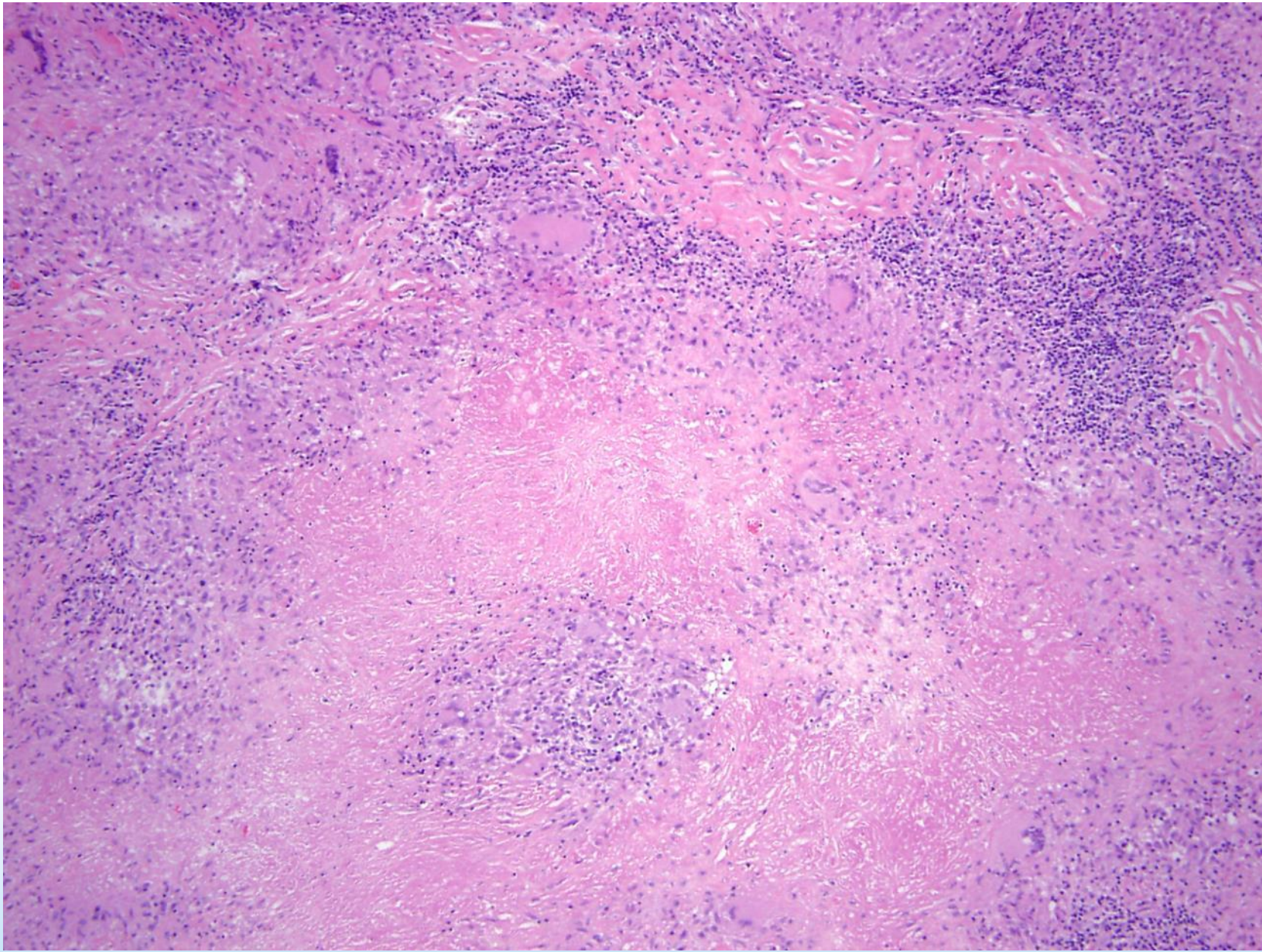
- Useful for detecting bacteria directly from primary samples including common surgical pathology specimens (e.g. brain abscess, endocarditis)
- Diagnostic yield markedly increased by the presence of organisms on histological review
- Submit frozen tissue (if saved) or FFPE
- Optimal timing usually after routine aerobic cultures are finalized (5 days)

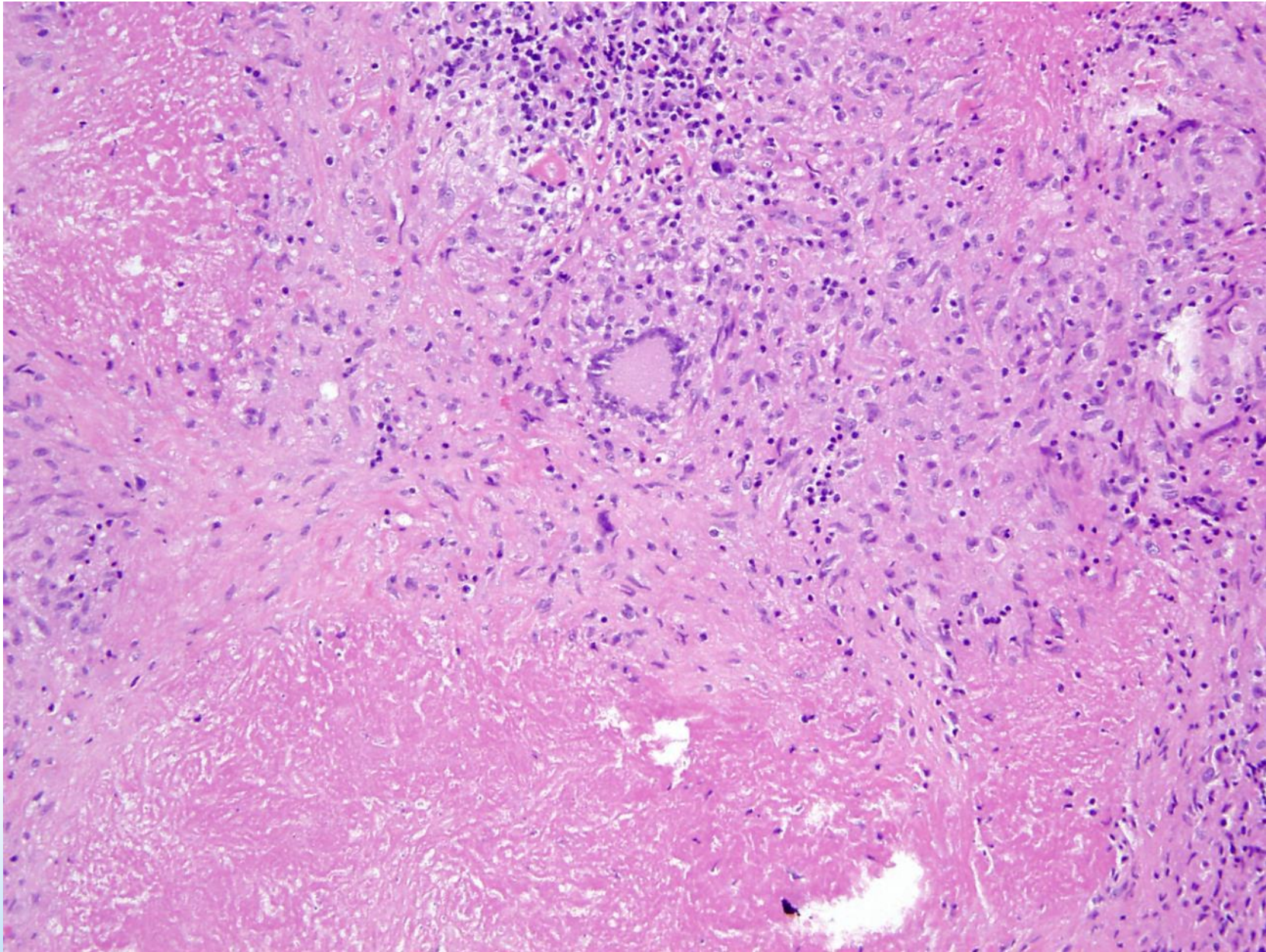


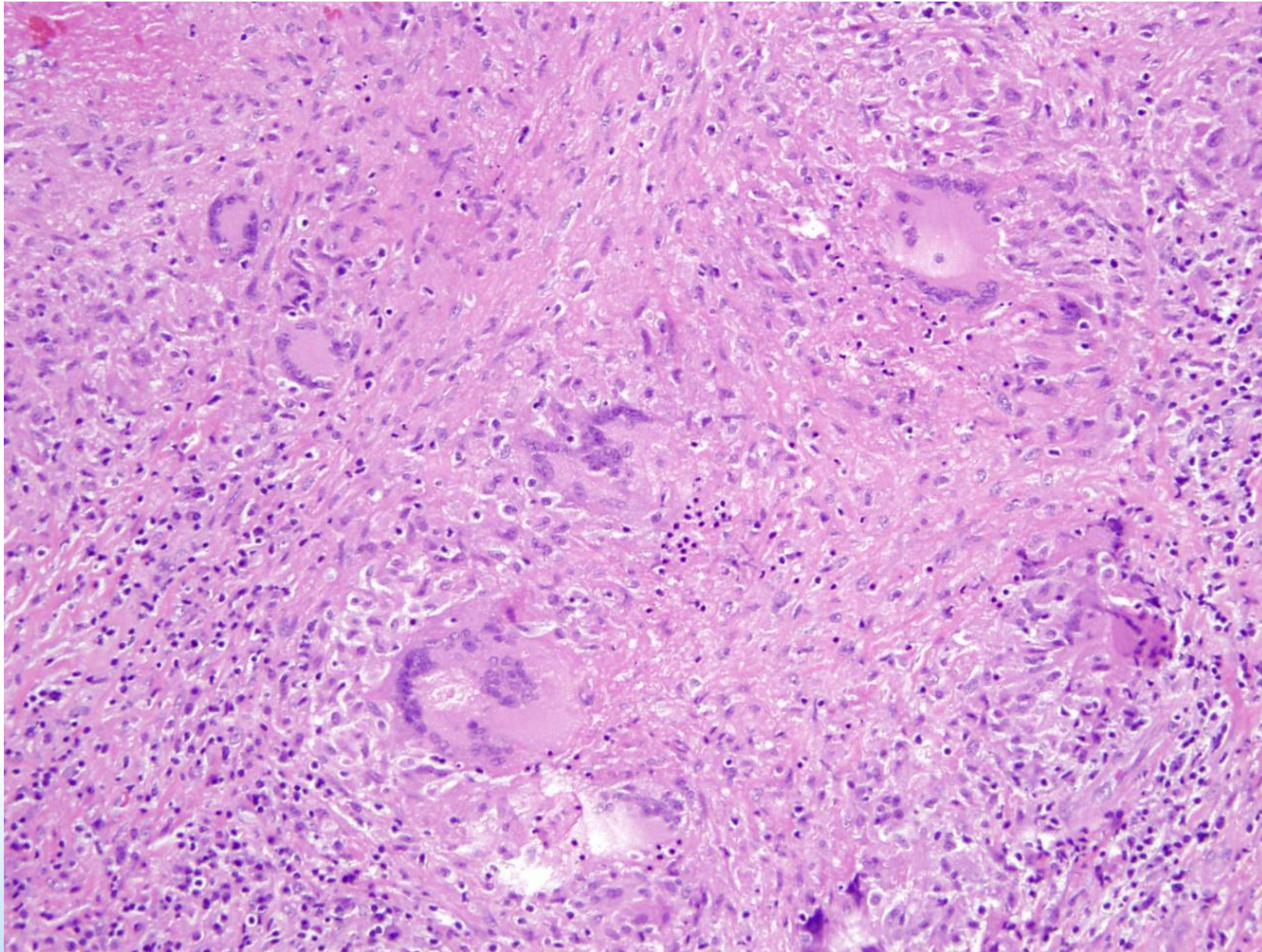
Case 2

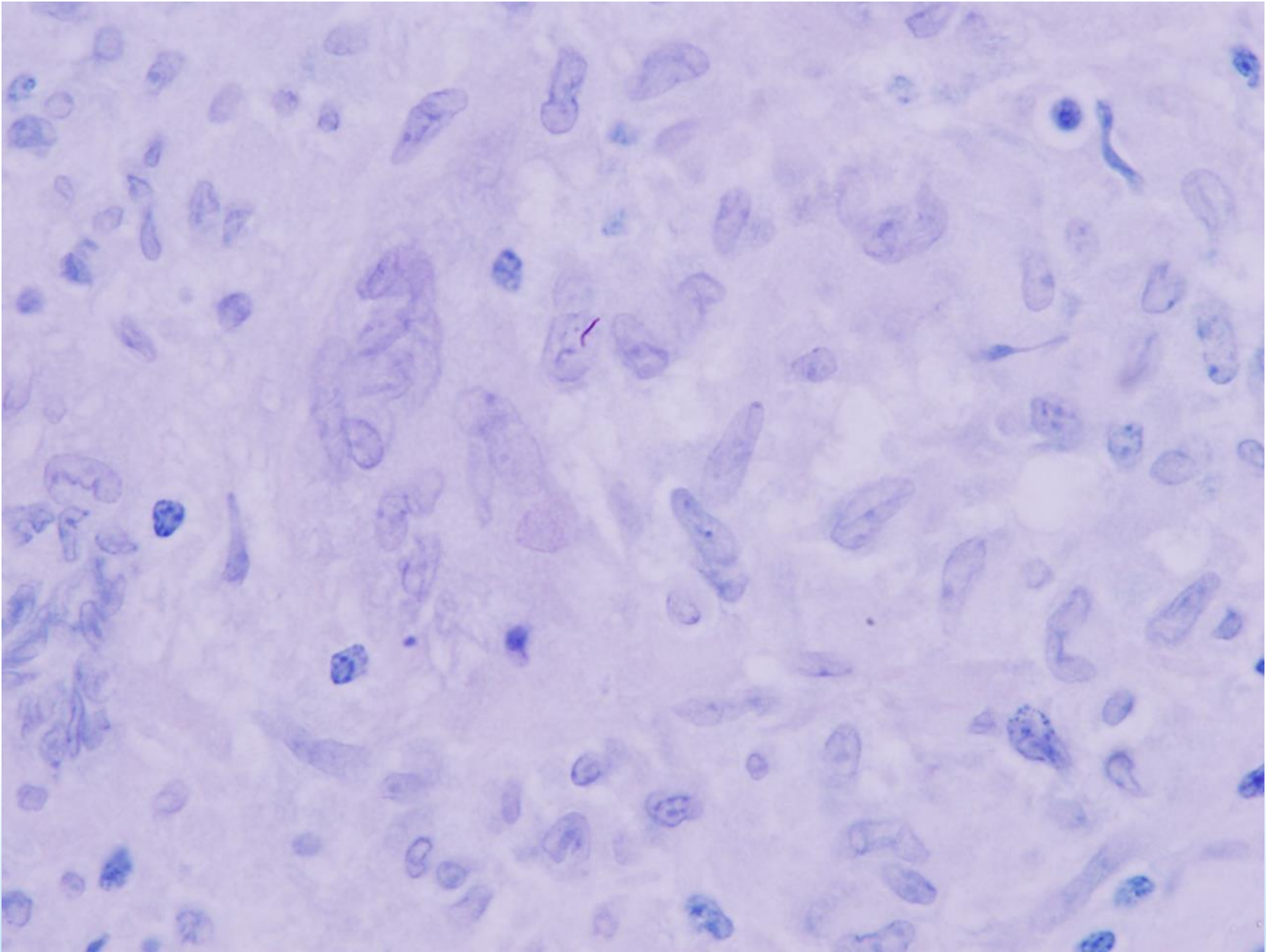
- 36-year-old woman with no significant past medical history
- Presented with 5 weeks of headaches unresponsive to triptans
- Lived in Philippines for 6 years during 20s to attend school
- MRI: Right frontal dural based mass, along right frontal convexity with associated edema (no images available)











PATHOLOGIC DIAGNOSIS:

A. SPECIMEN DESIGNATED "LEFT FRONTAL BRAIN MASS" :

Necrotizing granulomas containing AFP-positive organisms involving dura mater consistent with TUBERCULOUS PACHYMENINGITIS

Note: Acid fast bacilli identified by ZN AFB stain.
Gram, PAS-D, and MSS stains were negative.

Culture: *Mycobacterium tuberculosis* complex

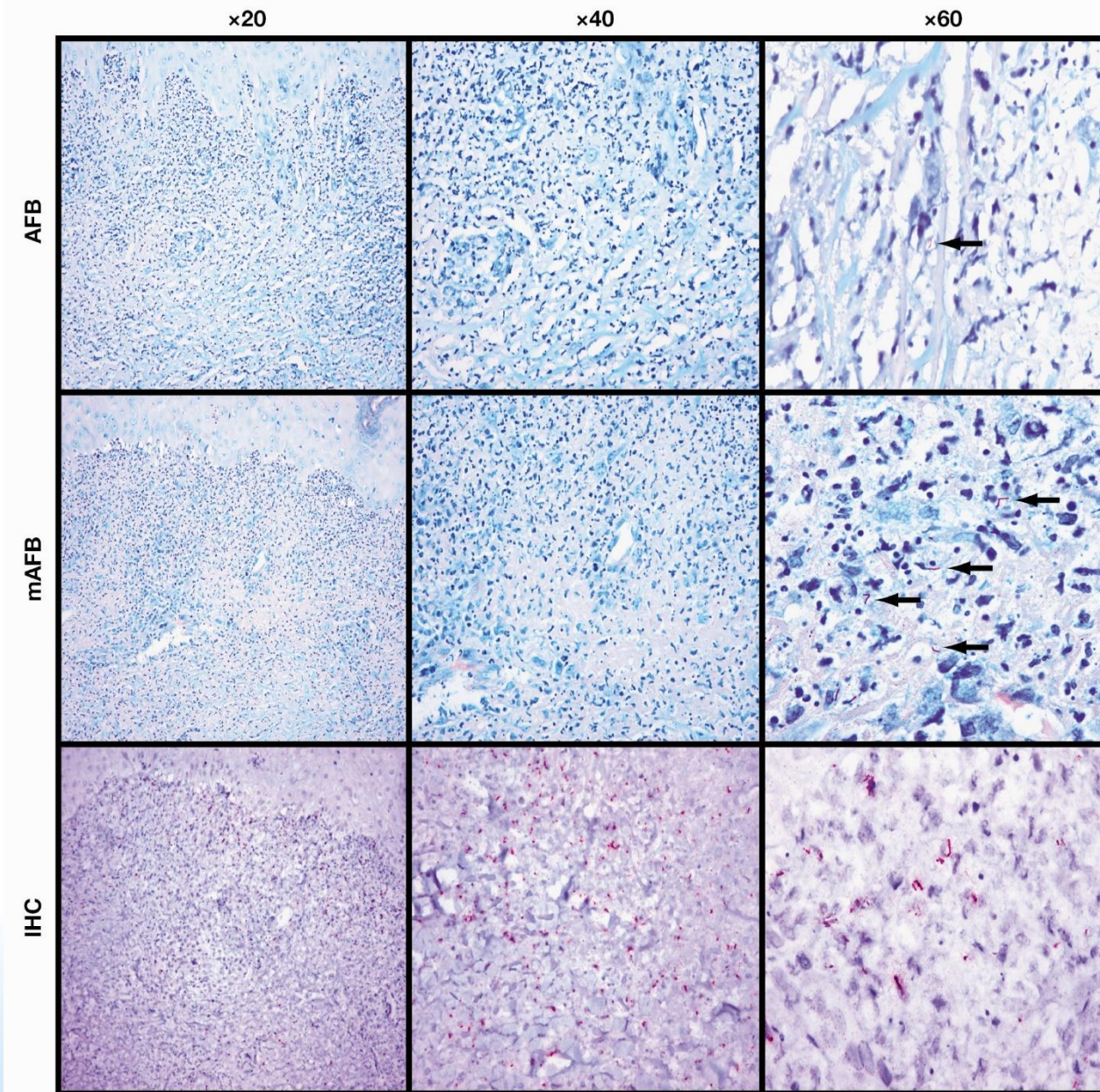


Mycobacterial Molecular Testing

- *16S rRNA* gene
 - Single copy, highly conserved
 - Can distinguish most *Mycobacterium* spp.
- *hsp65*
 - Shorter sequence (134 bp), less conserved
 - Less susceptible to interference from formalin-fixation
- *IS6110*
 - Multicopy gene (70 bp) present in MTB complex
 - Increased sensitivity compared to non-tuberculous mycobacteria
- Human *beta-globin* (DNA quality indicator)



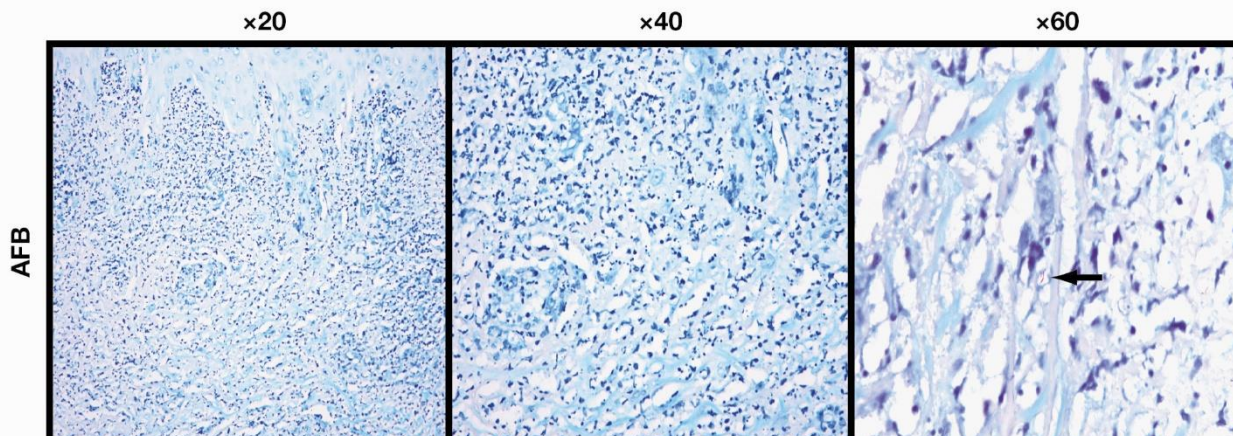
AFB (Ziehl-Neelsen) vs Fite-Farcao (mAFB) vs Mycobacteria IHC



Crothers *et al.* (2021) *Am J Clin Pathol.* 4;155(1):97-105.



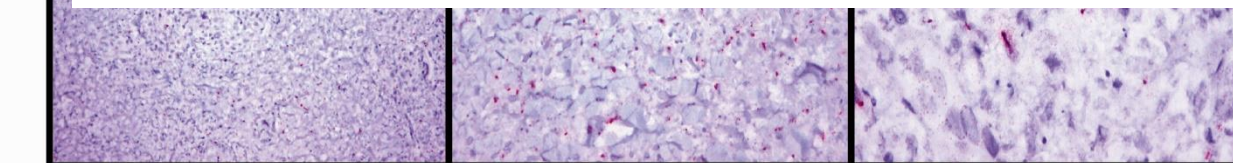
AFB (Ziehl-Neelsen) vs Fite-Farcao (mAFB) vs Mycobacteria IHC



Sensitivity and Specificity of Mycobacterial IHC, AFB, and mAFB Stains

	Characteristic	TP, No.	FP, No.	FN, No.	TN, No.	Total, No.	Sensitivity (95% CI), %	Specificity (95% CI), %
mAFB	Mycobacterial IHC vs culture/PCR	29	25	27	99	180	52 (38-65)	80 (71-86)
	AFB vs culture/PCR	9	8	33	90	140	21 (11-37)	92 (84-96)
	mAFB vs culture/PCR	23	15	15	76	129	61 (43-76)	84 (74-90)
	Mycobacterial IHC vs culture/PCR/AFB/mAFB	46	12	37	172	267	55 (44-66)	93 (89-96)

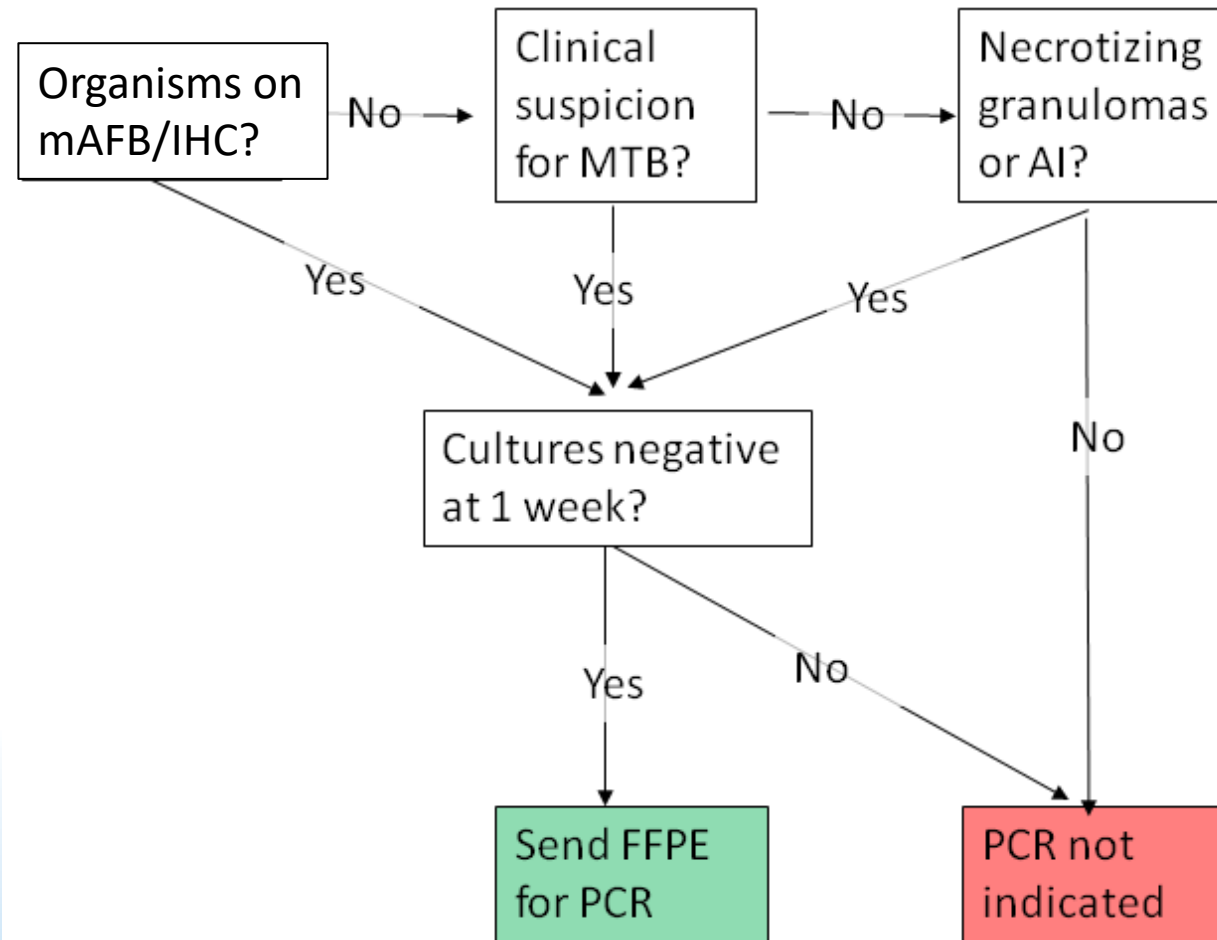
AFB, acid-fast bacilli; CI, confidence interval; FN, false negative; FP, false positive; IHC, immunohistochemistry; mAFB, modified acid-fast bacilli; PCR, polymerase chain reaction; TM, true negative; TP, true positive.



Crothers *et al.* (2021) *Am J Clin Pathol.* 4;155(1):97-105.



Mycobacterial Molecular Testing Algorithm



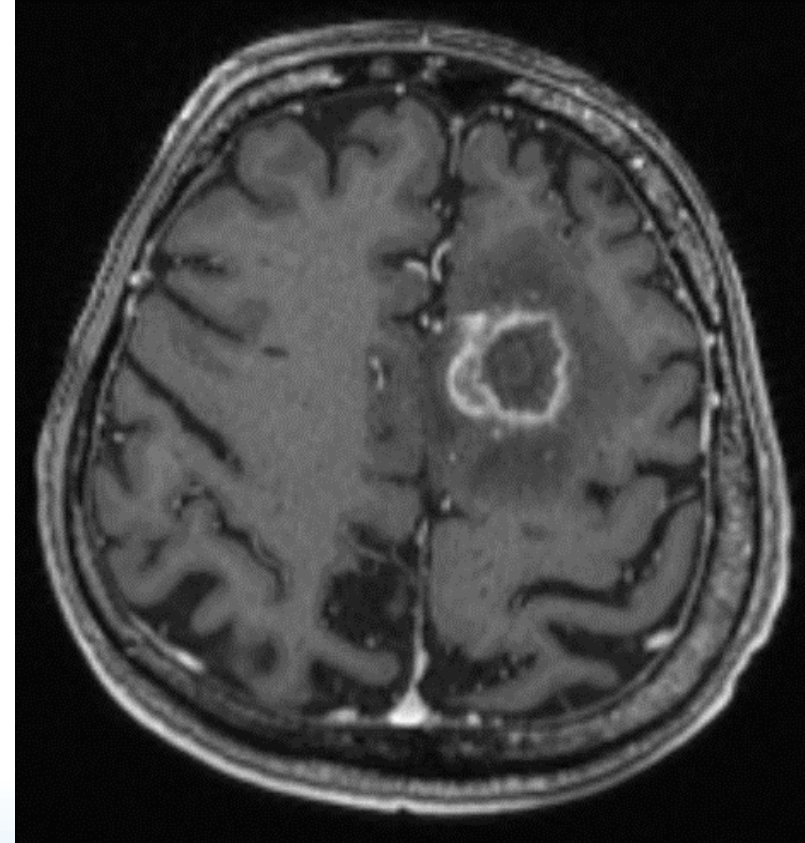
Summary – Mycobacterial Testing

- Multi-target sequencing approach can identify MTB and NTM at low concentrations
- Identification of unusual organisms should raise concern for environmental contamination
- Presence of bacilli on mycobacteria IHC, mAFB, or AFB stains correlates with higher yield
- Optimal timing after ~1 week to exclude rapid growers



Case 3

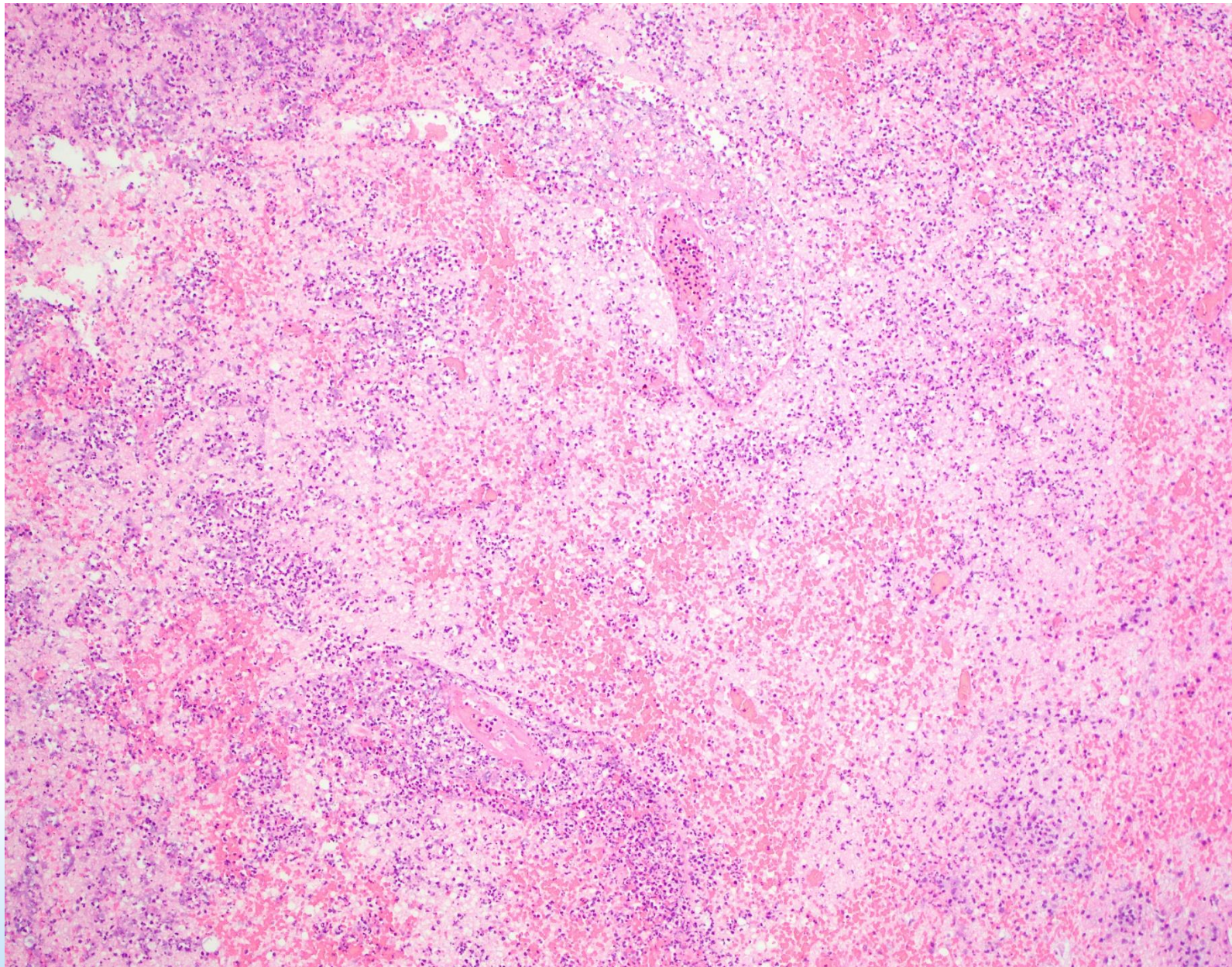
- 74-year-old man with chronic lymphocytic leukemia (on ibrutinib) and AFib presented with impaired speech, nausea/vomiting, and possible seizures
- MRI: irregularly enhancing 2.4 x 2.5 x 2.9 cm lesion in left frontal centrum semiovale with central restricted diffusion and surrounding vasogenic edema
- Also found to have lung nodules (possibly post infectious, recent history of pneumonia)

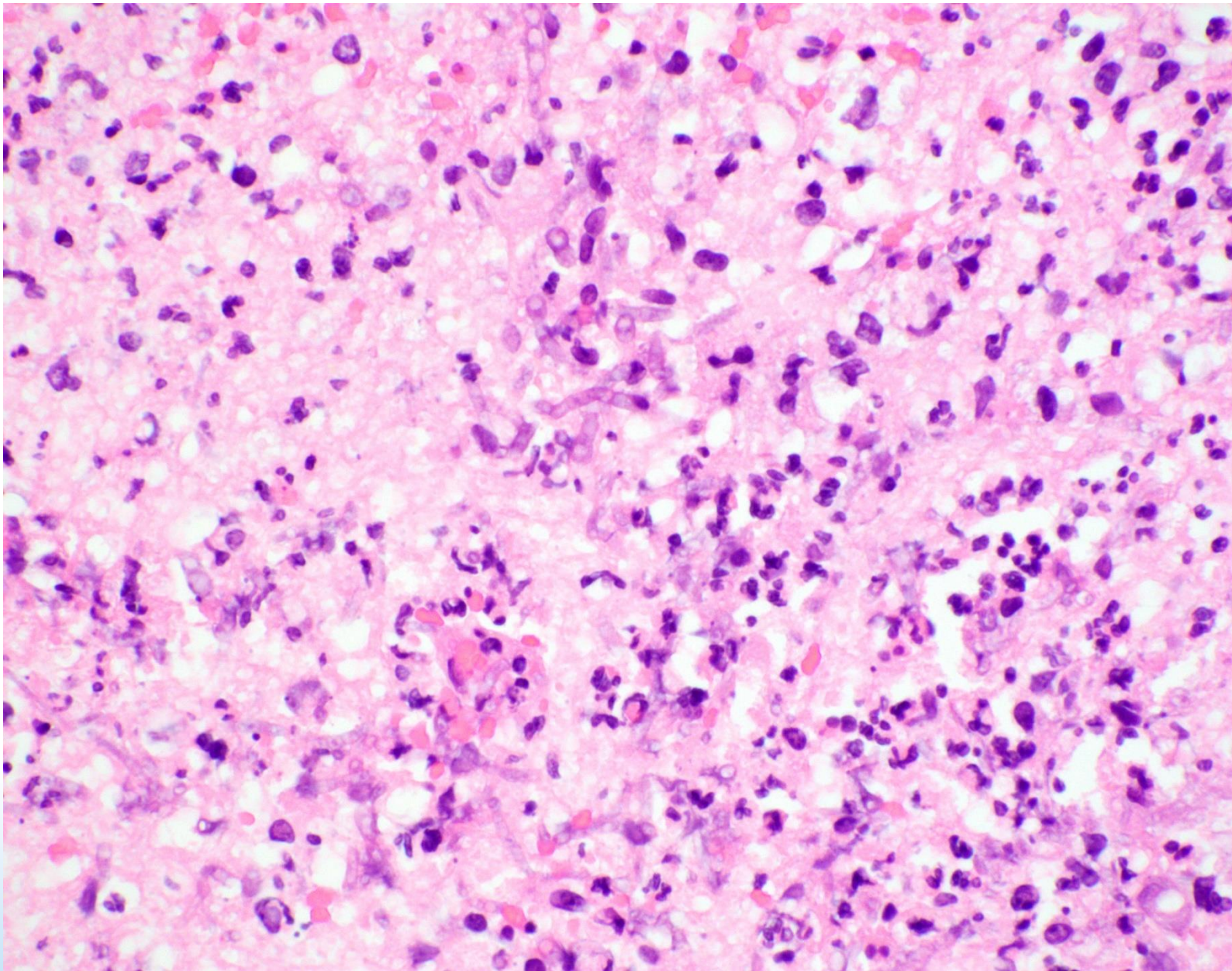


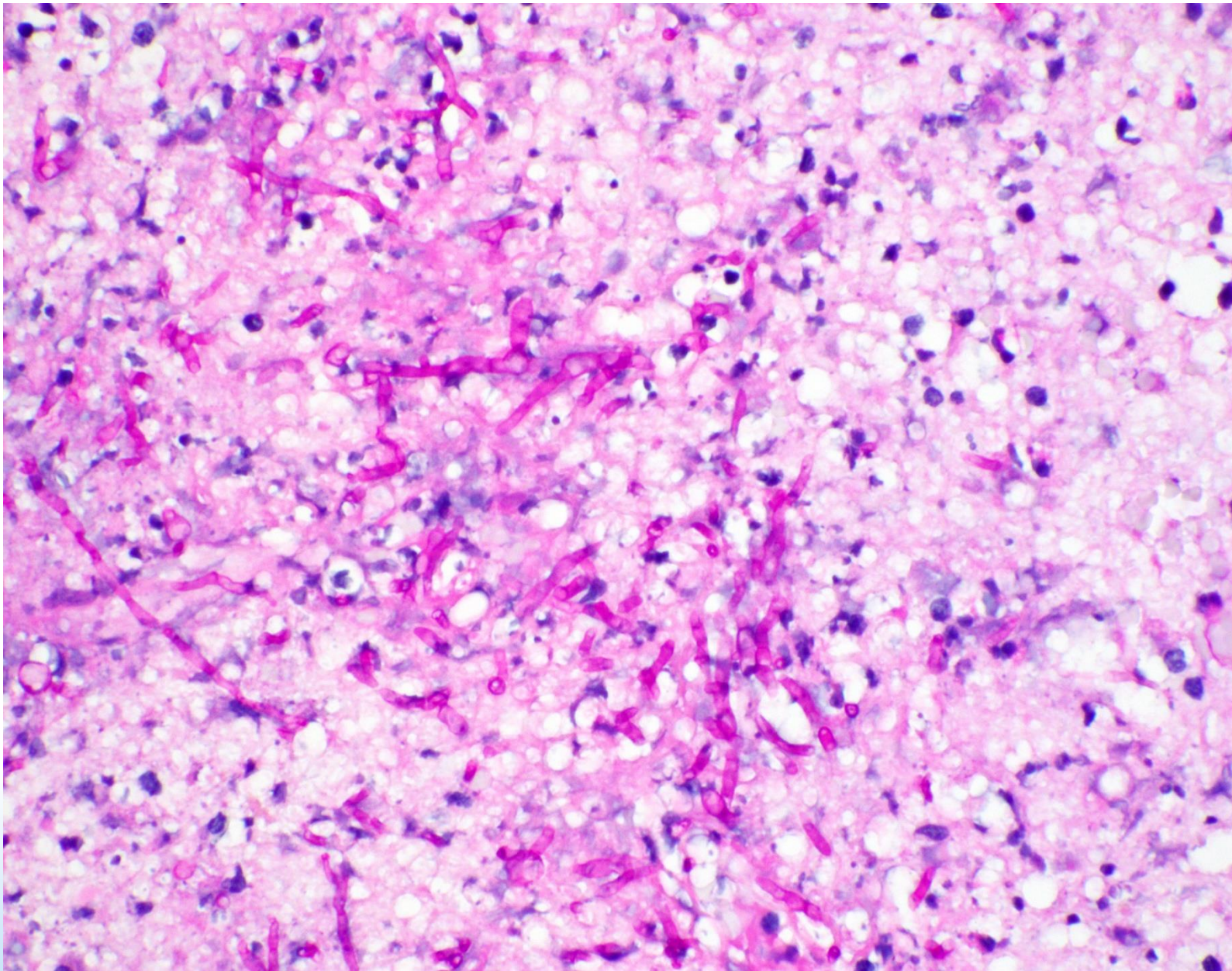
Review Virtual Slide

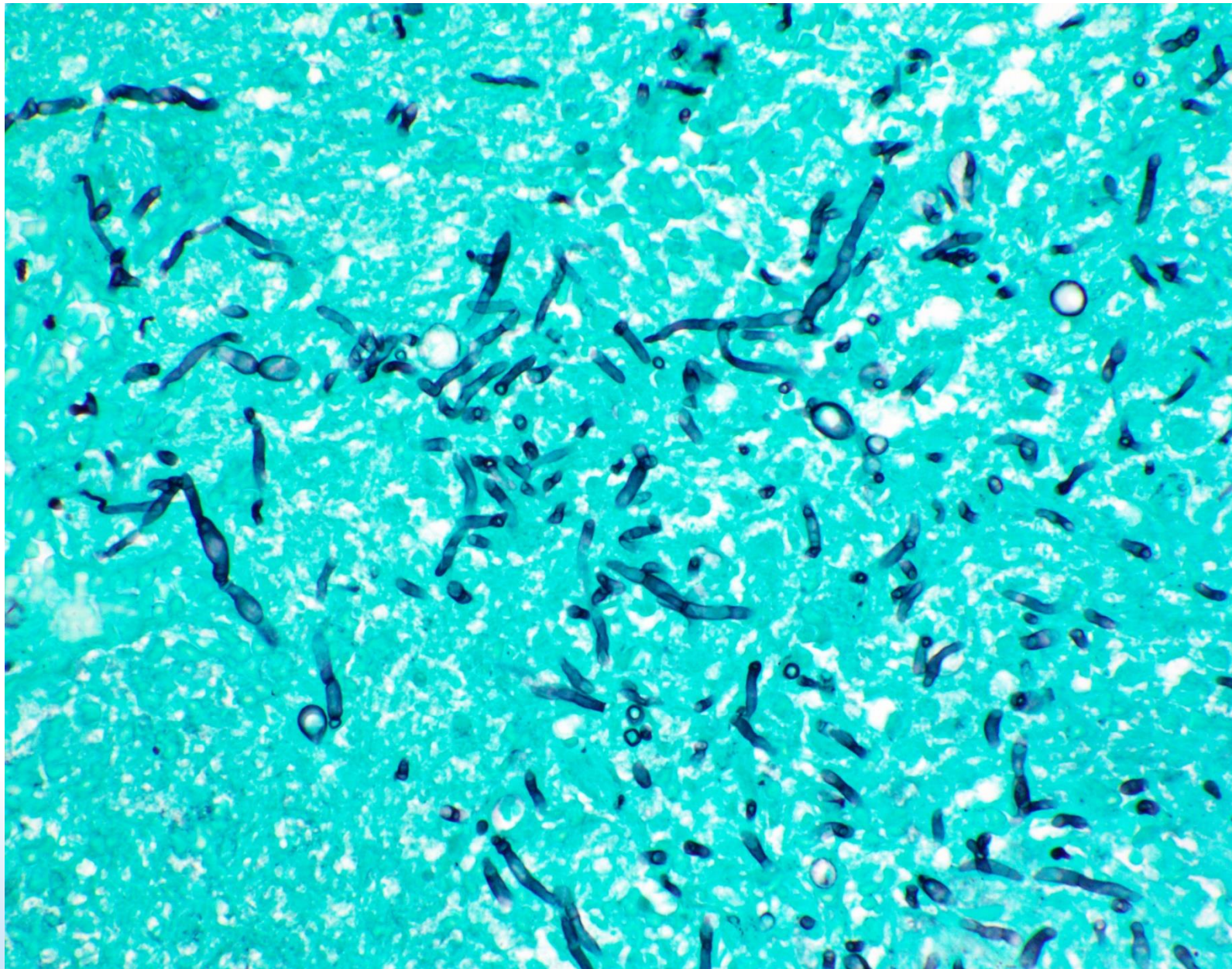
<https://pathpresenter.net/#/public/presentation/display?token=00b87721>











PATHOLOGIC DIAGNOSIS:

B. SPECIMEN DESIGNATED "LEFT FRONTAL MASS" :

Fungal abscess

NOTE: MSS and PAS-D highlight abundant fungal forms involving blood vessels and brain parenchyma, including narrow hyphae with abundant septations and irregular branching, numerous chlamydoconidia, and occasional pyriform conidia.

Gram and Fite (mAFB) stains are negative.

These findings are morphologically compatible with *Scedosporium* or *Lomentospora* sp., while *Fusarium*, *Candida*, *Aspergillus*, and other hyaline molds remain lower on the differential.

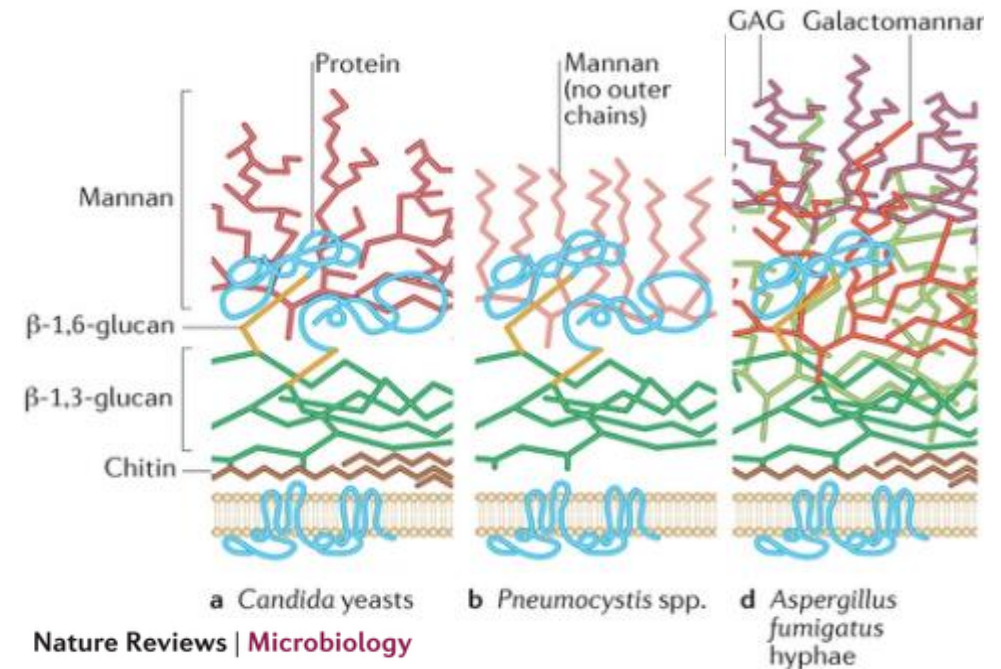
Culture: Positive for mold

Sequencing (TUB, CAL genes): *Scedosporium boydii* (member of *Scedosporium apiospermum* complex)



Laboratory Testing

- Serology
 - Antigen/antibody detection
 - *Cryptococcus*
 - *Histoplasma*
 - *Blastomyces*
 - *Coccidioides*
 - Fungal wall components
 - Galactomannan
 - (1,3)- β -D-glucan



Erwig and Gow (2016) *Nat Rev Microbiol.* 14(3), 163–176



Filamentous Fungi

Broad ribbon-like hyphae,
pauciseptate, 90-degree
angle branching

Mucorales order:
Mucor, *Rhizopus*, *Absidia*,
Cunninghamella

Galactomannan –
(1,3)- β -D-glucan –

Uniform septate hyphae that
branch at acute angles

Aspergillus

Galactomannan +
(1,3)- β -D-glucan +

Scedosporium,
Fusarium, etc.

Galactomannan –
(1,3)- β -D-glucan +
*Cultures/Molecular

Hyphae, pseudohyphae,
Gram-positive yeast

Candida

Galactomannan –
(1,3)- β -D-glucan +

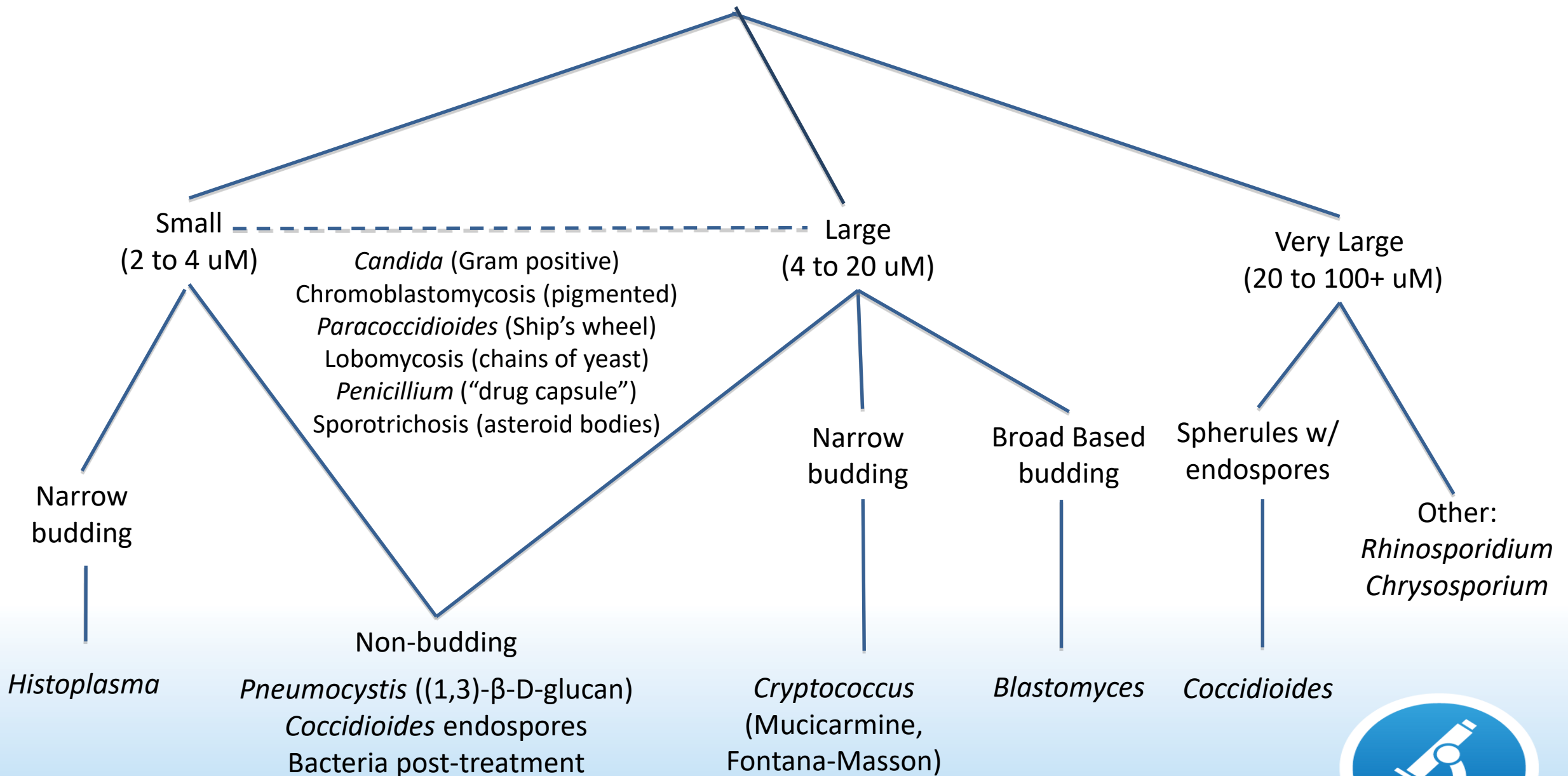
Pigmented hyphae,
yeast (Fontana
Masson-positive)

Phaeohyphomycosis:
Alternaria, *Bipolaris*,
Curvularia, *Exophiala*, etc.

Galactomannan –
(1,3)- β -D-glucan +

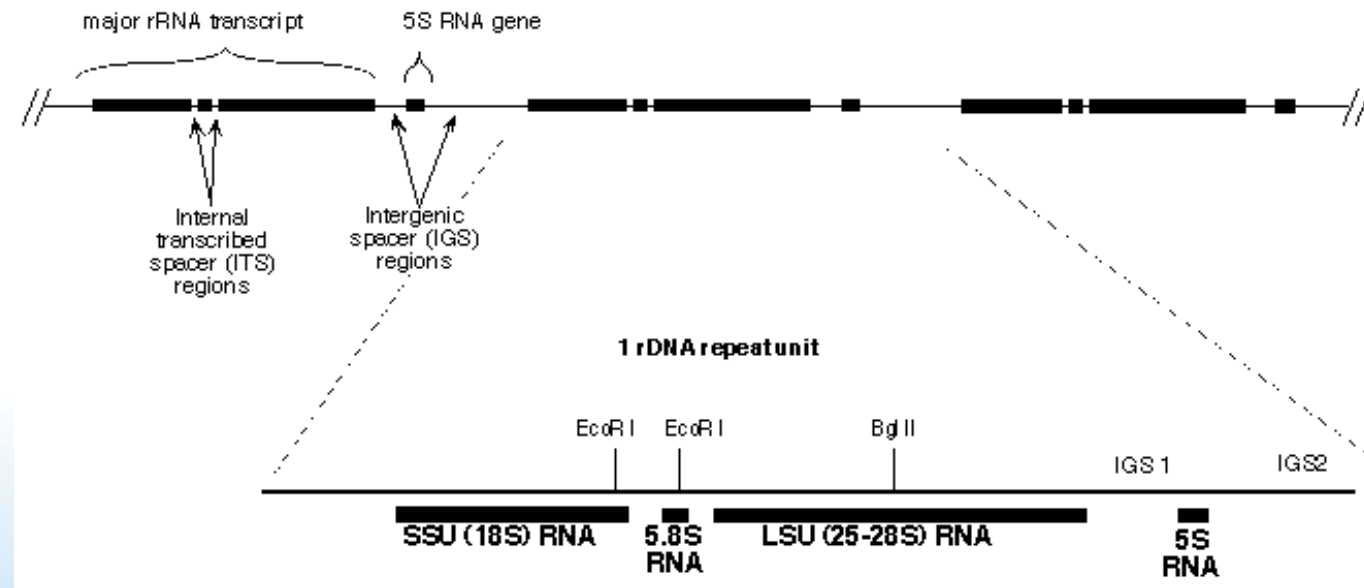


Yeast Forms in Tissue



Fungal Sequencing

- Species directed PCR
 - e.g. *Cryptococcus* spp.
 - Higher sensitivity; requires high clinical suspicion
- Broad spectrum
 - 18S
 - ITS
 - D1/D2



<http://sites.biology.duke.edu/fungi/mycolab/primers.htm>



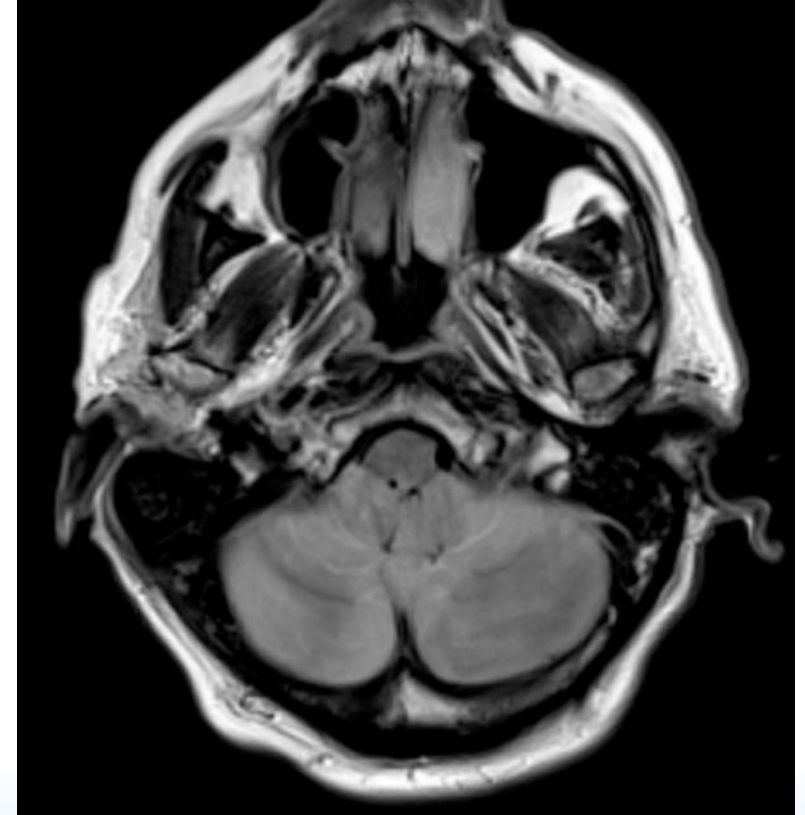
Summary – Fungal Sequencing

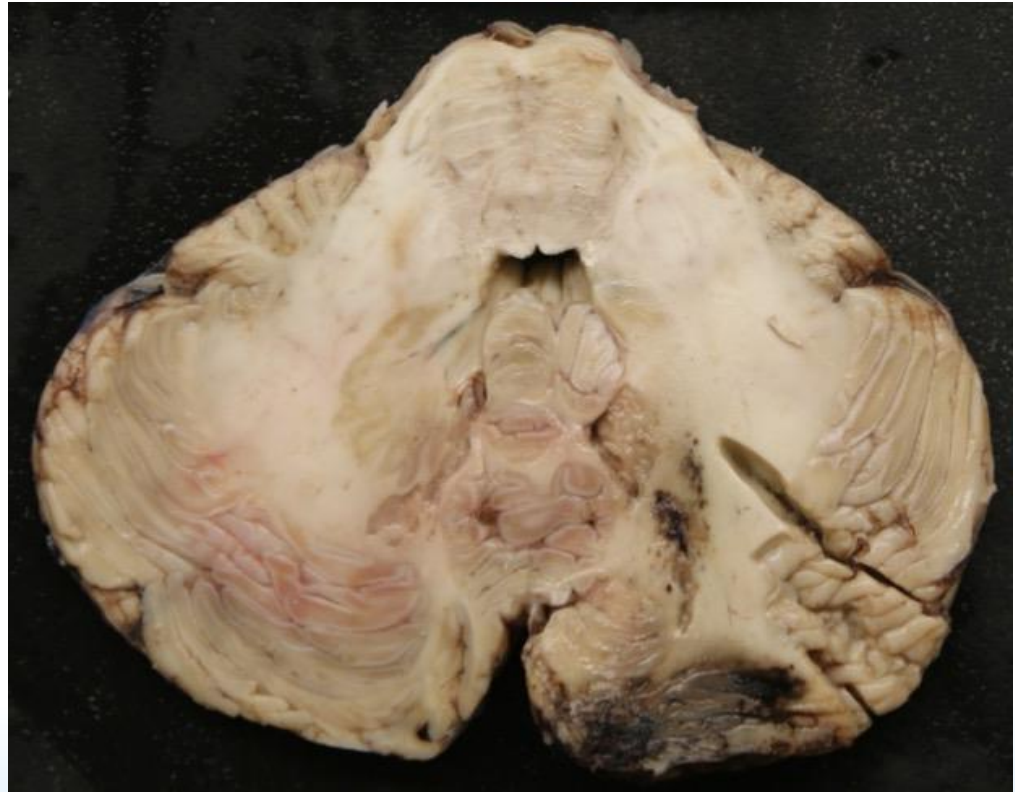
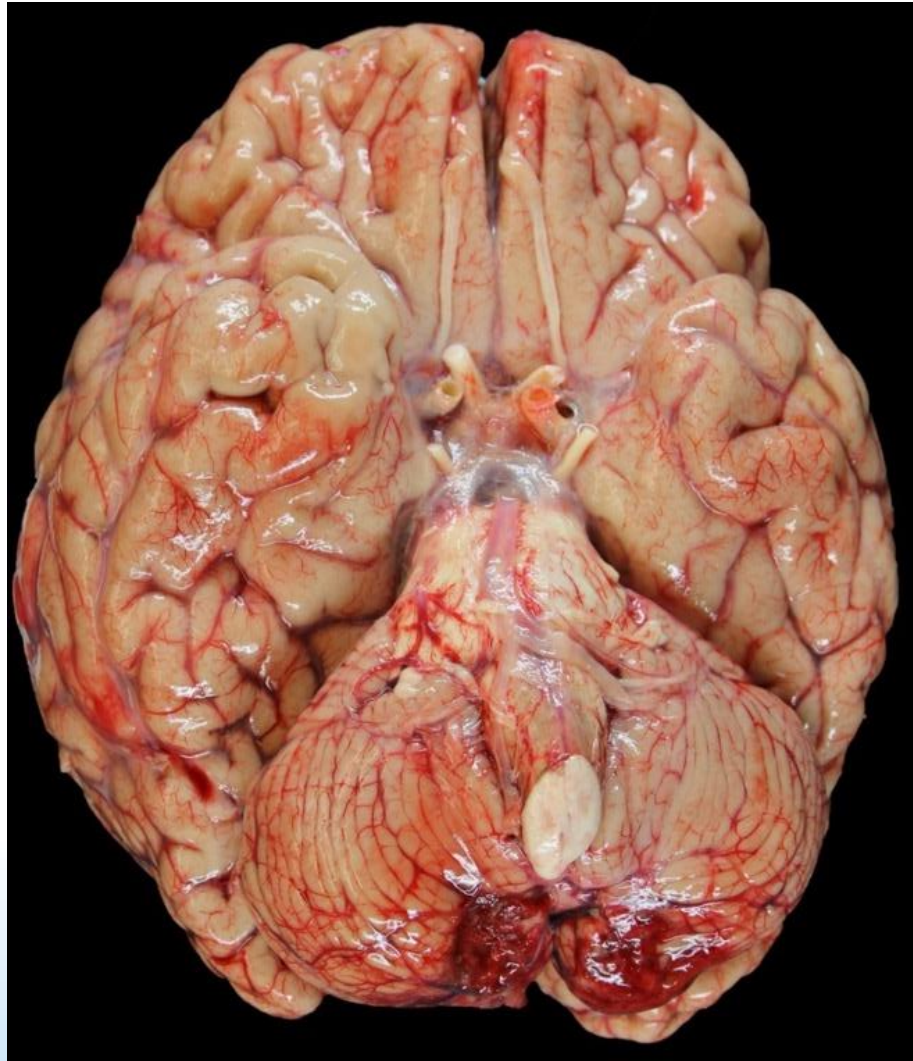
- Very useful for identification of slow growing molds or species difficult to identify based on morphology
- Identification of unusual organisms should raise concern for environmental contamination, but may also represent disease in immunocompromised patients
- Tissue specimens without observable organisms are usually false positives
- Timing depends on clinical urgency; typically after 1-2 weeks if cultures negative or unable to further classify

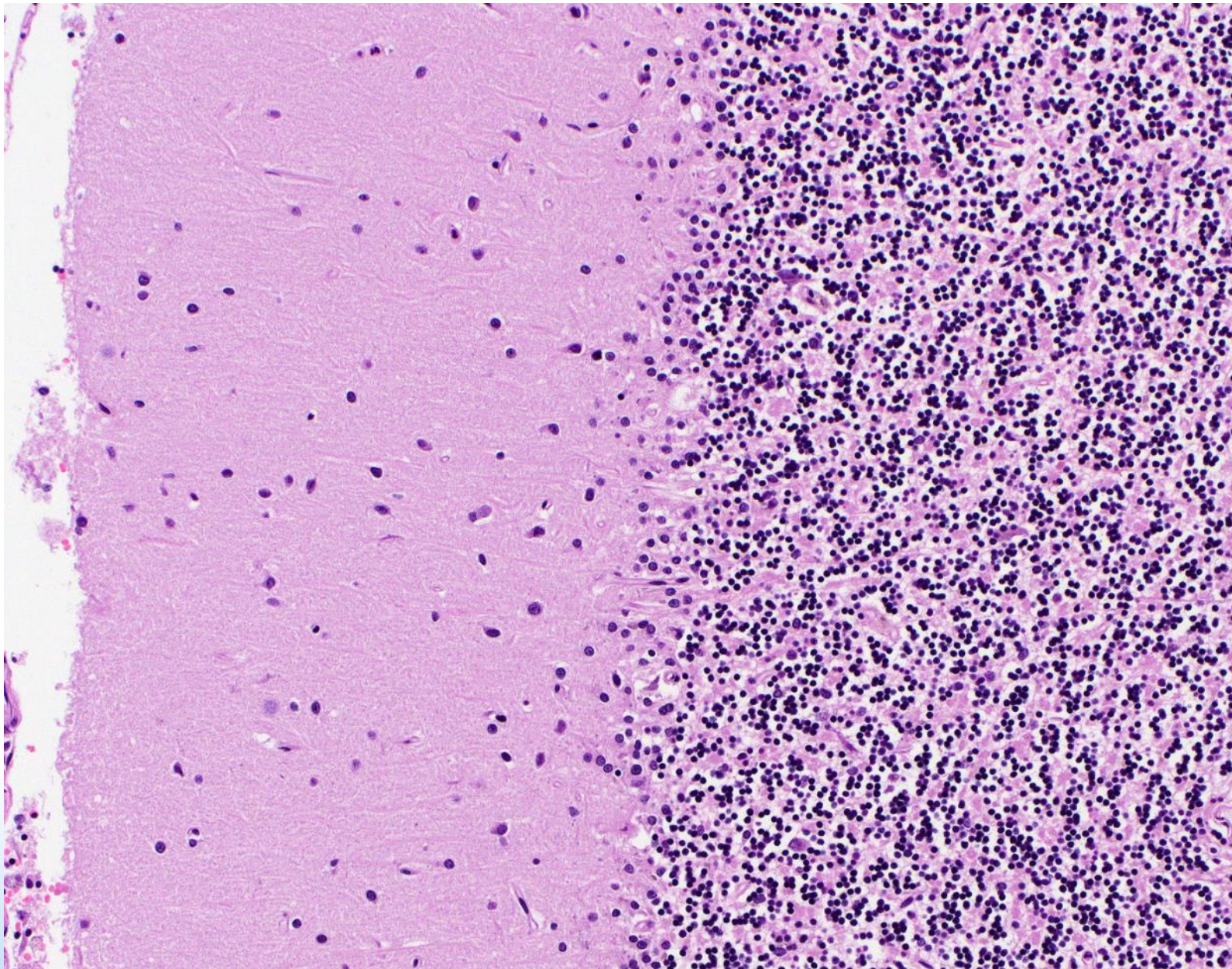


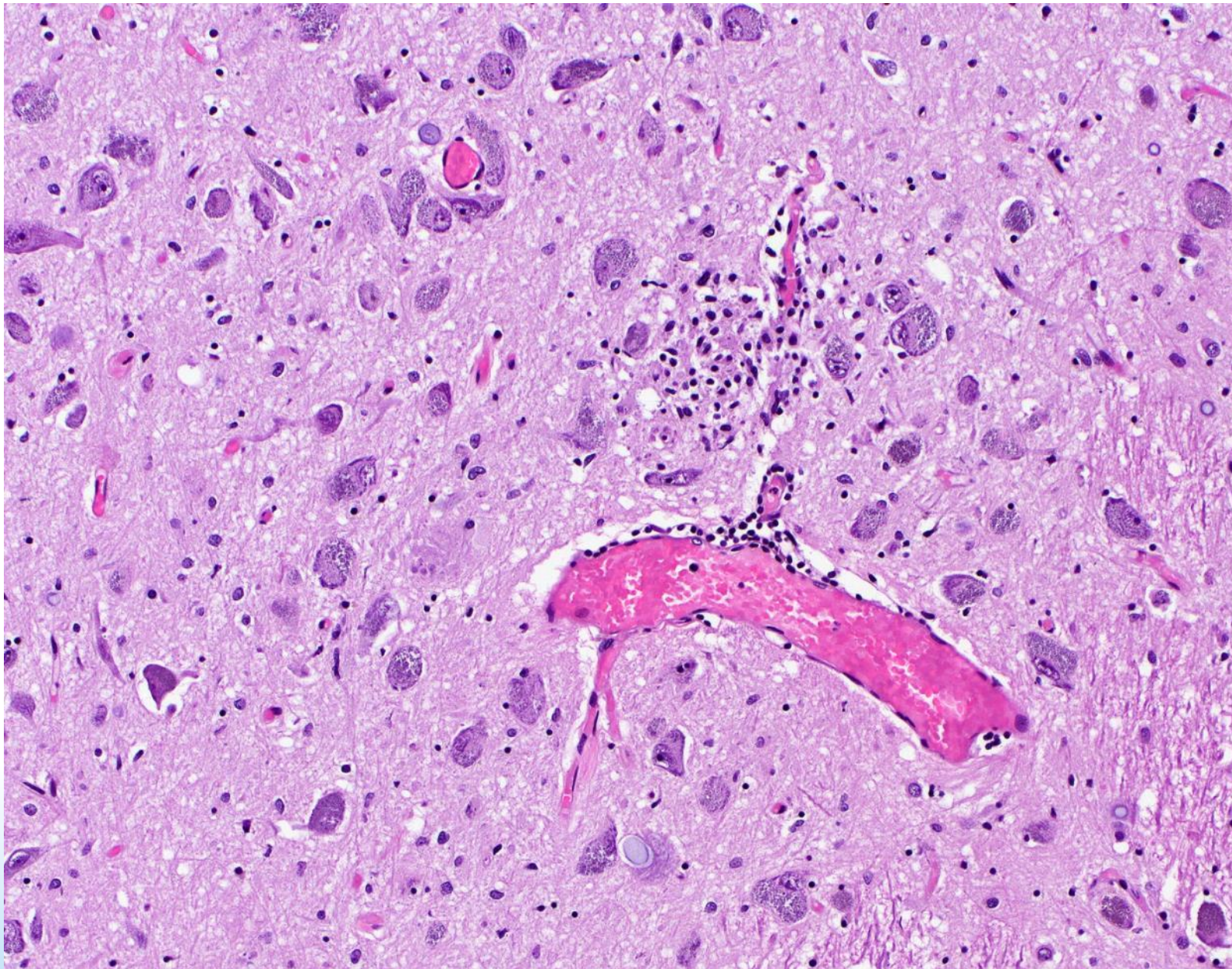
Case 4

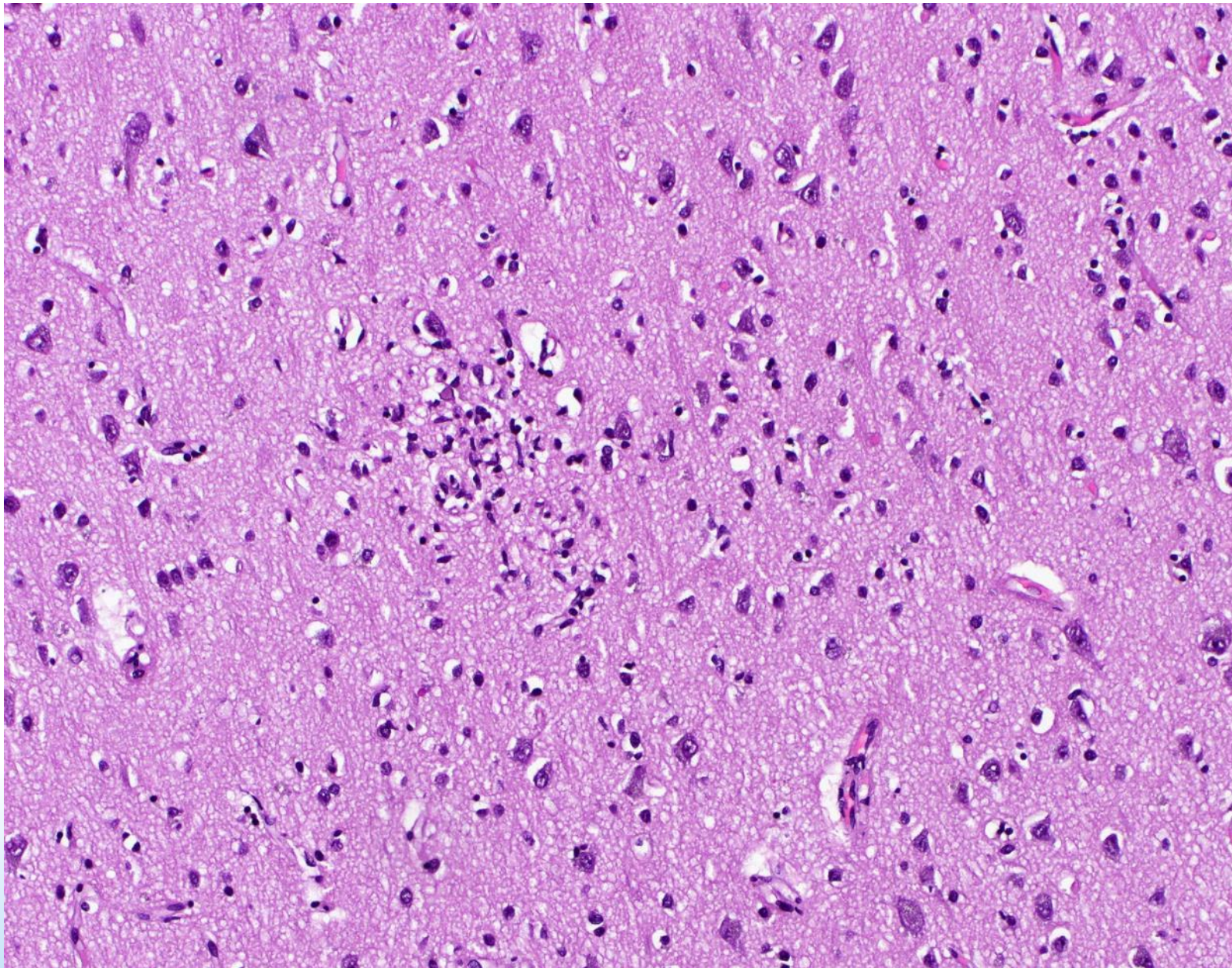
- 65-year-old man with history of grade 2 follicular lymphoma (on rituximab) and occasional tick bites
- Presented with fever and subsequently developed slurred speech followed by neck stiffness
- LP: Normal glucose, elevated protein, mix of lymphocytes and neutrophils
- MRI: Cerebellum with diffuse swelling, obstructive hydrocephalus, leptomeningeal enhancement; additional signal abnormality within midbrain and thalami

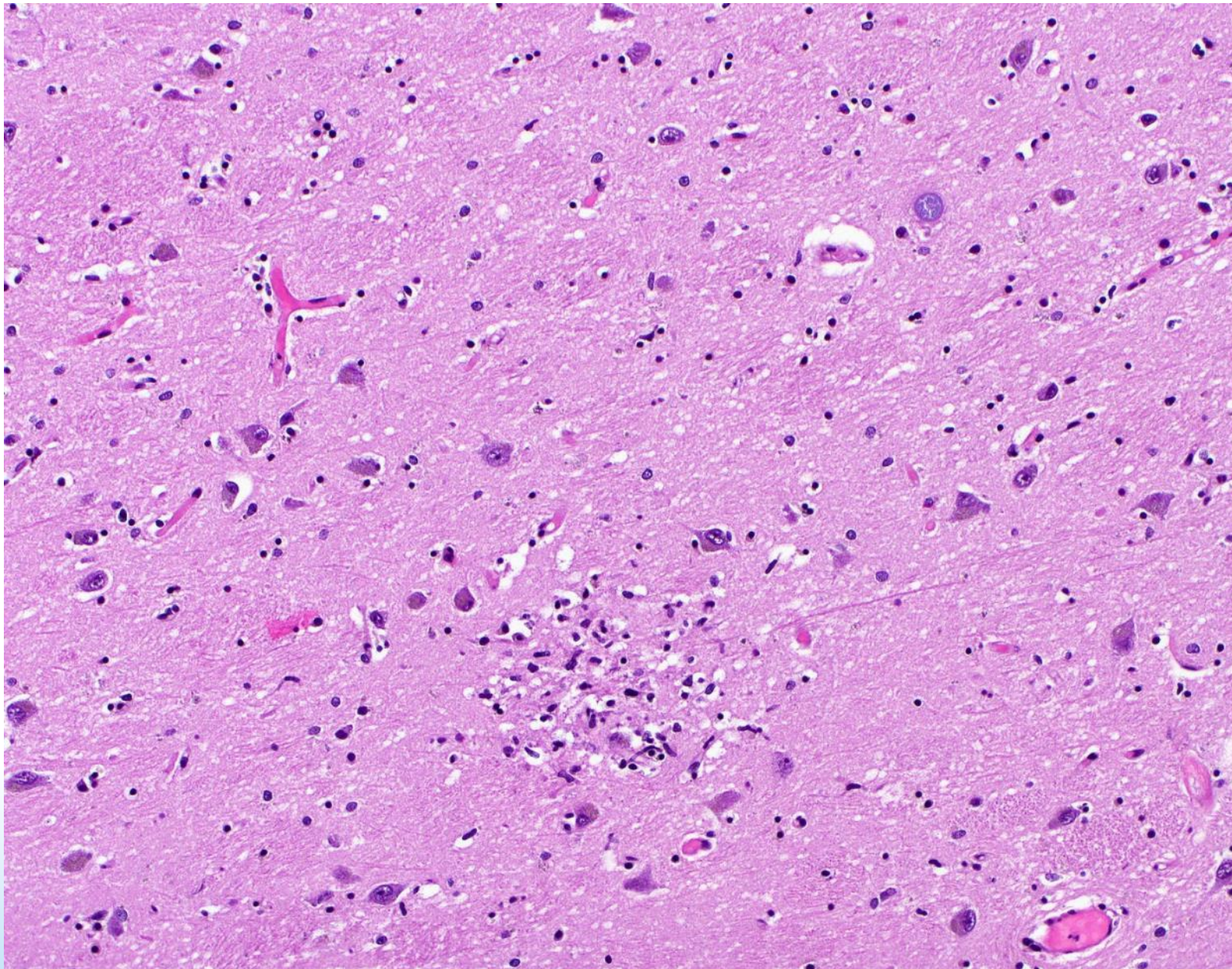




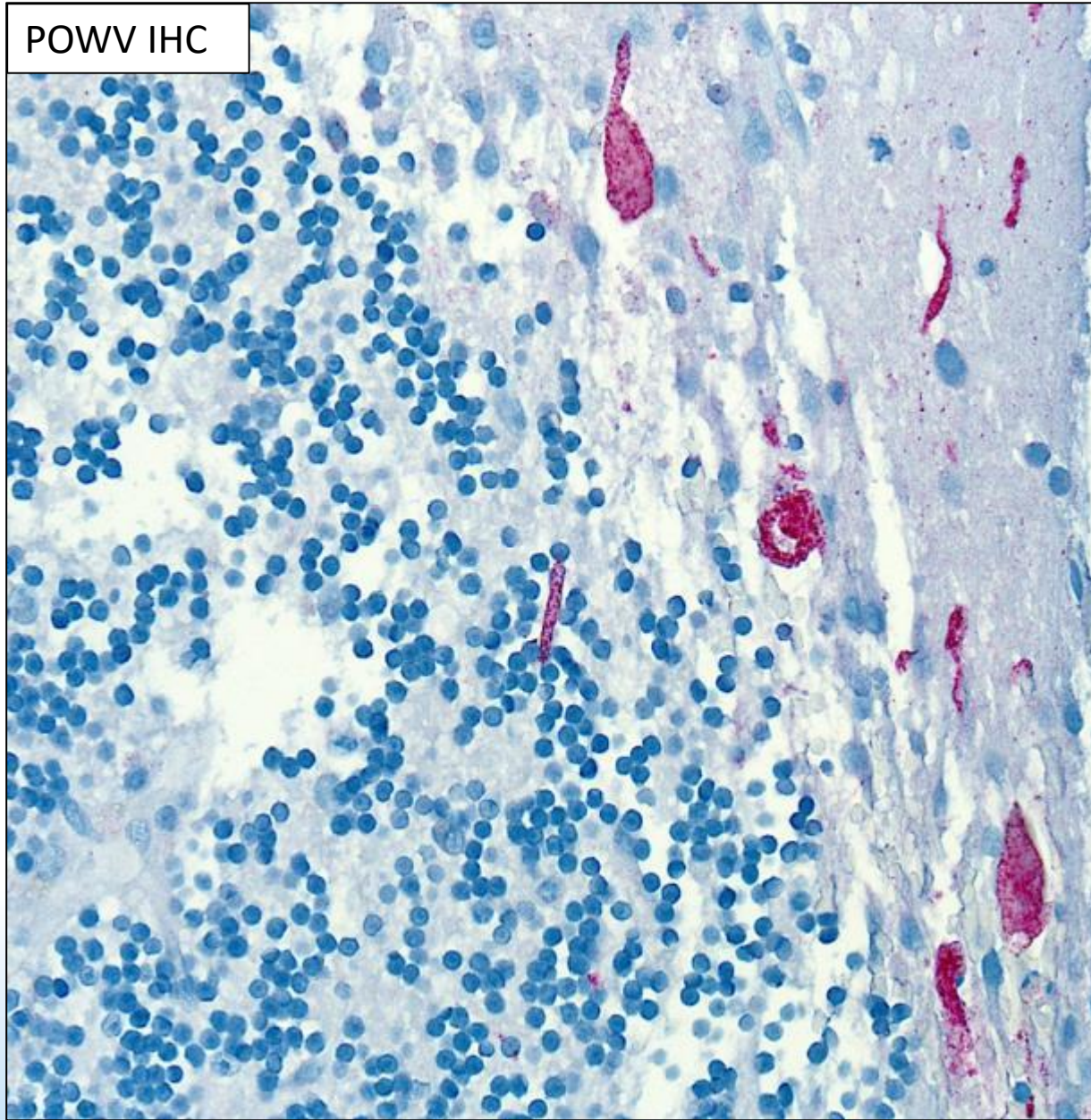








POWV IHC



Courtesy: Sherif Zaki, MD, PhD



POWV

FINAL NEUROPATHOLOGICAL DIAGNOSIS:

POWASSAN ENCEPHALITIS

mNGS (CSF):	POWV (DTV, lineage II)
IgM (blood):	negative
IgM (CSF):	negative
PCR (serum):	POSITIVE
PCR (CSF):	POSITIVE
PCR (FFPE brain):	POSITIVE
POWV IHC (FFPE brain):	POSITIVE



CNS Viral Infections

- Morphological Diagnosis of Viral Infections

- Adenovirus
- Herpes Simplex Virus 1 and 2 (HSV-1, HSV-2)
- Varicella Zoster Virus (VZV; HHV-3)
- Epstein-Barr Virus (EBV; HHV-4)
- Cytomegalovirus (CMV; HHV-5)
- Polyomavirus (i.e. JC and BK)
- Measles Virus
- Rabies Virus

- Viral Infections Requiring Ancillary Tests

- Mumps Virus
- Poliovirus
- Rubella
- Enterovirus
- Human T-Lymphotropic Virus Type 1 (HTLV-1)
- Human Immunodeficiency Virus (HIV)
- Influenza Virus
- Parainfluenza
- Arboviruses (i.e. West Nile, Eastern Equine, Powassan, Zika)
- Hendra virus and Nipah virus
- Lymphocytic Choriomeningitis Virus (LCMV)
- HHV-6 and HHV-7

Positive-strand RNA viruses

	Picornaviridae	Caliciviridae	Togaviridae	Flaviviridae	Coronaviridae
Genome size (kb)	7.2-8.4	8	12	10	16-21
Envelope	No	No	Yes	Yes	Yes
Capsid symmetry	Icosahedral	Icosahedral	Icosahedral	Icosahedral	Helical

Negative-strand RNA viruses

	Rhabdoviridae	Filoviridae	Paramyxoviridae
Genome size (kb)	13-16	13	16-20
Envelope	Yes	Yes	Yes
Capsid symmetry	Helical	Helical	Helical

Segmented negative-strand RNA viruses

	Orthomyxoviridae	Bunyaviridae	Arenaviridae	Reoviridae
Genome size (kb)	14	13-21	10-14	16-27
Envelope	Yes	Yes	Yes	No
Capsid symmetry	Helical	Helical	Helical	Icosahedral

Segmented double-strand RNA viruses

Retroviruses

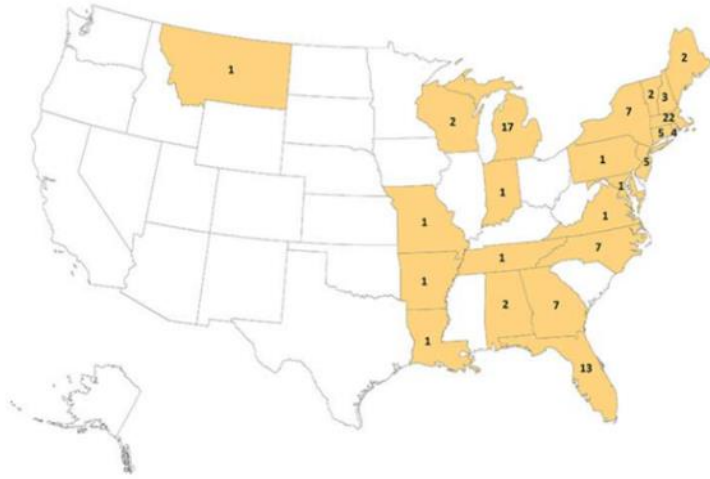	Retroviridae
Genome size (kb)	3-9
Envelope	Yes
Capsid symmetry	Icosahedral

DNA viruses

	Parvoviridae	Papovaviridae	Adenoviridae	Herpesviridae	Poxviridae
Genome size (kb)	5	5-9	36-38	100-250	240
Envelope	No	No	No	Yes	Yes
Capsid symmetry	Icosahedral	Icosahedral	Icosahedral	Icosahedral	Complex

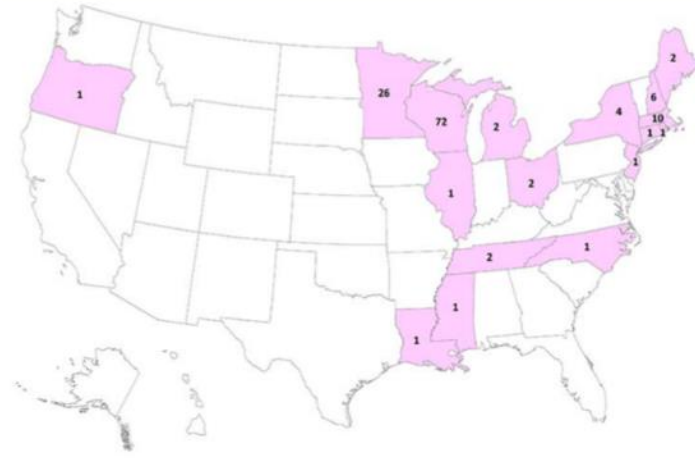
Source: Longo DL, Fauci AS, Kasper DL, Hauser SL, Jameson JL, Loscalzo J: *Harrison's Principles of Internal Medicine, 18th Edition*: www.accessmedicine.com
 Copyright © The McGraw-Hill Companies, Inc. All rights reserved.

Eastern equine encephalitis virus neuroinvasive disease cases reported by state of residence, 2010–2019*



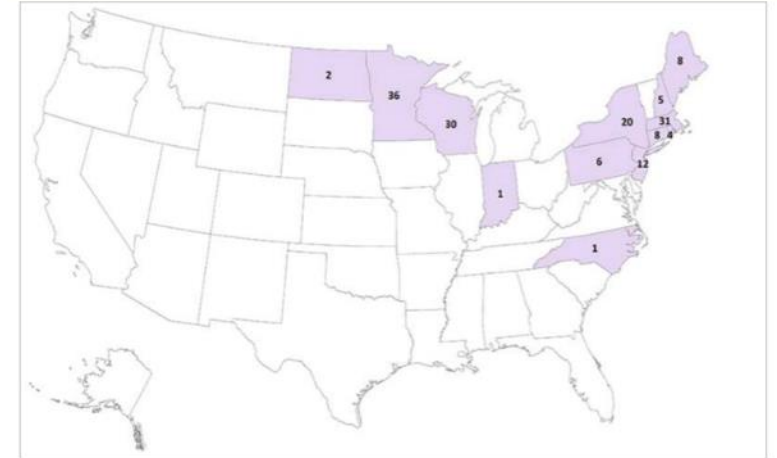
Source: ArboNET, Arboviral Diseases Branch, Centers for Disease Control and Prevention

Jamestown Canyon virus neuroinvasive disease cases reported to CDC by state of residence, 2010–2019*



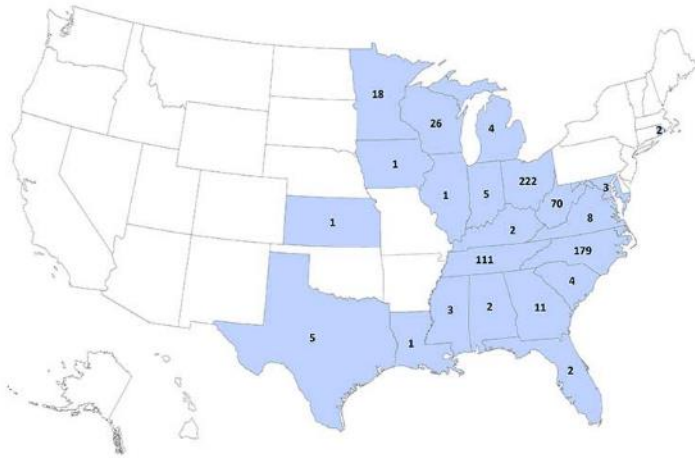
Source: ArboNET, Arboviral Diseases Branch, Centers for Disease Control and Prevention
*2019 data are provisional and subject to change

Powassan virus neuroinvasive disease cases reported by state of residence, 2010–2019*



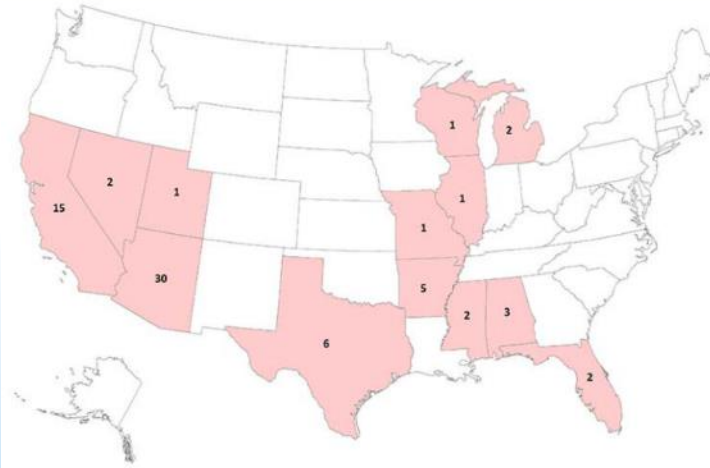
Source: ArboNET, Arboviral Diseases Branch, Centers for Disease Control and Prevention
*2019 data are provisional and subject to change

La Crosse virus neuroinvasive disease cases reported by state of residence, 2010–2019*



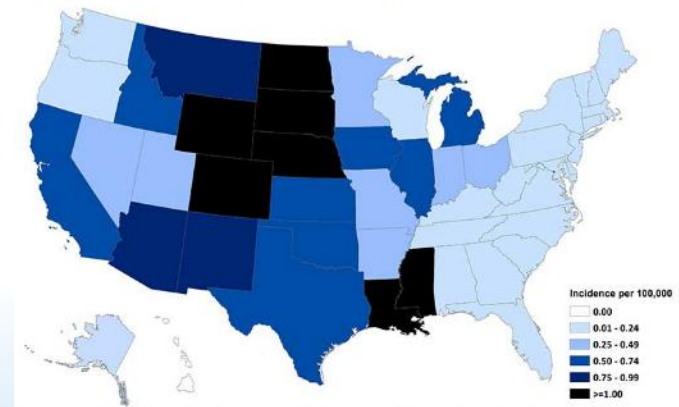
Source: ArboNET, Arboviral Diseases Branch, Centers for Disease Control and Prevention
*2019 data are provisional and subject to change

St. Louis encephalitis virus neuroinvasive disease cases reported by state of residence, 2010–2019*



Source: ArboNET, Arboviral Diseases Branch, Centers for Disease Control and Prevention
*2019 data are provisional and subject to change

Average annual incidence of West Nile virus neuroinvasive disease reported to CDC by state, 1999–2018



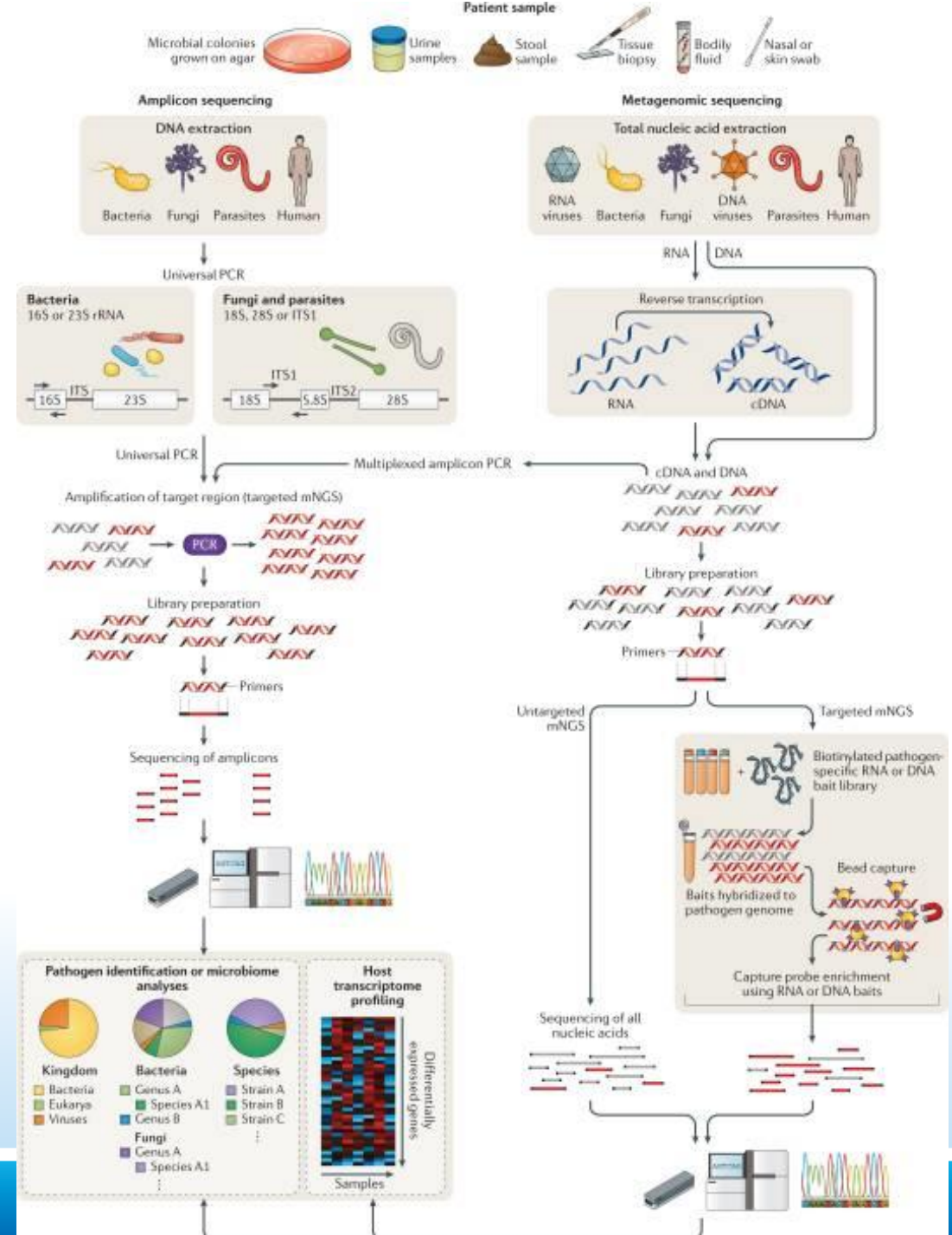
Source: ArboNET, Arboviral Diseases Branch, Centers for Disease Control and Prevention



Metagenomic next-generation sequencing (mNGS)

- Advantages
 - Single test
 - Unbiased
 - Moderate turn around time
- Limitations
 - Relatively expensive
 - Low sensitivity
 - Requires sufficient quantity of pathogen nucleic acid

Chiu and Miller. (2019) *Nat Rev Genet.* 20(6): 341–355.



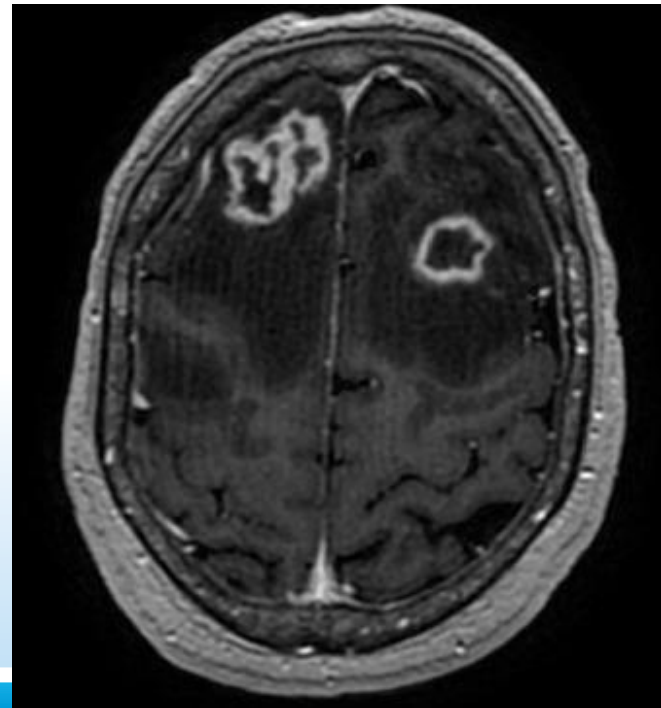
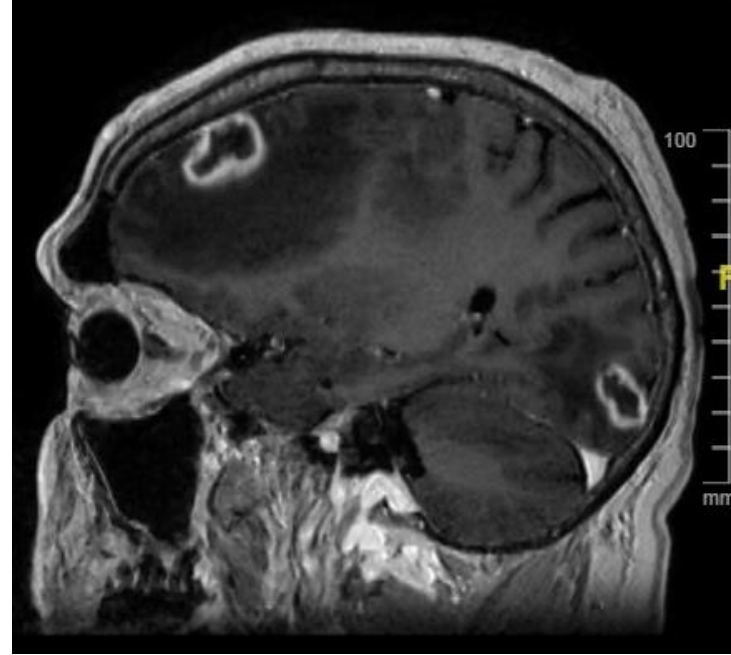
Summary – mNGS

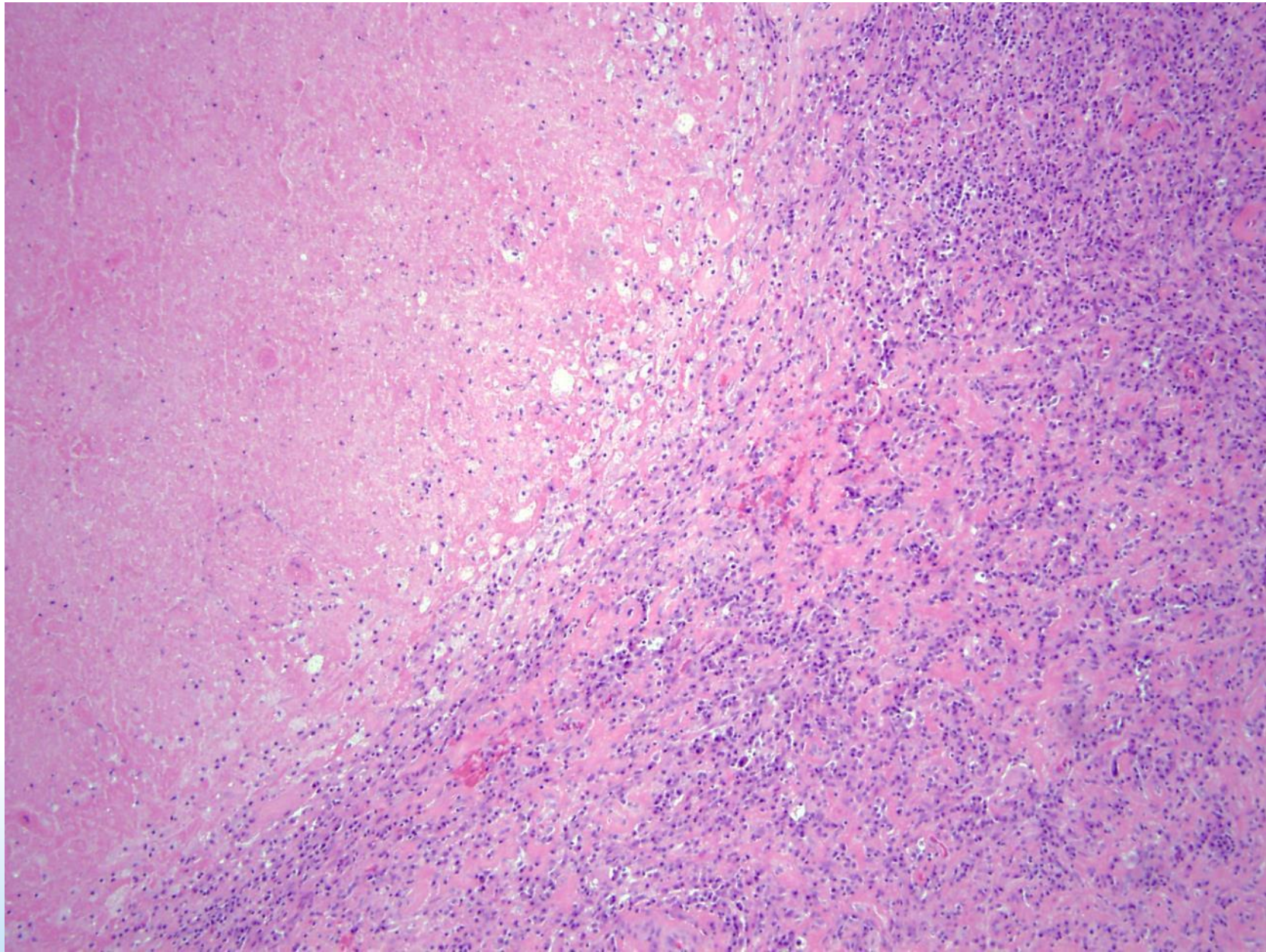
- Powerful tools for identification of pathogens in cases with broad infectious differential (e.g. viral meningoencephalitis)
- Can identify novel pathogens, but must distinguish from environmental contamination (varies with laboratory)
- Relatively expensive but could provide cost savings if ordered instead of large panel of molecular tests
- Turn around time improving with better informatics pipelines; interpretation still required

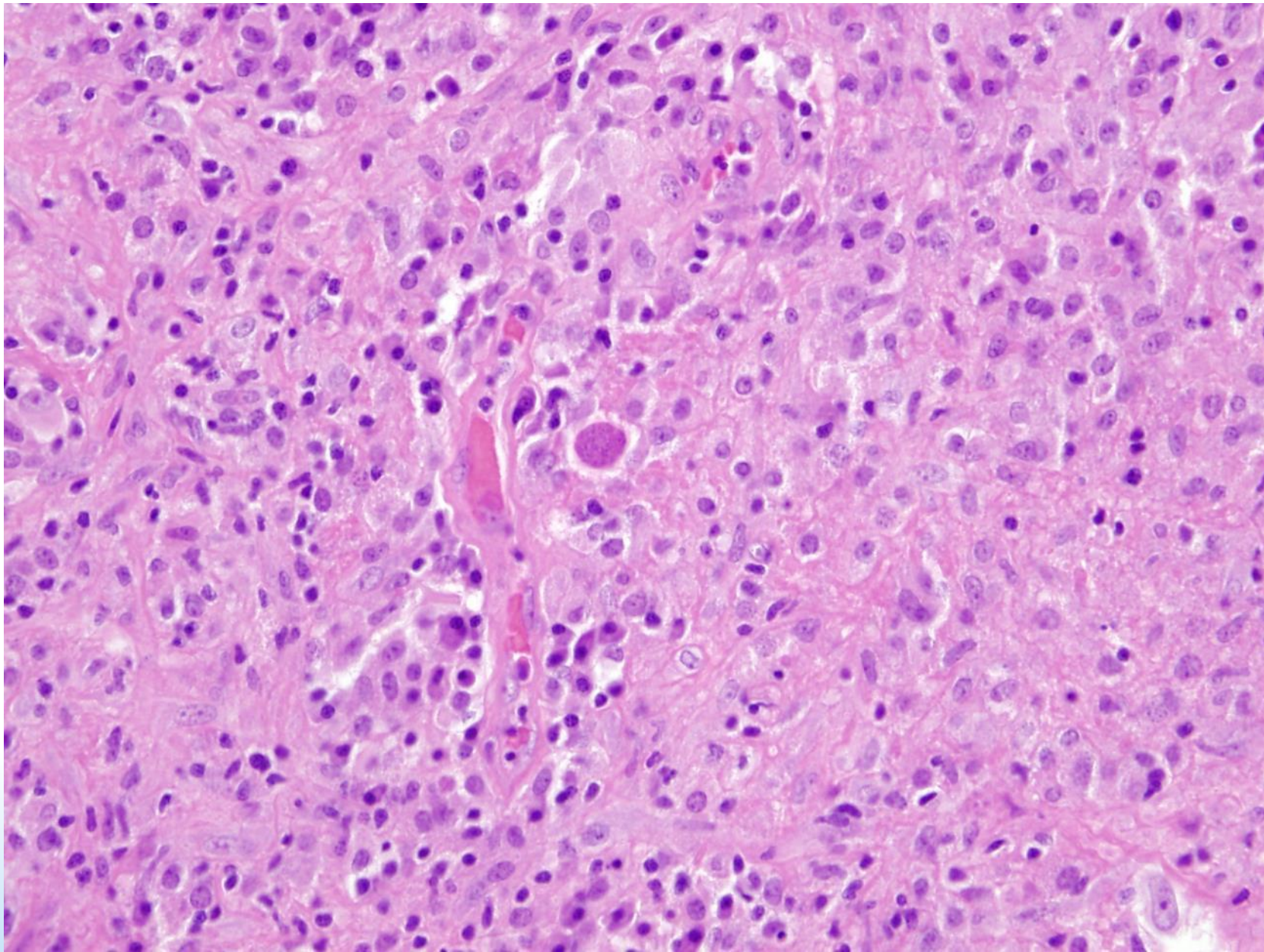


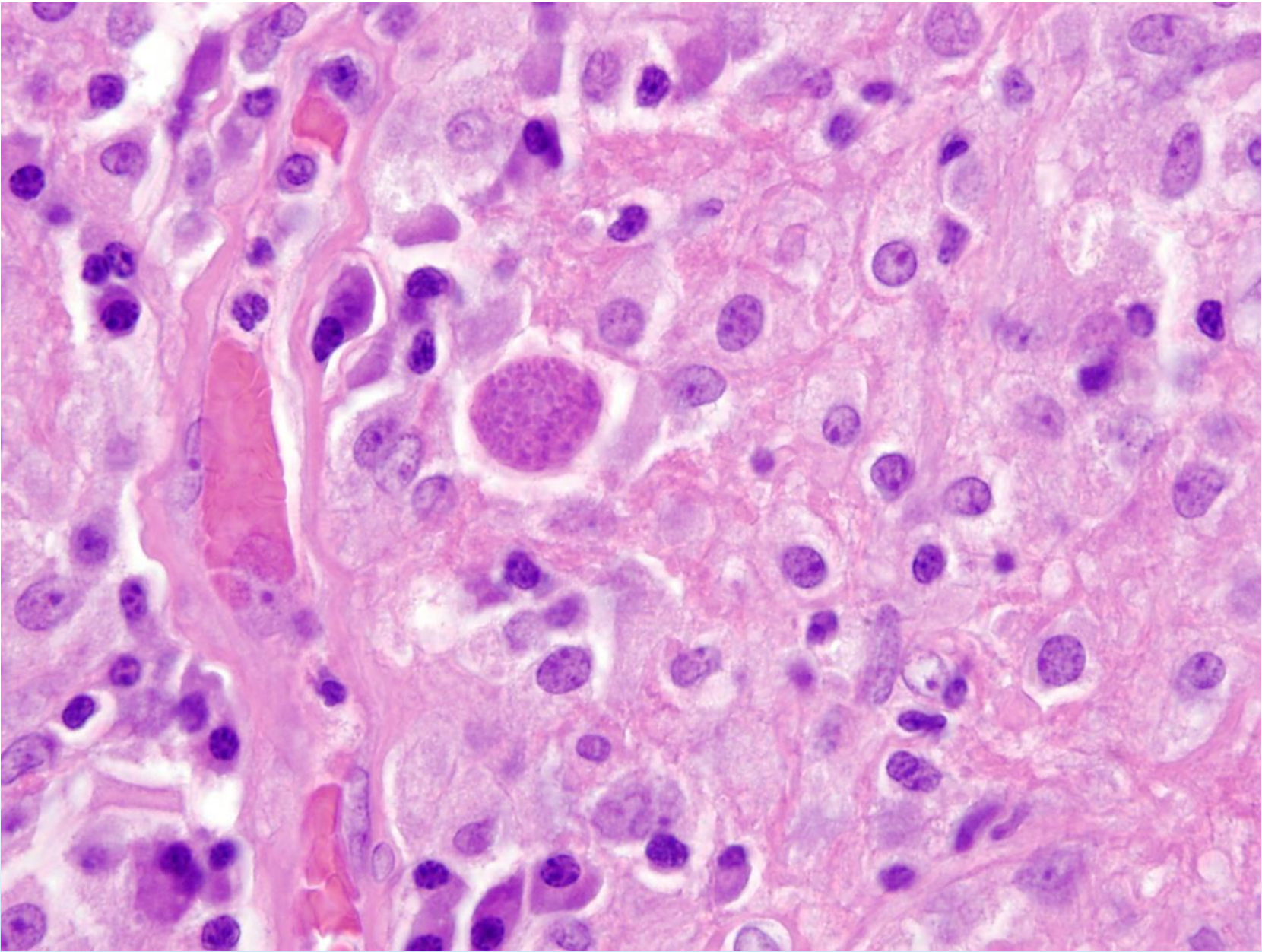
Case 5

- 56-year-old man with untreated HCV, alcoholic liver disease, interstitial lung disease
- Presented with progressive cognitive decline over several days without fever or meningismus
- MRI: Multiple large ring enhancing lesions (up to 3 cm) with extensive vasogenic edema and local mass effect

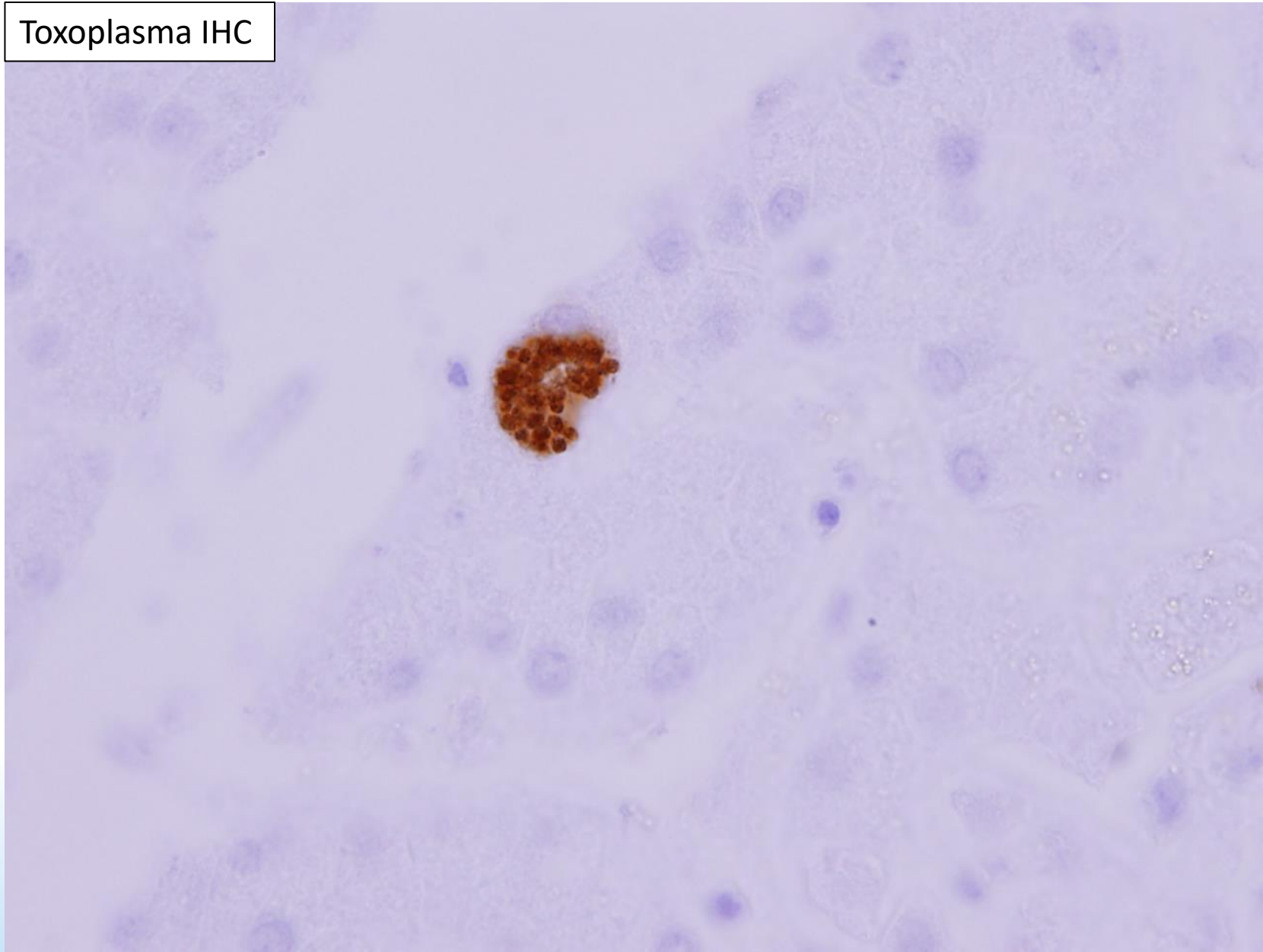




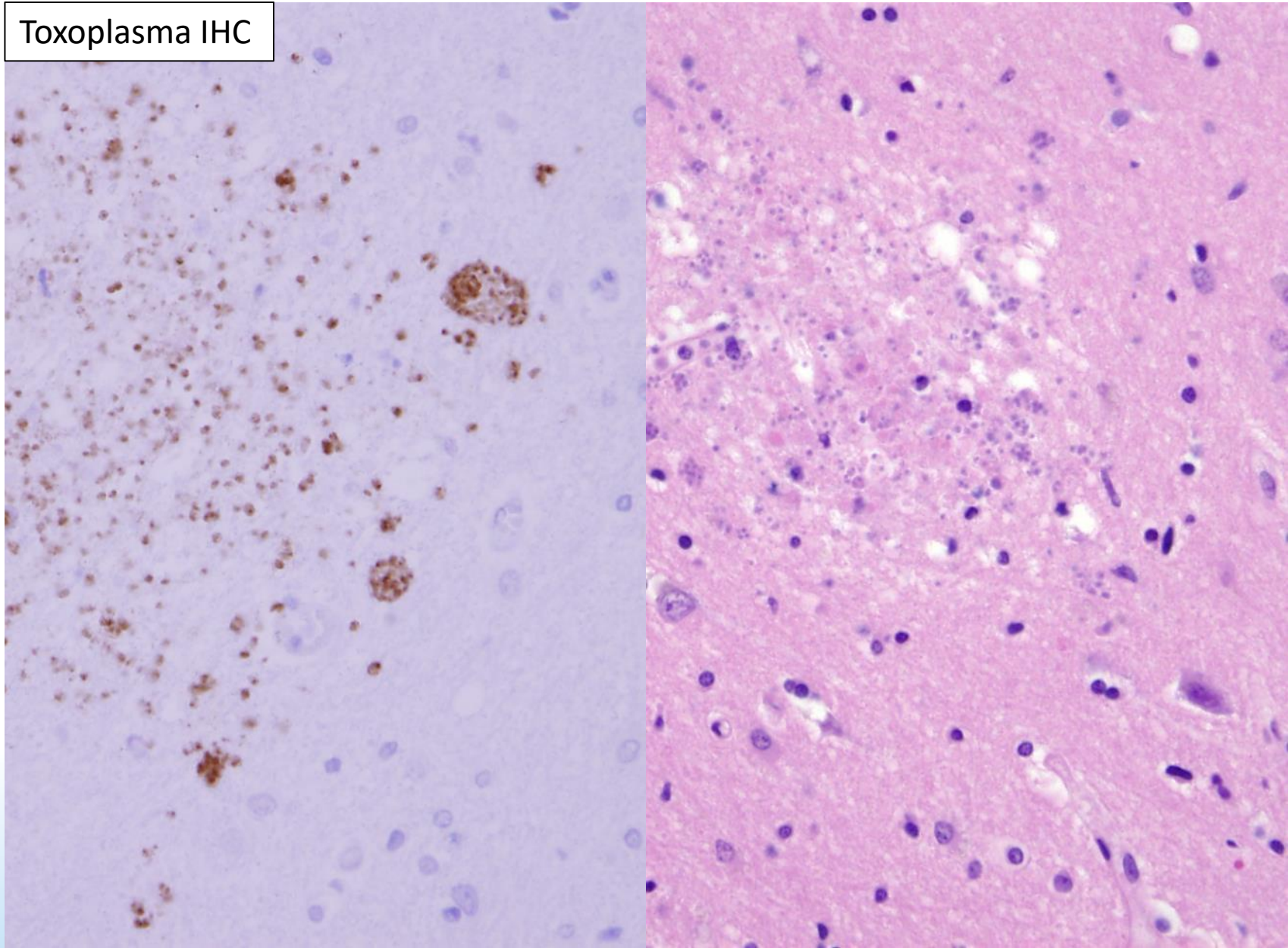




Toxoplasma IHC



Toxoplasma IHC



PATHOLOGIC DIAGNOSIS:

A. SPECIMEN DESIGNATED "RIGHT FRONTAL TUMOR":

Abscess with TOXOPLASMA GONDII organisms identified.

Toxoplasma IGG EIA: 5.57 POSITIVE (Suggestive of infection at undetermined time)

HIV ELISA test positive



Parasitic Infections

Table 5.2 Principal Protozoa Responsible for Human Infections

1. Amoebiasis

- a. *Entamoeba histolytica*: cerebral amoebic abscesses
- b. Primary amoebic encephalitis
 - i. Primary amoebic meningoencephalitis (*Naegleria fowleri*)
 - ii. Granulomatous amoebic encephalitis (*Acanthamoeba* spp. and *Leptomyxid*)
 - iii. *Acanthamoeba* keratitis

2. **Cerebral malaria** (*Plasmodium falciparum* infection)

3. **Toxoplasmosis** (*Toxoplasma gondii* infection)

4. Trypanosomiasis

- a. African trypanosomiasis (*Trypanosoma brucei* spp.)

Table 5.3 Major Helminthic Infections of the CNS

1. Cestodes

- a. Neurocysticercosis (*Taenia solium*)
- b. Hydatid cyst (*Echinococcus granulosus*)
- c. Coenuriasis (*Taenia multiceps*)
- d. Sparganosis (*Spirometra*)

2. Trematodes

- a. Paragonimiasis (*Paragonimus westermani*)
- b. Schistosomiasis (*Schistosoma mansoni*, *japonicum*, *haematobium*, *mekongi*)
- c. Other trematode infections

3. Nematodes

- a. Eosinophilic meningoencephalitis
 - i. *Angiostrongylus cantonensis*
 - ii. *Gnathostoma spinigerum*
- b. Toxocariasis (visceral larva migrans)
Other forms of larva migrans
Trichinella spiralis
- c. Human filariases
 - i. Loa-loa
 - ii. *Dracunculus medinensis*
 - iii. *Onchocerca volvulus*
- d. Nematodes and immunosuppression
Strongyloides stercoralis



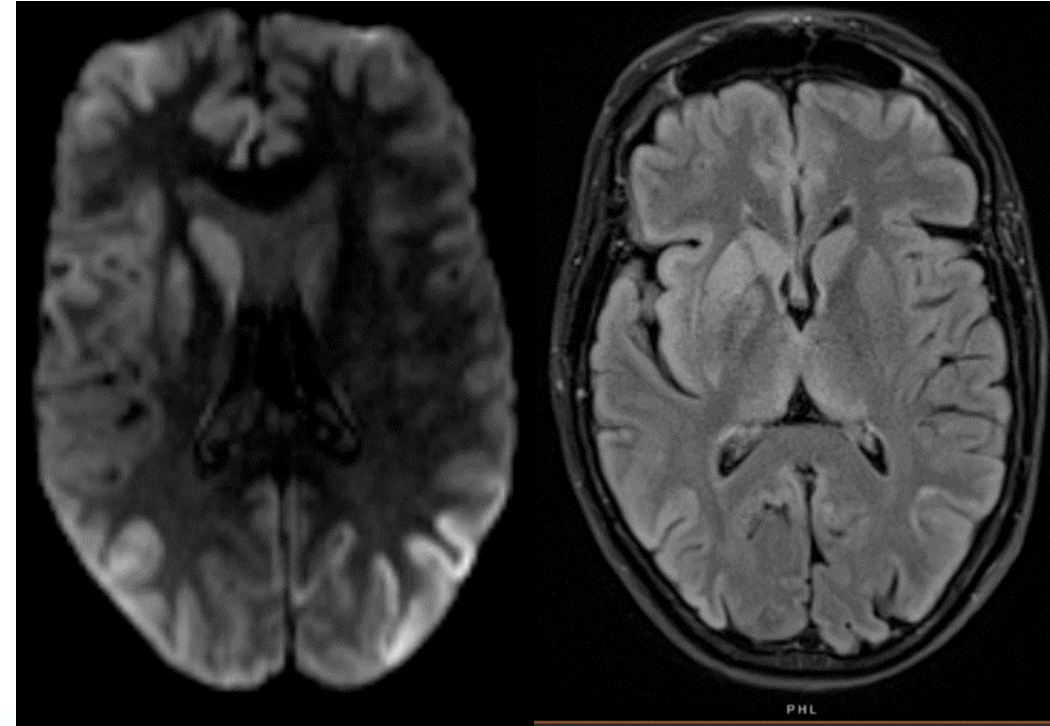
Summary - Parasitic Infections

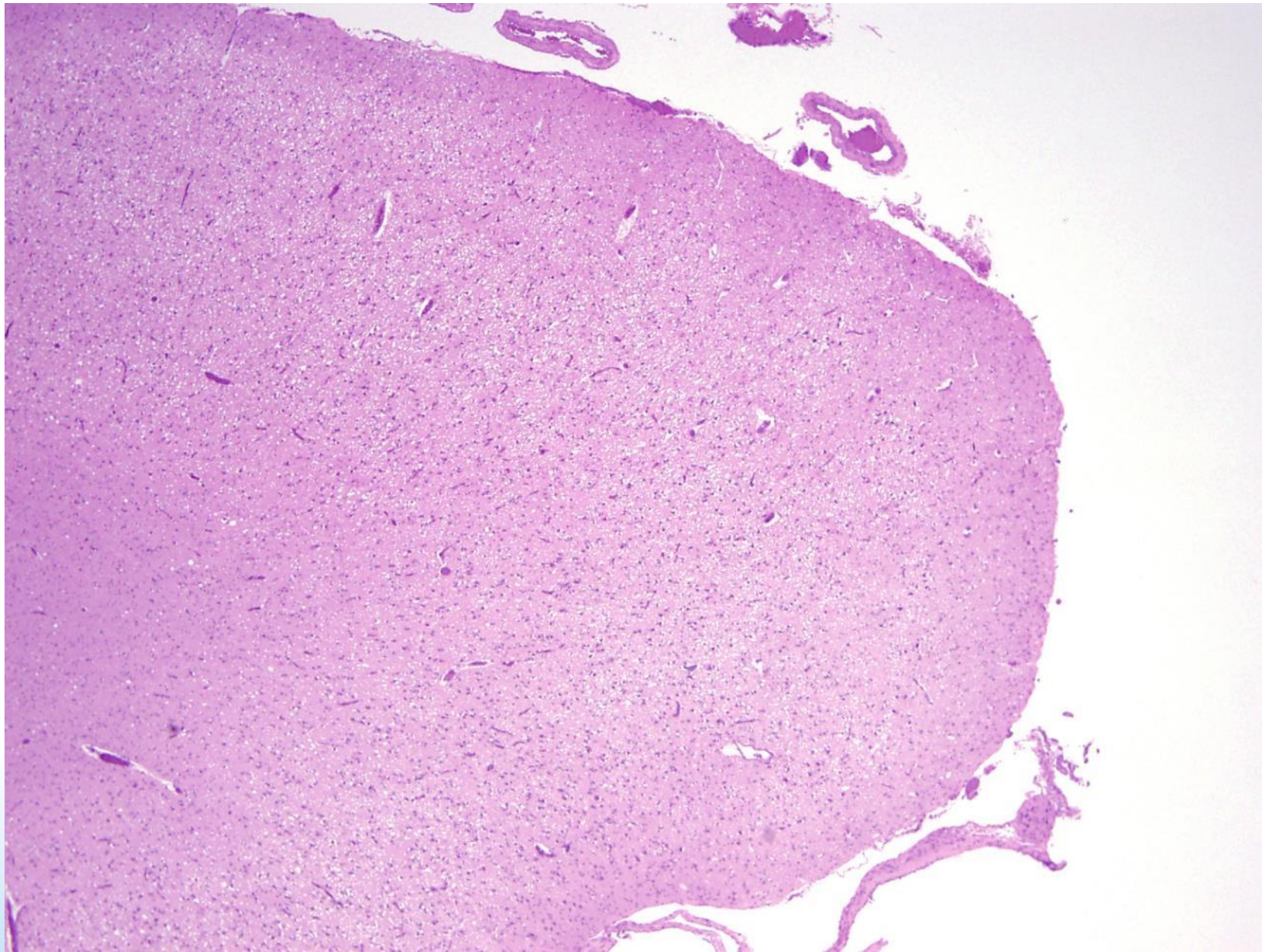
- Morphological diagnosis sufficient in many cases
- Often unable to identify to species, but can specify helminth vs protozoan, nematode vs trematode vs cestode, amoeba vs toxoplasma
- Consultation available from reference centers
- Serology (and exposure history) can narrow differential
- Targeted assays (e.g. *Naegleria fowleri* vs *Acanthamoeba* spp.) and mNGS (CSF) are clinically available

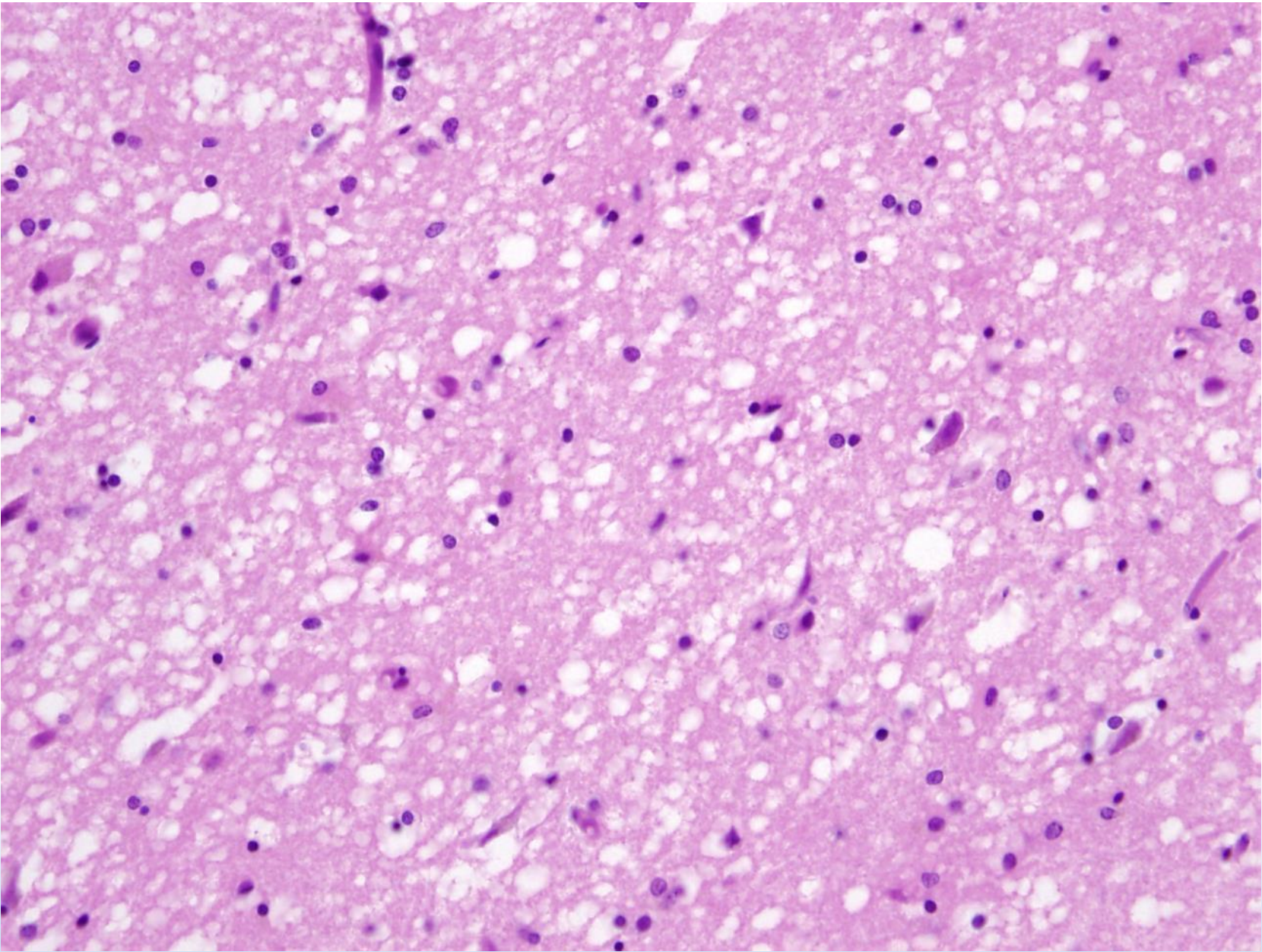


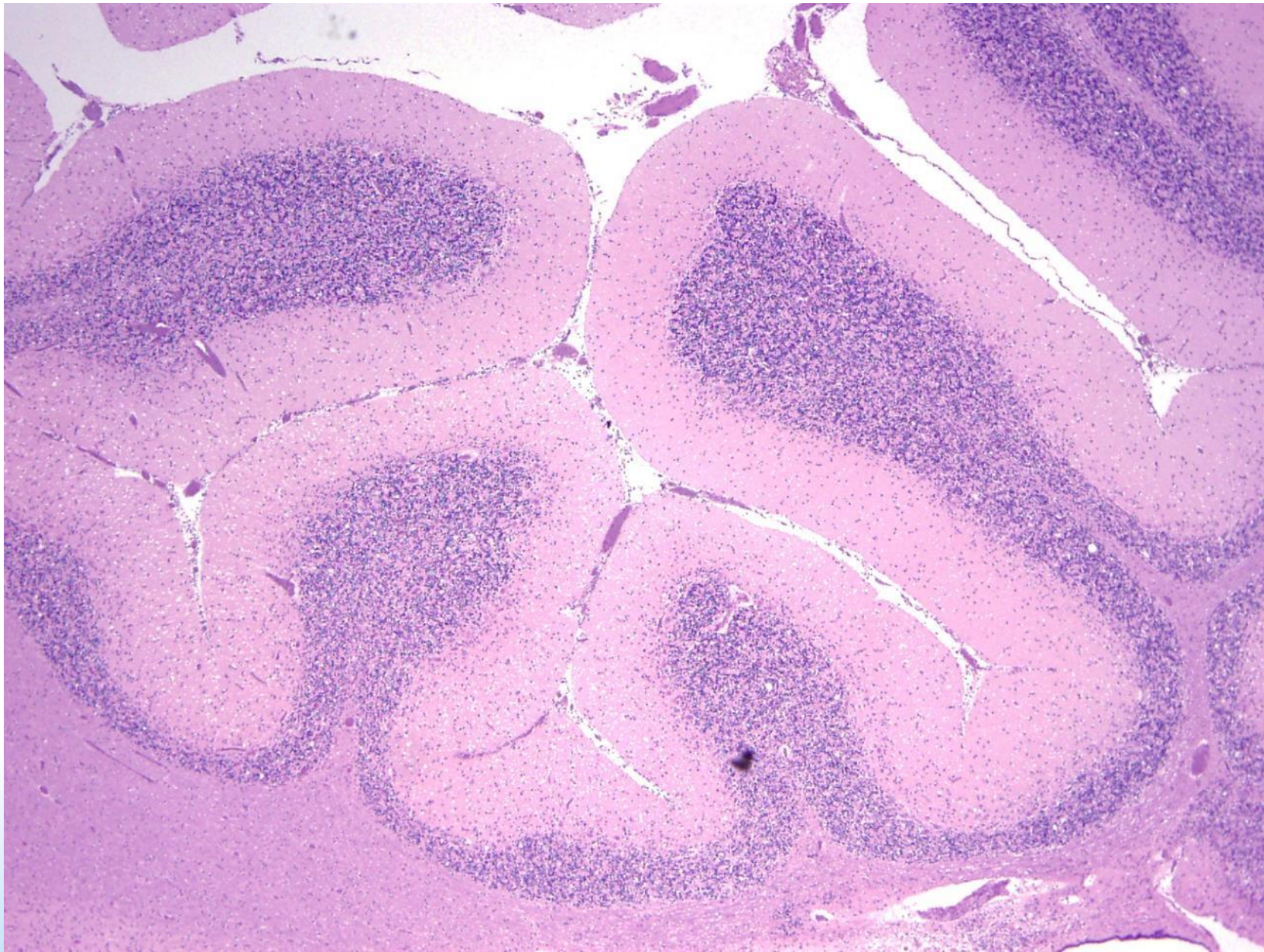
Case 6

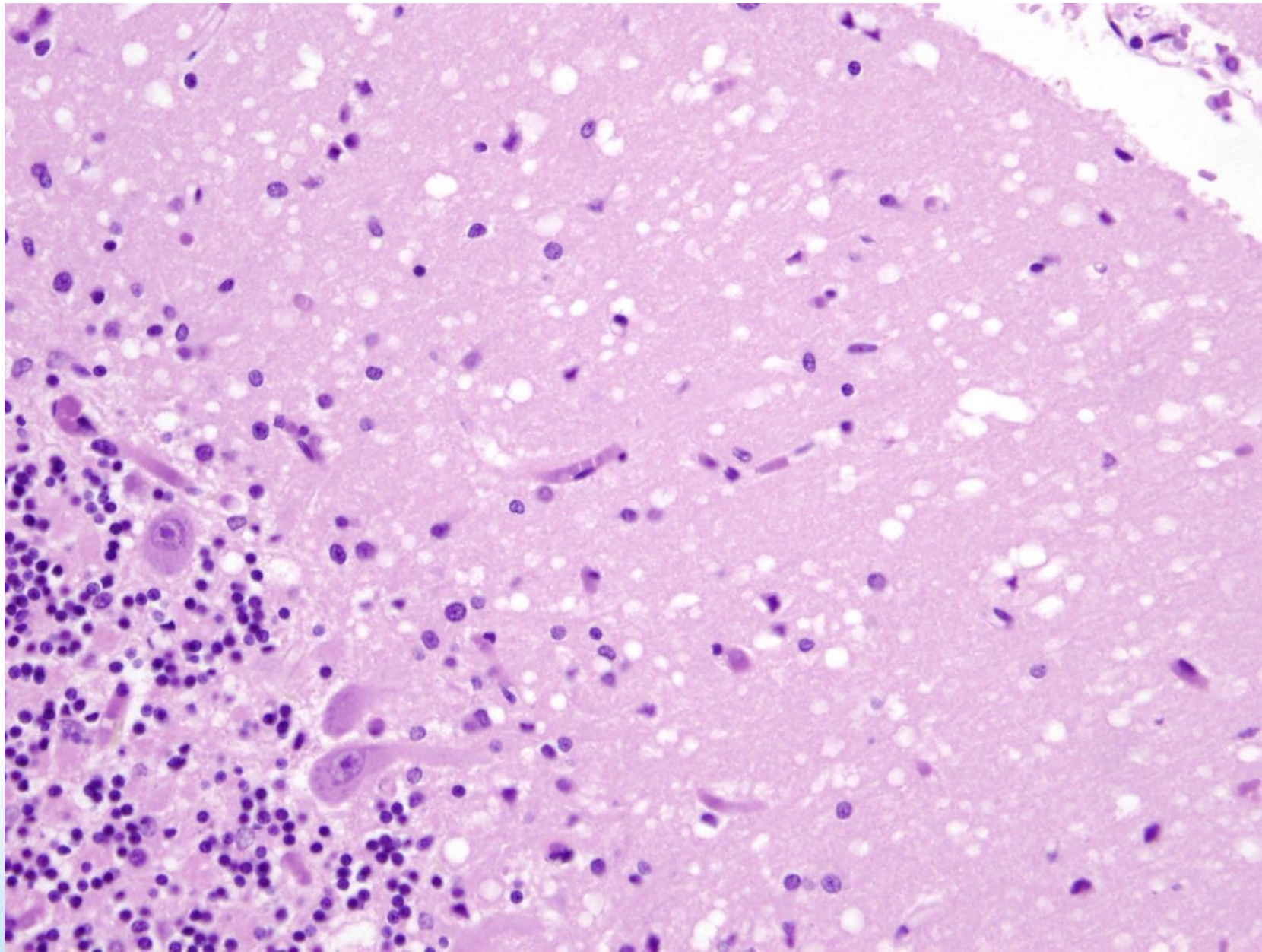
- 56-year-old woman with no significant past medical history
- Presented with multiple neurological complaints (headaches, gait abnormalities, slowed speech, trouble swallowing, difficulty with driving, memory, and calculations), and insidious decline in functioning and ADLs over 2-3 months
- MRI: Cortical restricted diffusion identified in occipital, temporal, frontal and parietal lobes; T2/FLAIR hyperintensity in bilateral basal ganglia and thalami









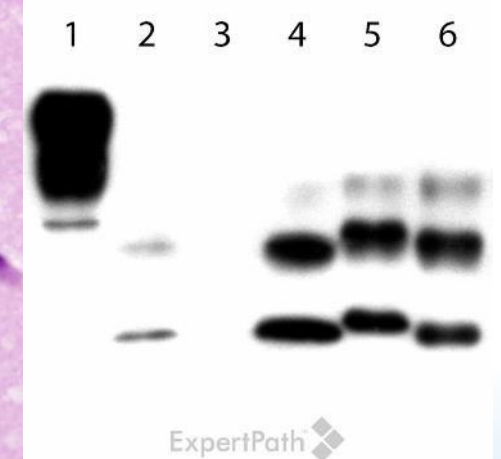
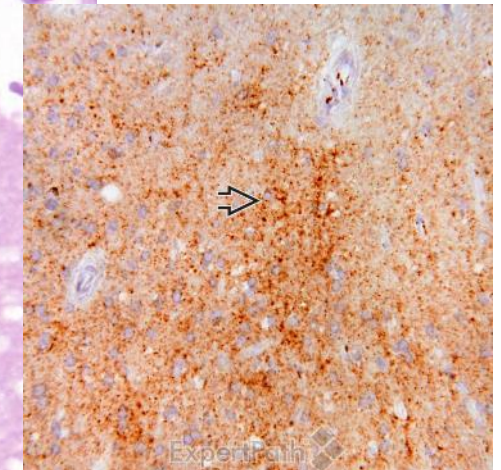


FINAL NEUROPATHOLOGICAL DIAGNOSIS:

PRION DISEASE, most likely CREUTZFELDT-JAKOB DISEASE

NOTE:

Western blot and immunohistochemistry (3F4) for PrPSc were performed at the National Prion Disease Pathology Surveillance Center, which revealed granular deposits as seen in prion disease.



Human Prion Diseases

- MRI
- CSF (14-3-3, tau, RT-QuIC)
- Histology: Spongiform degeneration
- Confirm by WB, IHC
- Sequence *PRNP* gene for mutations

2018 CDC Diagnostic Criteria for CJD

1. Sporadic CJD

Definite:

- Diagnosed by standard neuropathological techniques; and/or immunocytochemically; and/or Western blot confirmed protease-resistant PrP; and /or presence of scrapie-associated fibrils.

Probable:

- Neuropsychiatric disorder **plus** positive RT-QuIC in cerebrospinal fluid (CSF) or other tissues

OR

- Rapidly progressive dementia; **and** at least two out of the following four clinical features:
 1. Myoclonus
 2. Visual or cerebellar signs
 3. Pyramidal/extrapyramidal signs
 4. Akinetic mutism

AND a positive result on at least one of the following laboratory tests

- a typical EEG (periodic sharp wave complexes) during an illness of any duration
- a positive 14-3-3 CSF assay in patients with a disease duration of less than 2 years
- High signal in caudate/putamen on magnetic resonance imaging (MRI) brain scan or at least two cortical regions (temporal, parietal, occipital) either on diffusion-weighted imaging (DWI) or fluid attenuated inversion recovery (FLAIR)

AND without routine investigations indicating an alternative diagnosis.

Possible:

- Progressive dementia; **and** at least two out of the following four clinical features:
 1. Myoclonus
 2. Visual or cerebellar signs
 3. Pyramidal/extrapyramidal signs
 4. Akinetic mutism

AND the absence of a positive result for any of the four tests above that would classify a case as "probable"

AND duration of illness less than two years

AND without routine investigations indicating an alternative diagnosis.

2. Iatrogenic CJD

Progressive cerebellar syndrome in a recipient of human cadaveric-derived pituitary hormone; **or** sporadic CJD with a recognized exposure risk, e.g., antecedent neurosurgery with dura mater implantation.

3. Familial CJD

Definite or probable CJD **plus** definite or probable CJD in a first degree relative; and/or Neuropsychiatric disorder **plus** disease-specific PrP gene mutation.

Overall Summary

- CNS infections can be effectively diagnosed by gross and histological findings with appropriate ancillary testing
- Targeted assays useful when a specific pathogen is suspected on clinical or histological grounds
- Consider panel or unbiased testing if a broad differential exists
- Molecular testing results should be correlated with histological findings for a final integrated diagnosis



Questions?



HARVARD
MEDICAL SCHOOL



**BRIGHAM AND
WOMEN'S HOSPITAL**

ihsolomon@bwh.harvard.edu



References

1. Solomon IH. Surg Pathol Clin. 2020 Jun;13(2):277-289. Molecular and Histologic Diagnosis of Central Nervous System Infections. PMID: 32389267
2. Ramachandran PS, Wilson MR. Nat Rev Neurol. 2020 Oct;16(10):547-556. Metagenomics for neurological infections - expanding our imagination PMID: 32661342
3. Kanjilal S, Cho TA, Piantadosi A. Semin Neurol. 2019 Jun;39(3):297-311. Diagnostic Testing in Central Nervous System Infection. PMID: 31378866

